

Rinore ile Başvuran Kalsifiye Ventriküloperitoneal Şantlı Bir Olgu

A Case With Calcified Ventriculoperitoneal Shunt Presenting With Rhinorrhea

Hümevra Kullukçu Albayrak¹ ORCID No: 0000-0003-0675-8288, **Atilla Kazancı²** ORCID No: 0000-0001-8975-9694, **Ahmet Gürhan Gürçay²** ORCID No: 0000-0002-8810-938X, **Oktay Gürçan¹** ORCID No: 0000-0002-2726-0043, **Mehmet Özgür Özateş¹** ORCID No: 0000-0002-2051-7766, **Salim Şentürk³** ORCID No: 0000-0003-0524-9537, **Pınar Ural⁴** ORCID No: 0000-0001-7324-8339, **Erkin Gonca⁵** ORCID No: 0000-0001-6682-5433, **Murad Bavbek⁶** ORCID No: 0000-0002-6256-4202

¹Ankara City Hospital Department of Neurosurgery, Ankara, Turkey.

²Yıldırım Beyazıt University Faculty of Medicine Department of Neurosurgery, Ankara, Turkey.

³Koç University Hospital, Department of Neurosurgery, İstanbul, Turkey.

⁴Çaycuma Public Hospital, Department of Neurosurgery, Zonguldak, Turkey.

⁵Etimesgut Public Hospital, Department of Neurosurgery, Ankara, Turkey.

⁶Özel Muayenehane, Ankara, Türkiye.

Geliş Tarihi/Received: 09.07.2020

Kabul Tarihi/Accepted: 07.11.2020

Yazışma Adresi/Address for Correspondence:

Hümevra Kullukçu Albayrak

Ankara City Hospital

Department of Neurosurgery,

Ankara, Turkey.

e-posta: humeyrakullukcu@hotmail.com

ÖZ

Ventriküloperitoneal şant, silikon serebral omurilik sıvısı şant sistemi, hidrosefali için en yaygın etkili tedavidir. Cerrahi teknikler ve cihazlardaki gelişmelere rağmen, beyin omurilik sıvısı şant cerrahisinde çeşitli sorunlar ve zorluklar yaşanmaktadır. Şant malzemesinin yaşlanması ve bozulması, bozulmuş silikonun neden olduğu aşırı duyarlılık ve kateterin kalsifikasyonundan kaynaklanan şant tıkanması geç komplikasyonların tipik örnekleridir. Ventriküloperitoneal şantın kalsifikasyonu ve ilişkili disfonksiyonu nöroşirürji pratiğinde nadir görülen olaylardır. Şant kalsifikasyonu, şönt disfonksiyonuna, yani bağlantısızlık ve tıkanıklığa neden olur. Bu yazıda kalsifikasyona bağlı tıkanıklık nedeniyle şant bozukluğu olan 34 yaşında erkek hasta sunuldu.

ABSTRACT

The ventriculoperitoneal shunt, silicone cerebral spinal fluid shunting system, is the most common effective treatment of hydrocephalus. Despite developments in surgical techniques, and devices, various problems and difficulties are still experienced in the surgery of cerebral spinal fluid shunting. Aging and degradation of the shunt material, hypersensitivity caused by degraded silicone, and shunt obstruction caused by calcification of the catheter are typical examples of late complications. Calcification and related dysfunction of ventriculoperitoneal shunt are rare events in neurosurgical practice. Shunt calcification causes shunt dysfunction in two ways, namely disconnection and obstruction. We present a 34-year-old male patient with shunt malfunction due to obstruction secondary to calcification.

Anahtar Kelimeler:

Kalsifikasyon

Komplikasyon

Ventriküloperitoneal

Şant

Key Words:

Calcification

Complication

Ventriculoperitoneal

Shunt

Introduction

For the treatment hydrocephalus most common method is using cerebral spinal fluid (CSF) shunting system (1-2). Various problems like as disfunction of shunt, infection, shunt malposition and calcification of shunt are still experienced in the surgery of CSF shunting. The rate of shunt failure after surgery is nearly 30% after the 1st year, the possibility of a shunting system being still

functional with in ten years has been predicted as 15% (3). In literature shunt calcifications are reported as rare case reports. Boch et al. reported 64 cases with shunt calcification as a late complication (3). Herein, we present a 34-year-old male patient with shunt malfunction due to obstruction secondary to calcification 22 years after ventriculoperitoneal shunt (VP) shunt surgery.

Case Report

A 34-year-old male patient was referred to our clinic with complaints of serous nasal discharge for 10 days following a severe headache lasting for 3 days. The patient had undergone VP shunt operation by the senior author of this paper 22 years ago with the indication of secondary hydrocephalus due to meningitis. His neurological examination was unremarkable. On cranial computed tomography, tetraventricular hydrocephalus was observed. During magnetic resonance cisternography, radio-opaque substance (Magnevist®; Schering Diagnostics AG, Berlin, Germany) was administered intrathecally and CSF leak into sphenoid sinus was observed while the patient was in prone position (Figure 1).

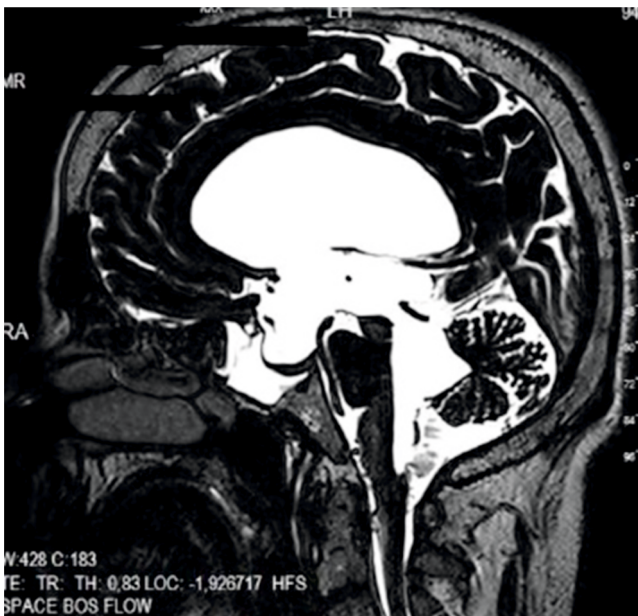

Figure 1. Magnetic resonance cisternography showing cerebrospinal fluid leak into sphenoid sinus.

Palpation revealed non-functional dome of the shunt. Calcified shunt trace was observed in the plain radiograph (Figure 2). After evaluation of the patient reoperated for shunt revision was performed.

Perioperatively, CSF leak from the ventricular end was observed; however, calcification of the peritoneal part of the shunt was detected which necessitated removal of the shunt (Figure 3). A new shunt system with a moderate pressure was applied. During the postoperative period, rhinorrhea ceased and a second surgical intervention was not performed on sphenoid sinus. At his 1st year-follow-up visit, any medical or surgical problem was not encountered. Consent form was taken from the patient.

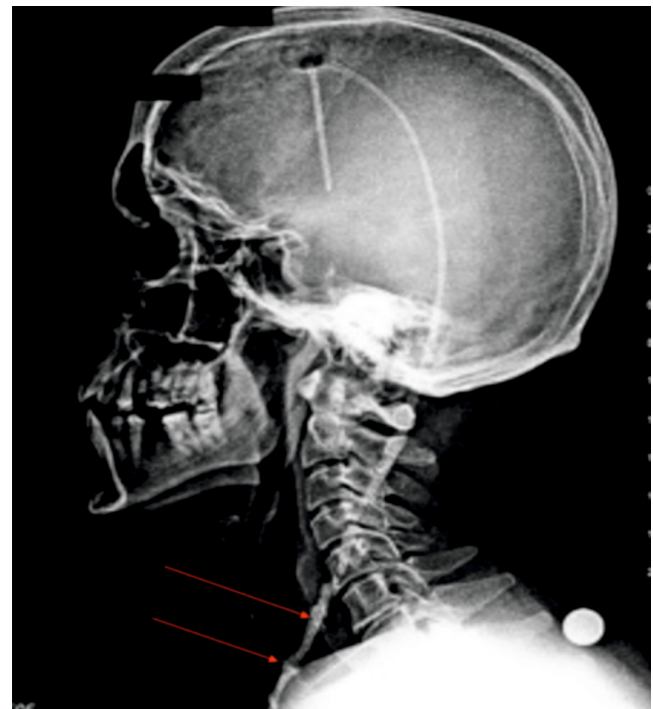


Figure 2. Preoperative plain radiograph showing the calcified shunt trace with arrow.

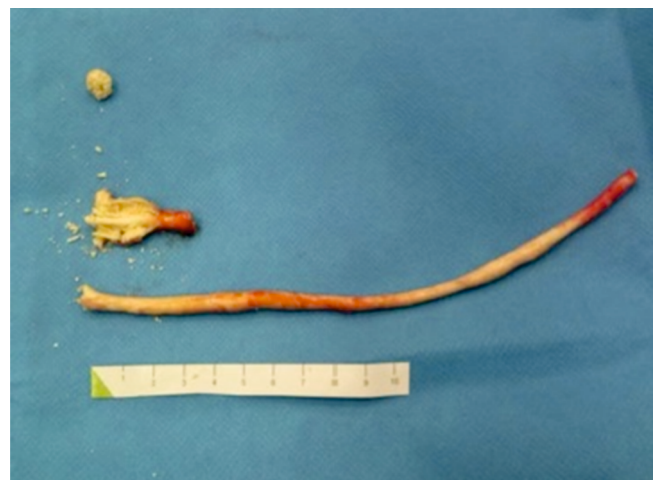

Figure 3. Calcification observed in the peritoneal part of the shunt.

Discussion

The VP shunt insertions account for a compelling number of neurosurgical operations. Even though VP shunts have resulted in striking improvements in survival of patients and neural functions, they are associated with a number of complications. In our case rhinorrhea was detected. Probably reason of rhinorrhea is increased intracranial pressure due to hydrocephalus and defected bony structure. Two types of, early and late complications of shunting are described by Boch et al. (3). Several studies revealed that blocked shunt systems might be

referred to either the extension of neighborhood tissue through to the shunt catheter, a comprehensive immune reaction, or a hypersensitivity reaction (4). Problems dealing with management of the patient, shunting procedure and the functioning of the shunt system itself are the common causes of early shunt complications like as hemorrhage, malposition, infection and poor quality shunt components. Aging and degradation of the shunt material, hypersensitivity caused by degraded silicone, and shunt obstruction caused by calcification of the catheter are typical examples of late complications (5). Herein, we present a patient with VP shunt malfunction due to obstruction caused by calcification. Calcification of the VP shunt has been one of the least reported complications of VP shunts. There are a series of cases in literature about shunt calcification Boch et al. reported 64 cases with as a late complication (3).

A variety of factors have been blamed for calcium deposition in VP shunts:

1. A soft-tissue reaction may be triggered by the difference in the quantity of silica added to silicone rubber (6).
2. Dust and lint may be hold by the static electrical charges on the tubing (6).
3. Silicone rubber may absorb benzalkonium chloride (6).
4. Soft-tissue fibrosis may be triggered by detergents and dissolved ethylene oxide gas (6).
5. Biodegradation of polymers may be caused due to dissolution and digestion by macrophages, splitting of covalent bonds, and hydration (3,6,7).
6. Catheters may be damaged before implantation. New and unused VP shunts are studied with the scanning electron microscope by Guevara et al (8). They showed sporadic irregular defects in the outer surface and revealed the defective quality control during manufacture.

Shunt calcification is a late complication and appears to be partly related to aging of the shunt tube material (3).

Yazarlık Katkısı: Fikir/Hipotez: HKA, AK, OG, EG, PU
Tasarım: AK, MÖÖ, SŞ Veri toplama/Veri işleme:AK, AGG, OG, MÖÖ, PU, SŞ,MB Veri analizi: AGG, OG, EG Makalenin hazırlanması: : HKA, AGG, OG, EG.

Hasta Onayı: Olgu sunumu için hastadan izin alınmıştır.

Hakem Değerlendirmesi: İlgili alan editörü tarafından atanan iki farklı kurumda çalışan bağımsız hakemler tarafından değerlendirilmiştir.

Kural et al. reported that the shunt tube calcification can occur in spite of normal blood calcium and phosphorus levels; this is attributed mainly to the altered cellular metabolism and the quality of the shunt tube used (9). Echizenya et al. reviewed 25 removed shunts with microscope and showed significant mineralization of the VP shunt (6). They also revealed that the most significant factors for calcification of the VP shunt are patient's age during VP shunting and length of time since tubing. In the present case, the patient was 12-years-old during the shunt surgery and 22 years had been passed since shunting.

Griebel et al. reported three calcified VP shunts which were fractured spontaneously before the removal of the shunt (10). They revealed that shunt catheters were enclosed by mineral deposits observable by the naked eye. These deposits were shown to be associated with weakening of the catheter wall. Spectral examination revealed that the surface deposits to be calcium phosphate.

Microscopic calcification of the soft tissues adjacent to VP shunt tubes is a common finding; however, heavy calcification apparent on plain radiographs is extremely rare. Such a calcification seems to show VP shunt catheter degeneration and should be deeply investigated for a probable disconnection.

In conclusion, as a rare complication calcification of the VP shunts might result in non-function, and might lead to disconnect or rupture of the shunt during neck movements or with patient's growth. Therefore, close follow-up is necessary not only with cranial tomography but also with x-rays of neck, chest and abdomen. Standart radiological examination is not necessary for asymptomatic patients and neurological examination is enough for this group of patients. For symptomatic patients neurological examination is gold standart for follow up period and also cranial tomography is needed.

Çıkar Çatışması: Yazar tarafından çıkar çatışması bildirilmemiştir.

Finansal Destek: Yazar tarafından finansal destek alınmadıkları bildirilmiştir.

Kaynaklar

1. Maruyama H, Nakata Y, Kanazawa A, Watanabe H, Shigemitsu Y, Iwasaki Y, et al. Ventriculoperitoneal shunt outcomes among infants. *Acta Med Okayama* 2015; 69:87-93.
2. Kanik A, Sirin S, Kose E, Eliacik K, Anil M, Helvaci M. Clinical and economic results of ventriculoperitoneal shunt infections in children. *Turk Neurosurg* 2015; 25:58-62.
3. Boch AL, Hermelin E, Sainte-Rose C, Sgouros S. Mechanical dysfunction of ventriculoperitoneal shunts caused by calcification of the silicone rubber catheter. *J Neurosurg* 1998; 88:975-982.
4. Khan F, Rehman A, Shamim MS, Bari ME. Factors affecting ventriculoperitoneal shunt survival in adult patients. *Surg Neurol Int* 2015; 6: 25.
5. Shimotake K, Kondo A, Aoyama I, Nin K, Tashiro Y, Nishioka T. Calcification of a ventriculoperitoneal shunt tube: Case report. *Surg Neurol* 1988; 30: 156-158.
6. Echizenya K, Satoh M, Murai H, Ueno H, Abe H, Komai T. Mineralization and biodegradation of CSF shunting systems. *J Neurosurg* 1987; 67:584-591.
7. Stannard MW, Rollins K. Subcutaneous catheter calcification in ventriculoperitoneal shunts. *AJNR* 1995; 16: 1276-1278.
8. Guevara JA, La Torre J, Denoya C, Zuccaro G. Microscopic studies in shunts for hydrocephalus. *Childs Brain* 1981; 8:284-293.
9. Kural C, Kirik A, Pusat S, Senturk T, Izci Y. Late calcification and rupture: A rare complication of ventriculoperitoneal shunting. *Turk Neurosurg.* 2012; 22:779-82.
10. Griebel RW, Hoffman HJ, Becker L. Calcium deposits on CSF shunts: clinical observations and ultrastructural analysis. *Childs Nerv Syst* 1987; 3:180-182.