

A Rare Complication After Conventional Coronary Angiography: Left Homonymous Hemianopia

Konvansiyonel Koroner Anjiyografi Sonrası Nadir Bir Komplikasyon: Sol homonim Hemianopsi

İhsan Alur¹, Veli Çıtışlı², Gökhan Pekel³, Tevfik Güneş¹, Gökhan Yiğit Tanrısever¹, Gökhan Önem¹

¹Pamukkale Üniversitesi Tıp Fakültesi, Kalp Ve Damar Cerrahisi Anabilim Dalı, Denizli

²Pamukkale Üniversitesi Tıp Fakültesi, Beyin Cerrahisi Anabilim Dalı, Denizli

³Pamukkale Üniversitesi Tıp Fakültesi, Göz Hastalıkları Anabilim Dalı, Denizli

Özet

Koroner arter hastalığının tanısında konvansiyonel koroner anjiyografi altın standart olarak kabul edilmektedir. Ancak tanısal veya girişimsel amaçlı koroner anjiyografi sırasında serebrovasküler olay gerçekleşebilir. Bu durum hastaya ait risklere veya işlemin invaziv olmasına bağlıdır. Hastada yaygın aterosklerotik damar hastalığı, kalsifik veya mural trombus içeren aort anevrizması ya da inflamatuvar aortit gibi patolojilerden biri varsa ateroembolizm için risk oluşturur. Bu yazıda tanısal amaçlı koroner anjiyografiden sonra sol homonim hemianopsi bulgusuyla beyin BT'de serebral enfarktüs tanısı konan olgu sunuldu.

Anahtar Kelimeler: Görme, beyin, enfarkt, koroner, anjiyografi.

Abstract

In coronary artery disease, coronary angiography is considered as a golden standard diagnostic tool. But, during diagnostic or interventional procedure of coronary angiography, cerebrovascular accidents may occur due to the procedure itself or risk factors related to the patient, mainly when the patient has diffuse atherosclerosis, aortic aneurysm with calcification, mural thrombosis or inflammatory aortitis. In this case report, we will present a case of left homonymous hemianopsia (HH) occurred after diagnostic coronary angiography and identified by CT-Scan which showed a cerebral infarction.

Keywords: Vision, brain, infarction, coronary, angiography.

Introduction

The incidence of clinically overt stroke following coronary angiography (CAG) is less than 0.3 %. However, the incidence of asymptomatic cerebral infarct might be significantly higher (1). It has been shown that microemboli may occur in cerebral arteries during CAG (2, 3). Cerebrovascular embolism (CVE) following CAG or left cardiac catheterization is related to many factors. A thrombus might be formed on or around the catheter and might be carried by the guide wire to various cerebral arteries. Additionally, an air embolism or microparticles (debris) that may have separated from atheromatous plaques in the aorta or its branches may cause CVE (4). Occipital infarcts, optic tract damages and lesions of the optic chiasm are the most common reasons of visual field loss following stroke (5). Hemianopsia constitutes 70% of all visual field loss that occur in the cerebral artery infarcts (6). Homonymous visual field defects occur in approximately 8% patients who have experienced a stroke (7). It was shown that the risk of cerebral embolism is higher when CAG is

done via the radial artery when compared to the femoral artery. Additionally, it was reported that microemboli risk is higher in CAG via the right radial artery (2). In our case, we performed a CAG via the right brachial artery, because the patient had peripheral artery disease. In a previous study, it was found that age, hypertension, diabetes and impairment on renal functions were related to the homonymous visual field defects (7).

In this report, we present a case that had left homonymous hemianopsia (HH) and cerebral infarct on cranial CT following coronary angiography.

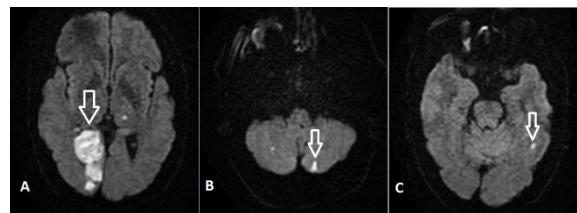

Figure 1. The brain MRI section of the patient.

Case

A 60-year-old man presented to our outpatient facility complaining of bilateral leg pain increasing when walking. The patient had a history of systemic hypertension (HT), diabetes mellitus (DM), peripheral arterial disease and coronary artery disease. Physical examinations showed that his pulse was 86/min, blood pressure was 150/90 mmHg, tibialis anterior and dorsalis pedis pulses were nonpalpable. All other pulses were palpable. ECG showed sinus rhythm. Ejection fraction of the left ventricle was 55% and mild mitral, aortic and tricuspid valve insufficiency was detected in echocardiography. Patient had a history of coronary bypass surgery that was performed 3 years ago. Multislice CT angiography of the lower extremities showed 100% occlusion in the right common iliac artery and left external iliac artery. The diagnosis of peripheral artery disease (PAD) was made and an operation was planned. Because of the older age and having history of coronary heart disease, CAG was done prior to surgery. CAG was performed via the right brachial artery, because of PAD. Following CAG, hematoma developed in the brachial area and the patient was operated immediately to repair the brachial artery injury and embolectomy was performed due to distal embolization.

compensate the loss in his left visual field. A diffusion-weighted MR imaging (MRI) was planned with the indication of cerebrovascular event. We detected acute-subacute right occipital infarct, millimetric embolic lesions in the thalamus, cerebellar hemisphere, and left temporal lobe (Figure 1A, 1B, 1C). Left HH was detected in the visual field analysis (Figure 2A, 2B). The other ocular examinations did not show any pathology. Sensorimotor and cognitive functions were completely normal except for left HH.

Discussion

Visual perception is a process that originates from the retinal ganglion cells to the occipital cortex requiring the use of almost half of the neocortex. Depending on the location of the lesion affecting the afferent eye pathway, different visual field loss (VFL) patterns may occur. Especially occipital lesions may cause symmetrical, contralateral homonymous hemianopia (HH) (8). Prevalence of HH after stroke is between 1.1 and 10% (7). However, prevalence of isolated unilateral temporal VFL due to the occipital infarct is not known (6). Stroke is not the only causal factor of VFL. Tumor, trauma, infections, and congenital factors are other etiological factors. Still, 40-90% of the VFL occur as a result of cerebral artery infarcts (7). HH might recover spontaneously, although most of the cases resolve with sequels.

In our case, the visual field of the patient showed the characteristic HH with macular sparing seen in occipital lobe lesions. Since the comorbidity factors such as DM, HT, and coronary bypass surgery history were present, the possibility of cerebral infarction after CAG was relatively high in our patient. In this case, the right brachial artery was used for CAG. Jurga et al. revealed that more particulate microemboli passes the right middle cerebral artery than the left middle cerebral artery with the right radial access CAG when compared with the femoral access, maybe because of the catheters have to pass the apertures of the

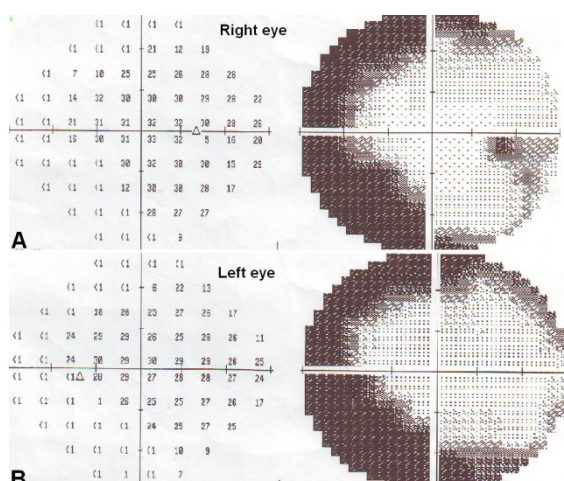


Figure 2. Visual field analysis of the patient (A: right eye, B: left eye).

In the next day, the patient complained of lack of vision on the left visual field, and told us that he had to turn his head to the left in order to

right brachiocephalic artery and curve sharply into the ascending aorta, which may separate atherosclerotic plaques (2). The above statement about the increased cerebral emboli risk in right cerebral artery during upper extremity CAG also conforms to our patient, since he had left HH.

Patients with hemianopsia may have serious problems while moving independently at home or outside, driving, reading, or accommodation in an unfamiliar environment or situations (9). In many countries, patients with hemianopsia or quadrantanopsia are not allowed to bear a driving license (6). The duration required to diagnose stroke-related VFL is long and functional outcomes are generally worse in these patients than in the patients with stroke only. Therefore, early diagnosis and treatment are important. Gilhotra et al. revealed that only 30% of patients having stroke related VFL were aware of their VFL. In the same study, only 7 of 25 patients with homonymous visual field defects reported to stop driving, while 12 kept driving, and 6 had never driven (7). This is a serious problem. We advice that even if patients do not have visual complaints, visual field test should be performed in cases possessing high risk of cerebral infarction development after CAG.

References

1. Sankaranarayanan R, Msairi A, Davis GK. Stroke complicating cardiac catheterization—a preventable and treatable complication. *J Invasive Cardiol.* 2007;19:40–5.
2. Jurga J, Nyman J, Tornvall P, Mannila MN, Svenarud P, van der Linden J, Sarkar N. Cerebral Microembolism During Coronary Angiography: A Randomized Comparison. *Stroke.* 2011;42:1475-7.
3. Azarpazhooh MR, Chambers BR. Clinical application of transcranial Doppler monitoring for embolic signals. *J Clin Neurosci.* 2006;13:799–810.
4. Hamon M, Lipiecki J, Carrié D, Burzotta F, Durel N, Coutance G, Boudou N, Colosimo C, Trani C, Dumonteil N, Morello R, Viader F, Claise B, Hamon M. Silent cerebral infarcts after cardiac catheterization: A randomized comparison of radial and femoral approaches. *Am Heart J.* 2012;164:449-54.
5. Keklikoglu HD, Yoldas TK, Coruh Y. A case report of bilateral superior altitudinal hemianopia with cerebral infarction. *Neurologist.* 2010;16:132-5.
6. Güler S, Keleş A, Demircan A, Cumali Doğru, Gülşah Yavuz. Occipital Infarcts Presenting with Isolated Temporal Vision Loss: A Report of Two Cases and Review of the Literature. *Turk J Emerg Med.* 2011;11:28-31.
7. Gilhotra JS, Mitchell P, Healey PR, Cumming RG, Currie J. Homonymous visual field defects and stroke in an older population. *Stroke.* 2002;33:2417-20.
8. Kansu T. [Brain and Vision]. *Turkish Journal of Neurology.* 2004;10: 85-91.
9. Nelles G, Widman G, de Greiff A, Meistrowitz A, Dimitrova A, Weber J, Forsting M, Esser J, Diener HC. Brain representation of hemifield stimulation in poststroke visual field defects. *Stroke.* 2002;33:1286-93.

