

Is Familial Mediterranean Fever a Risk Factor for Malignant Peritoneal Mesothelioma: A Case Presentation and Literature Review

Ailesel Akdeniz Ateşi Malign Periton Mezotelyoma için bir Risk Faktörü mü: Bir Olgu Sunumu ve Literatür Taraması

Şafak Şahin¹, Soner Şenel², Saadetin Kılıçkap³

¹Gaziosmanpaşa Üniversitesi, Tıp Fakültesi, İç Hastalıkları Anabilim Dalı, Tokat

²Erciyes Üniversitesi, Tıp Fakültesi, Romatoloji Bilim Dalı, Kayseri

³Hacettepe Üniversitesi, Tıp Fakültesi, Onkoloji Bilim Dalı, Ankara

Özet

Ailesel Akdeniz ateşi (AAA) ateş ve serozal inflamasyon ile karakterize kalıtsal bir hastalıktır. Malign mezotelyoma (MM) primer olarak plevranın daha az yaygın olarak da periton, perikard ve tunika vaginalisin bir tümörüdür. MM, AAA hastalarında çok nadirdir ve aralarındaki ilişki açık değildir. MM ve AAA arasında az sayıda vaka çalışmalarında bir ilişki rapor edilmiştir. Bu noktada, biz daha önce AAA tanısı olan karın ağrısı ve şişkinlik şikayetleri ile başvuran 51 yaşında bir Türk erkek hasta rapor ediyoruz ve MM ile AAA arasındaki tartışmalı ilişkiyi literatür değerlendirmesi ile ortaya koyuyoruz.

Anahtar Kelimeler: Ailesel Akdeniz ateşi, Malign mezotelyoma, M694V mutasyonu.

Abstract

Familial Mediterranean fever (FMF) is an inherited disorder characterized by episodes of fever and serosal inflammation. Malignant mesothelioma (MM) is a primary tumor of the pleura and less commonly of the peritoneum, pericardium and tunica vaginalis. MM is very rare in patients with FMF and its association is unclear. An association between MM and FMF was reported in a small number of previous case studies. Herein we report the case of a 51-year-old Turkish male patient with a previous diagnosis of FMF presenting with abdominal pain and distension which were found to be due to MM and discuss their association by means of a literature review.

Keywords: Familial Mediterranean fever, malignant mesothelioma, M694V.

Introduction

Familial Mediterranean fever (FMF) is an inherited disorder characterized by episodes of fever and serosal inflammation. It is a genetic disease with autosomal recessive inheritance and ethnic predilection. FMF occurs predominantly in Turks, Armenians, Arabs, and Sephardic Jews. A familial Mediterranean fever gene (MEFV) has been identified on the short arm of chromosome 16, and several mutations in this gene have been identified in FMF patients (1). The disease and its complications are usually controlled with colchicine treatment (2).

Malignant mesothelioma (MM) is a primary tumor arising in the pleura or, less commonly, in the peritoneum and pericardium. Risk factors associated with its development include asbestos exposure, chronic irritation or inflammation of the peritoneum, abdominal radiotherapy, FMF and simian virus 40. MM in

patients with FMF is very rare and its association with FMF is equivocal (3). There are only a few reports of patients with FMF and malignant peritoneal mesothelioma (MPM). In this paper we report the case of a patient with a previous diagnosis of FMF presenting with abdominal pain and distension which were found to be due to MPM and discuss their association by means of a literature review.

Case report

A 51-year-old Turkish male patient was admitted to our hospital because of abdominal pain and distention. He had been diagnosed with FMF because of recurrent fever and abdominal pain attacks with familial history over the last 20 years. Genetic analysis revealed that the patient was heterozygote for the M694V mutation in the MEFV gene. He suffered about 10 to 15 recurring peritoneal

attacks a year. In the last year, he had experienced unusual attacks of FMF with continuous and consistent levels of abdominal pain and distension accompanied by subfebrile fever lasting longer than 10 days. He did not use colchicine regularly. There were no risks of malignancies. The patient had never smoked and there was no history of malignancies in his family. Although FMF is endemic in the city of Sivas in Turkey, there was no history of exposure to asbestos. There were no findings of systemic secondary amyloidosis. His laboratory evaluations were as follows: Hemoglobin: 11.2 g/dL (12-18 g/dl), ESR: 58 mm/1 h (0-15 mm/h), CRP: 5.3 mg/dL (0.0-0.8). Abdominal ultrasonography detected ascites in the patient. Examination of the peritoneal biopsy material revealed malignant mesothelioma (epithelioid type, positive calretinin WT:20% nuclear positive, cytokeratin 5/6:70-80% positive cytoplasmic, mesothelin: 40-50% luminal positive) (Fig 1). The patient was treated with combination chemotherapy including cisplatin (80 mg/m²/day) and pemetrexed (500 mg/m²/day) every 21 days. However he died one month later.

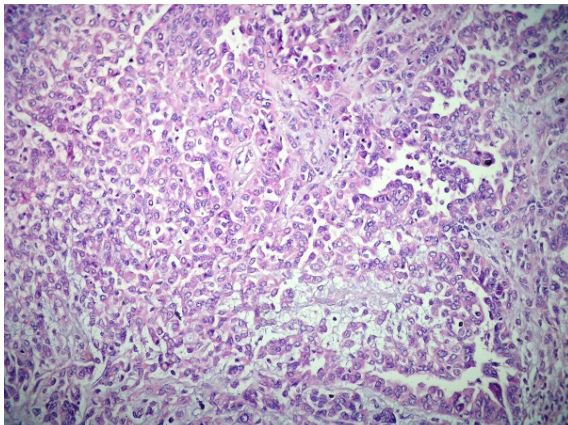


Figure 1: Peritoneal biopsy shows malignant mesothelioma cells (H&E x 200)

Discussion

Familial Mediterranean fever (FMF) is a disorder characterized by sporadic, paroxysmal attacks of fever and serosal inflammation. FMF occurs primarily in several ethnic groups originating in the Mediterranean littoral (1). MM is a rare neoplasm arising most commonly from the mesothelial surfaces of the pleural cavity, occasionally from the peritoneal

surface, and rarely from the tunica vaginalis or pericardium. Asbestos exposure is the most common etiological factor. However, exposure to other fibers, mineral dust, various chemicals, and ionizing radiation as well as chronic serosal inflammation is also considered to increase the risk for these tumors (3). MM in patients with FMF is very rare and its association with FMF is equivocal. In the literature there are only a four reports of patients with FMF and peritoneal mesothelioma (4-6).

We reviewed a total of 5 patients (4 male) with FMF and MPM. Some comparable parameters in our case and in other cases are summarized in Table 1. The ethnicities of these patients were as follows: 2 of Jewish Moroccan, one of Turkish, one of Italian and one of Arabic Jordanian ancestry. The median disease duration of FMF was 30 years. In cases 1 and 2, there were no data about MEFV mutations and use of colchicine. Meanwhile, the presence of no other mutations apart from M694V mutations in three of the cases was also meaningful. The minimal disease duration was 20 and the maximum was 45 years.

There is some evidence to support a possible association between mesothelioma and FMF. Only %10-30 of MM is peritoneal mesothelioma. Current studies have found a strong association between peritoneal mesothelioma and asbestos exposure (7). However in our case, there was no history of exposure to asbestos. The distribution of reported mesothelioma characteristics is different in patients with FMF than in mesothelioma in general. When most mesotheliomas are pleural, those in patients with FMF are mainly peritoneal consistent with the fact that peritoneal inflammation is more common than pleural inflammation in FMF. Four of five published cases are peritoneal mesothelioma. There are multiple consistent lines of evidence linking inflammation to cancer. The inflammatory process is a co-factor in carcinogenesis in various malignancies. Examples include the association of hepatitis B and C virus infection with hepatocellular carcinoma (8), inflammatory bowel disease

with colorectal cancer (9), and Barrett’s metaplasia with esophageal cancer (10).

It is important that there was no association with asbestos exposure (only in one of the five cases) and that the disease period was longer than 20 years. Although there is no certain evidence about the relation between FMF and MPM, the number of published case studies in literature is increasing. Furthermore in some studies, the link between chronic inflammatory disease and risk of malignancy was shown (4-6). Our case has some similarities which those reported in the literature such as M694V mutation, duration of disease and middle age. No history of asbestos exposure, long duration of disease (20+ years) and frequent episodes of peritonitis supported the relation between FMF and peritoneal malignant mesothelioma in our patient.

Conclusion

We suggested that if a patient with M694V mutation and long disease period presents atypical FMF signs i.e. prolonged fever, abdominal pain, distention, we should consider the possibility of peritoneal malignancy. Further studies are required to clarify whether the occurrence of FMF together with MPM is only a coincidence or there is an association between them.

References

1. Ben-Chetrit E, Levy M. Familial Mediterranean fever. *Lancet* 1998; 351: 659-64.
2. Onen F. Familial Mediterranean fever. *Rheumatol Int* 2006; 26:489-96
3. Bani-Hani KE, Gharabeh KA. Malignant peritoneal mesothelioma. *J Surg Oncol* 2005; 91:17-25.
4. Chahinian AP, Pajak TF, Holland JF, Norton L, Ambinder RM, Mandel EM. Diffuse malignant mesothelioma. Prospective evaluation of 69 patients. *Ann Intern Med* 1982; 96:746-55.
5. Gentiloni N, Febbraro S, Barone C, Lemmo G, Neri G, Zannoni G, Capelli A, Gasbarrini G. Peritoneal mesothelioma in recurrent familial peritonitis. *J Clin Gastroenterol* 1997; 24: 276-9.
6. Hershcovici T, Chajek-Shaul T, Hasin T, Aamar S, Hiller N, Prus D, Peleg H. Familial Mediterranean fever and peritoneal malignant mesothelioma: a possible association? *Isr Med Assoc J* 2006; 8:509.
7. Welch LS, Acherman YI, Haile E, Sokas RK, Sugarbaker PH. Asbestos and peritoneal mesothelioma among college-educated men. *Int. J. Occup. Environ Health* 2005; 11: 254-8.
8. Fattovich G, Stroffolini T, Zagni I, Donato F. Hepatocellular carcinoma in cirrhosis: incidence and risk factors. *Gastroenterology* 2004; 127:35–50.
9. Itzkowitz S H; Yio X. Inflammation and cancer. IV. Colorectal cancer in inflammatory bowel disease: the role of inflammation. *Am. J. Physiol. Gastrointest Liver Physiol* 2004; 287:7–17.
10. Hesketh PJ, Clapp RW, Doos WG, Spechler SJ. The increasing frequency of adenocarcinoma of the esophagus. *Cancer* 1989; 64: 526–30.

Table 1: Characteristics of patients with FMF and MM.

	case 1 (Ref.2)	case 2 (Ref.3)	case 3 (Ref.4)	case 4 (Ref.4)	case 5 (our case)
Age (year)	49	unknown	61	38	51
Sex	male	male	male	female	male
Period of disease	25	unknown	45	30	20
Ethnic group	Arabian(Jordan)	Turkish	Jewish(Morocco)	Jewish(Morocco)	Turkish
MEFV mutation	unknown	unknown	Homozygote M694V	Homozygote M694V	Heterozygote M694V
Use of colchicine	unknown	unknown	regular	irregular	irregular
Exposure to asbestos	yes	no	no	no	no

