

RESEARCH

Estimation of the trabecular structure of alveolar bone before implant planning in orthodontic treated patients by using fractal analysis method

Gülbahar Ustaoglu(0000-0002-4205-861X)^α, Duygu Göller Bulut(0000-0003-4260-2520)^β,
Emine Şebnem Kurşun Çakmak(0000-0002-7113-5450)^γ, Burak Sarıoğlu(0000-0003-4648-9369)^λ,
Handan Ankaralı(0000-0002-3613-0523)^μ

Selcuk Dent J, 2020; 7: 259-264 (Doi: 10.15311/selcukdentj.549719)

Başvuru Tarihi: 05 Nisan 2019
Yayına Kabul Tarihi: 27 Ağustos 2019

ABSTRACT

Estimation of the trabecular structure of alveolar bone before implant planning in orthodontic treated patients by using fractal analysis method

Background: The aim of this study was to assess the trabecular bone pattern changes of orthodontically treated patients before orthodontic treatment (T0), immediately after (T1) and 6 months after (T2) the treatment by using fractal dimension (FD) analysis in order to guide implant applications.

Methods: Totally 32 orthodontic patients who had one missing tooth were included in the study. Patients were treated to align the teeth and to create a dimensionally appropriate space for implant placement. Panoramic radiographs were taken with standard protocols at the time periods of before (T0), immediately after (T1) and 6 months after (T2) treatment. FD analysis was performed using Image J 1.3 software with the box-counting method.

Results: The highest FD value was measured before treatment (T0=1.47±0.14). Mean FD values of T2 was found statistically significantly higher (1.32±0.14) than T1 (1.19±0.15) (p<0.001).

Conclusion: It is suggested not to plan implant surgery immediately after the end of orthodontic treatment because trabecular bone gains more complex nature over time. FD analysis is a simple and cost-effective tool for examining bone structure in panoramic radiographs.

KEYWORDS

Alveolar bone, dental implants, fractal analyses, orthodontics, panoramic radiography

ÖZ

Ortodontik tedavi görmüş hastalarda implant planlaması öncesinde fraktal analiz yöntemi kullanılarak alveolar trabeküler kemik yapısının tayini

Amaç: Bu çalışmanın amacı, ortodontik tedavi gören hastaların implant tedavisinde rehber olması amacıyla, ortodontik tedavi öncesinde (T0), hemen sonrasında (T1) ve 6 ay sonrasında (T2) trabeküler kemik değişikliklerini fraktal boyut (FD) analizini kullanarak değerlendirmektir.

Gereç ve Yöntemler: Çalışmaya bir dişi eksik olan toplam 32 ortodonti hastası dahil edildi. Hastalar dişleri hizalamak ve implant yerleştirmek için boyutsal olarak uygun bir alan oluşturmak için tedavi edildi. Panoramik radyografiler standart protokollerle sabit ortodontik tedavi öncesinde (T0), hemen sonrasında (T1) ve 6 ay sonrasında (T2) alındı. FD analizi Image J 1.3 yazılımı kullanılarak kutu sayma yöntemiyle yapıldı.

Bulgular: En yüksek FD değeri tedavi öncesinde ölçüldü (T0 = 1.47 ± 0.14). T2' nin ortalama FD değeri (1.32 ± 0.14), T1'den (1.19 ± 0.15) istatistiksel olarak anlamlı derecede yüksek bulundu (p < 0.001).

Sonuç: Trabeküler kemik zamanla daha karmaşık bir yapı kazandığından, ortodontik tedavinin sona ermesinden hemen sonra implant ameliyatı planlanmaması önerilmektedir. FD analizi kemik trabekül yapısını panoramik radyografilerde incelemek için basit ve uygun maliyetli bir yöntemdir.

ANAHTAR KELİMELER

Alveolar kemik, dental implantlar, fraktal analizler, ortodonti, panoramik radyografi

Orthodontic tooth movement leads to a biological response of the surrounding tissues of the teeth, resulting in a remodelling of the periodontal ligament and the alveolar bone.¹ Tooth movement causes resorption of pre-existing alveolar bone tissue and provides new bone tissue formation in the process of bone remodelling. Moreover, the new alveolar bone tissue owns less mineral content than the pre-existing

bone tissue, so bone quality changes.^{2,3} Changes of alveolar bone quality due to active bone remodelling during and after orthodontic treatment have been observed by many studies including rat and finite element models.⁴⁻⁹ However, only limited number of human studies was conducted for evaluation of quantitative bone quality.^{10,11}

^α Bolu Abant İzzet Baysal University, Dentistry Faculty, Department of Periodontology, Bolu

^β Bolu Abant İzzet Baysal University, Dentistry Faculty, Department of Dentomaxillofacial Radiology, Bolu

^γ Türkiye Public Hospitals Agency, Ministry of Health, Ankara

^λ Bolu Abant İzzet Baysal University, Dentistry Faculty, Department of Orthodontics, Bolu

^μ Medeniyet University, Medical Faculty, Department of Biostatistics, İstanbul

The trabecular bone structure can be evaluated using different procedures like strut analysis, fractal dimension (FD) analysis, and visual observation on two-dimensional plain radiographs whereas specific imaging software is used in three-dimensional (3D) imaging modalities.¹²⁻¹⁴ 3D radiographs are the methods that are not used in every patient and are not available in all clinics. However, the inexpensive panoramic radiographs provide information about the maxillary and mandibular bone without undue exposure.¹⁵ Among the aforementioned techniques, FD analysis is a mathematical method that can be used to identify complex structure like trabecular bone.^{16,17} FD analysis is an objective and quantitative evaluation method which provides some information about bone tissues in a non-invasive way and is used to evaluate bone changes associated with apical periodontitis, periodontal disease, bone surgery and systemic diseases.^{18,19}

Dental implant treatment is a widely used method for edentulous areas after orthodontic treatment. The structure of the trabecular bone is critical for the stability of the dental implants.²⁰ Changes of the trabecular structure after orthodontic treatment have been researched in recent years. However, there is no consensus about the schedule (or timing) of dental implant placement after orthodontic treatment. It is a controversial issue to what extent clinicians should wait for bone formation before the implant placement to obtain appropriate osteointegration.

In this study, it was aimed to evaluate the changes in the trabecular bone pattern of orthodontically treated patients by using FD analysis before orthodontic treatment (T0), immediately after orthodontic treatment (T1) and 6 months after treatment (T2) to guide the implant therapy of patients.

MATERIALS AND METHODS

The study protocol was approved by the Clinical Ethical Committee of Bolu Abant İzzet Baysal University (institutional review board number: 2017/149).

Totally 32 orthodontic patients who had been applied to Bolu Abant İzzet Baysal University, Faculty of Dentistry, Department of Orthodontics were examined. Patients who had any systemic disease that might influence bone density (such as osteopetrosis, osteoporosis, hypohyperparatroidism), and had periodontal disease or alveolar bone loss before treatment; any visible anomalies and pathologic lesions were also excluded. Patients not complying with similar treatment period (1.5 years \pm 6 months) and patients who smoke were also excluded from the study.

All patients had one missing tooth; of these; 13 were in the maxilla (9 teeth were left lateral incisor and 4 teeth were right lateral incisor) and 19 were in the mandible (8 teeth were right first molar and 11 teeth were left first molar). Lateral incisors were congenitally missing and molars were extracted in childhood period with unknown reasons. There was a tipping of the adjacent teeth to the area where tooth loss occurred. Treatments were performed to align the teeth and create a dimensionally appropriate space for implant placement. Orthodontic treatments were performed by the same clinician with the experience of 5 years and a similar appliance system [0.022 inches, MBT prescription, Mini Master Series American Orthodontics metal brackets (Sheboygan, WI, USA)] were used. Similar materials and with similar strategies were used in all the subjects: type of arch wire [NT3™ SE NiTi - Nickel Titanium Arch Wire (American Orthodontics, Sheboygan, WI, USA), Stainless Steel Wire (SS) (American Orthodontics, Sheboygan, WI, USA), elastomeric ligatures, elastomeric chains, elastics and separators (American Orthodontics, Sheboygan, WI, USA). At the end of orthodontic treatment, for all patients, ideal crown and root positions and appropriate space for implant placement were provided. Panoramic radiographs were taken by the same machine (Soredex Cranex Novus, Tuusula, Finland) with standard protocols at the time periods of T0, T1 and T2.

FD analysis of each patient was performed three times as suggested by White and Rudolph²¹ using the box-counting method both for T0, T1 and T2. The images were analysed using ImageJ version 1.3 software (National Institutes of Health, MD, USA). Periodontal ligament, lamina dura, and related regions, and root apices were excluded to avoid false interpretation caused by inflammatory alterations. FD measures of the trabecular bone were measured from the expansion space for one implant area between the expanded teeth. In **Figure 1**, fractal analysis region of interest (ROI) is demonstrated.

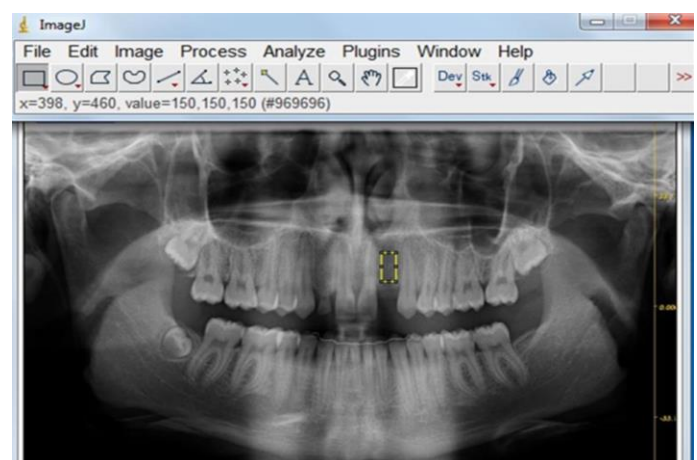


Figure 1.

Panoramic radiograph with selected ROI. Lamina dura, periodontal ligament and related regions, and root apices were not included within the

The high resolution panoramic radiographs of the patients were converted into tagged image file formats (TIFFs). Region of interest (ROI) was selected with the size of 53x25 pixels, cropped, and duplicated. Gaussian blur was used to blur the high and medium-bright areas in the image, which was due to the variable thickness of bone and the superficial soft tissue covering the bone. The resulting image was then subtracted from the original image, adding 128 gray tones for each pixel. Then binary process, erode, dilate, invert, and skeletonize process were performed and FD was calculated (Figure 2).




Figure 2.

A) Blurred image of the cropped and duplicated ROI, **B)** The duplicated image was blurred with a Gaussian filter, **C)** The blurred image was then subtracted from the original image, **D)** Addition of 128 gray value to each pixel location, **E)** Binarization, **F)** Dilatation, **G)** Inversion, **H)** Skeletonization.

All measurements were conducted by a single observer (dentomaxillofacial radiologist). The intra-observer reliability of FD analysis of the trabecular structure was assessed by re-evaluating T0, T1 and T2 on randomly selected 15 panoramic images at a 2-weeks interval by using intra-class correlation coefficient (ICC) with a confidence interval (CI) of 95%.

Power analysis

For power analysis, at the beginning of the study, the meaningful difference - effect size - between the initial period and the 6th month measurements was accepted as 0.20, 0.25 and the type-I error was accepted as 5%, and also the power of test was accepted as 80%. Using this information, the minimum required sample size was calculated as 25. After data analysis, posterior power analysis was performed, and it was seen that there was a significant difference between the 3 periods with 99% power. G*Power (ver. 3.0.10) was used for sample size determination.

Statistical analysis

Simple Repeated measurement analysis of variance model was used for comparisons. p value was accepted as statistical significance if lower than 0.05 level. Statistical analyses were done with SPSS for Windows SPSS® v. 16.0 (IBM Corp., New York, NY; formerly SPSS Inc., Chicago, IL)

RESULTS

The systemic intra-examiner error was evaluated at $p < 0.05$ and found to be statistically insignificant. The intraclass correlation coefficient (ICC) measurements indicated good reliability both for T0, T1 and T2 with a mean ICC of 0.853 (0.832-0.871), 0.847 (CI = 0.797-0.863) and ICC of 0.861 (CI=0.839-0.875), respectively. Of the patients examined, 8 (25%) were female and 24 (75%) were male. The mean age of patients was 28.84 ± 9.86 (range between 16 and 56 years) The mean age for male was 28.50 ± 9.54 years (range between 16 and 56 years) and for female was 29.87 ± 11.38 years (range between 20 and 43 years), no significant difference was found in distribution of age according to gender ($p = 0.739$).

When we compared FD values that measured time periods of T0, T1, and T2, a statistically significant difference was observed ($p < 0.001$) between them. Mean FD values of T0 was the highest ($FD 1.47 \pm 0.14$). T2 followed it with a mean FD value of 1.32 ± 0.14 . The lowest mean FD value was measured at T1 time period (1.19 ± 0.15) (Table 1).

Table 1.

Comparison of mean FD values of T0, T1, and T2 groups with range and standard deviation (SD)

Time Period	N	Mean of FD	Minimum	Maximum	SD	P value
T0	32	1.47 ^a	1.07	1.71	0.14	
T1	32	1.19 ^b	0.86	1.50	0.15	<0.001
T2	32	1.32 ^c	1.05	1.64	0.14	

DISCUSSION

Dental implant treatment is the most widely used treatment modality to treat edentulous areas after orthodontic treatment. It is a known fact that there must be sufficient bone support to perform implant treatment. Therefore, it is necessary to evaluate the quality of the bone to select the appropriate side and suitable implant.²² In addition to giving appropriate positions to the teeth, orthodontic treatment also lead some changes in the density of surrounding bone which may affect implant stability.²³

In the dental literature, there are some studies showing that bone density or quality is assessed by Hounsfield units (HU) values⁵ and grey scale values on cone beam computed tomography (CBCT)²⁴ and FD analysis on two-dimensional radiographs.^{18,25,26} CBCT and other 3D radiography modalities give more accurate results and provide more details, but using them routinely for orthodontic therapy seem unneeded, because these techniques have high cost and significant

radiation doses.¹⁰ Therefore, panoramic radiographs can be useful in the evaluation of trabecular pattern and used in orthodontic treatment follow-up. Therefore, this retrospective study was carried out by performing FD analysis on panoramic radiographs.

In some previous studies evaluating the effects of orthodontic treatment on alveolar bone, it has been reported that orthodontic tooth movement can reduce bone density around the teeth^{5,23,27,28}, whereas in some studies the opposite was stated.²⁸⁻³⁰ Campos et al³¹ showed that the bone density around the teeth after orthodontic treatment was similar with pretreatment values. The results of previous studies about the effect of orthodontic treatment on bone density around teeth are variable. In a study by Yu et al²⁴ using CBCT, before the orthodontic treatment, after 7 months of active orthodontic treatment and 20-22 months after the end of the treatment, the bone density around the teeth was evaluated by measuring the grey scale values in CBCT. They reported that the alveolar bone density around the teeth have decreased during orthodontic tooth movement. However, they noted that after a period of bone healing (about 20-22 months after orthodontic treatment), the decreased bone density returned to its baseline state prior to orthodontic treatment. Hsu et al⁵ evaluated HU values of the maxillary anterior teeth using the CBCT images of 8 patients at immediately before the end of the 7-months orthodontic treatment and immediately after the end of the treatment and reported a significant decrease in bone density. In the present study, FD values of trabecular bone were found similar with the results of Yu et al²⁴ and Hsu et al⁵, FD values measured at the end of active orthodontic treatment (T1) were lower than the initial values (T0), and the measured FD value after a 6-months waiting period (T2) approached to the pre-treatment state (T0). Usage of an orthodontic retainer for a period of time following active orthodontic treatment may lead the increase of bone density. This can be attributed to the increase in FD values.

When we evaluated the previous studies evaluating bone by FD analysis; we saw that different results are presented. Wilding et al³² performed FD analysis using panoramic radiographs to evaluate alveolar bone changes in 18 patients after implant treatment. The results of the study showed that bone changes in the implant neck were remarkable and this change was considered an FD increase in relation to an increase in trabecular complexity. Araújo et al³³ used FD analysis to evaluate osteoclastic activity induced by the orthodontic load on rabbit mandibles and found a strong correlation between the number of osteoclasts and fractal dimension. The authors concluded that osteoclastic activity induced to an increase in bone surface irregularity, which was quantified by its fractal dimension. Lee et al³⁴ evaluated the relationship between the implant stability coefficient (ISQ) and the FD measurement in 52 implant regions on panoramic radiography and found a significant positive correlation between them. These fractal findings show similarity to the current study results, but we evaluated bone quality by only fractal analysis not by histological or other methods because of human ethics.

In contrast with the present study result, Rothe et al³⁵ used FD to analyze the trabecular bone structure on the periapical radiographs as a risk factor in orthodontic relapse of mandibular incisors and found no statistically significant differences in the trabecular structure of bone, as measured with fractal analyses, between the relapse and stable groups. Similarly, Jung et al³⁶ retrospectively evaluated the structural changes in the alveolar bone of 12 patients with 35 implants from one week to six months after implantation using panoramic radiographs. They have reported no significant change in FD values until six months after implant placement. It is thought that the differences between the results of these studies are due to different sample size, radiographic methods, and different ROIs. Several studies have evaluated the reliability of FD calculations from radiographs, finding that they are not sensitive to small alignment variations or over- or sub-exposure. Furthermore, ROI placement has more critical importance than ROI size.³⁷ In our study, we used standardized panoramic radiographs and attentively placed ROI not involving lamina dura, periodontal ligament, and related regions, and root apices to prevent the potential unknown effects of these factors. The most commonly used method in the literature to calculate FD is box counting, which was also used in the present study to evaluate the trabecular structure of mandible.³⁸

To our knowledge, no published papers have focused on trabecular bone structure change of orthodontically treated patients over time before implant application. The results of this study confirmed that FD scores (or values) significantly increased after 6 months of treatment, suggesting an increase in the amount of bony microstructure in the trabecular bone structure. Also, FD measurements were conducted only at three time points (before, immediately after and 6 months after the treatment) with no long-term follow-up because of the closure risk of the tooth space.

CONCLUSION

Clinicians should be cautious when planning implant surgery to patients whose orthodontic treatment just completed and had decreased bone quality. Because negative bone changes as decreased bone quality can affect primary stability, osseointegration and success of dental implants. A delay should be advisable after completion of fixed orthodontic therapy for the placement of endosseous implants. We cannot claim whether trabecular structures alone can predict primary stability and successful osseointegration because many factors can affect. The findings of this study provide only preliminary evidence and further researches are required utilizing larger samples with long term follow-up and histological examination.

REFERENCES

1. Isola G, Matarese G, Cordasco G, Perillo L, Ramaglia L. Mechanobiology of the tooth movement during the orthodontic treatment: a literature review. *Minerva stomatologica*. 2016; 65(5): 299-327.
2. Roschger P, Fratzl P, Eschberger J, Klaushofer K. Validation of quantitative backscattered electron imaging for the measurement of mineral density distribution in human bone biopsies. *Bone*. 1998; 23(4): 319-26.
3. Ruffoni D, Fratzl P, Roschger P, Klaushofer K, Weinkamer R. The bone mineralization density distribution as a fingerprint of the mineralization process. *Bone*. 2007; 40(5): 1308-19.
4. King GJ, Keeling SD, Wronski TJ. Histomorphometric study of alveolar bone turnover in orthodontic tooth movement. *Bone*. 1991; 12(6): 401-9.
5. Hsu JT, Chang HW, Huang HL, Yu JH, Li YF, Tu MG. Bone density changes around teeth during orthodontic treatment. *Clinical oral investigations*. 2011; 15(4): 511-9.
6. Chang HW, Huang HL, Yu JH, Hsu JT, Li YF, Wu YF. Effects of orthodontic tooth movement on alveolar bone density. *Clin Oral Investig*. 2012; 16(3): 679-88.
7. Verna C, Dalstra M, Melsen B. The rate and the type of orthodontic tooth movement is influenced by bone turnover in a rat model. *European journal of orthodontics*. 2000; 22(4): 343-52.
8. Cattaneo PM, Dalstra M, Melsen B. The finite element method: a tool to study orthodontic tooth movement. *Journal of dental research*. 2005; 84(5): 428-33.
9. Liang W, Rong Q, Lin J, Xu B. Torque control of the maxillary incisors in lingual and labial orthodontics: a 3-dimensional finite element analysis. *American journal of orthodontics and dentofacial orthopedics: official publication of the American Association of Orthodontists, its constituent societies, and the American Board of Orthodontics*. 2009; 135(3): 316-22.
10. Haghnegahdar A, Zarif Najafi H, Sabet M, Saki M. Assessment of the changes in alveolar bone quality after fixed orthodontic therapy: A trabecular structure analysis. *Journal of dental research, dental clinics, dental prospects*. 2016; 10(4): 201-6.
11. Huang H, Richards M, Bedair T, Fields HW, Palomo JM, Johnston WM, et al. Effects of orthodontic treatment on human alveolar bone density distribution. *Clinical oral investigations*. 2013; 17(9): 2033-40.
12. Genant HK, Jiang Y. Advanced imaging assessment of bone quality. *Annals of the New York Academy of Sciences*. 2006; 1068: 410-28.
13. Hwang JJ, Lee JH, Han SS, Kim YH, Jeong HG, Choi YJ, et al. Strut analysis for osteoporosis detection model using dental panoramic radiography. *Dento maxillo facial radiology*. 2017; 46(7): 20170006.
14. Faber TD, Yoon DC, Service SK, White SC. Fourier and wavelet analyses of dental radiographs detect trabecular changes in osteoporosis. *Bone*. 2004; 35(2): 403-11.
15. Ibrahim N, Parsa A, Hassan B, Van der Stelt P, Wismeijer D. Diagnostic imaging of trabecular bone microstructure for oral implants: a literature review. *Dentomaxillofacial Radiology*. 2013; 42(3): 20120075.
16. Buckland-Wright JC, Lynch JA, Rymer J, Fogelman I. Fractal signature analysis of macroradiographs measures trabecular organization in lumbar vertebrae of postmenopausal women. *Calcified tissue international*. 1994; 54(2): 106-12.
17. Fazzalari NL, Parkinson IH. Fractal properties of cancellous bone of the iliac crest in vertebral crush fracture. *Bone*. 1998; 23(1): 53-7.
18. Gumussoy I, Miloglu O, Cankaya E, Bayrakdar IS. Fractal properties of the trabecular pattern of the mandible in chronic renal failure. *Dento maxillo facial radiology*. 2016; 45(5): 20150389.
19. de Molon RS, de Paula WN, Spin-Neto R, Verzola MH, Tosoni GM, Lia RC, et al. Correlation of fractal dimension with histomorphometry in maxillary sinus lifting using autogenous bone graft. *Brazilian dental journal*. 2015; 26(1): 11-8.
20. Pham D, Kiliaridis S. Evaluation of changes in trabecular alveolar bone during growth using conventional panoramic radiographs. *Acta odontologica Scandinavica*. 2012; 70(2): 127-32.
21. White SC, Rudolph DJ. Alterations of the trabecular pattern of the jaws in patients with osteoporosis. *Oral surgery, oral medicine, oral pathology, oral radiology, and endodontics*. 1999; 88(5): 628-35.
22. Jeong KI, Kim SG, Oh JS, Jeong MA. Consideration of various bone quality evaluation methods. *Implant dentistry*. 2013; 22(1): 55-9.
23. Verna C, Zaffe D, Siciliani G. Histomorphometric study of bone reactions during orthodontic tooth movement in rats. *Bone*. 1999; 24(4): 371-9.
24. Yu JH, Huang HL, Liu CF, Wu J, Li YF, Tsai MT, et al. Does Orthodontic Treatment Affect the Alveolar Bone Density? *Medicine*. 2016; 95(10): e3080.
25. Kursun-Cakmak ES, Bayrak S. Comparison of fractal dimension analysis and panoramic-based radiomorphometric indices in the assessment of mandibular bone changes in patients with type 1 and type 2 diabetes mellitus. *Oral surgery, oral medicine, oral pathology and oral radiology*. 2018; 126(2): 184-91.

26. Goller Bulut D, Bayrak S, Uyeturk U, Ankarali H. Mandibular indexes and fractal properties on the panoramic radiographs of the patients using aromatase inhibitors. *The British journal of radiology*. 2018; 20180442.
27. Ma ZG, Yang C, Fang B, Xia YH, Mao LX, Feng YM. Three-D imaging of dental alveolar bone change after fixed orthodontic treatment in patients with periodontitis. *International journal of clinical and experimental medicine*. 2015; 8(2): 2385-91.
28. Ru N, Liu SS, Zhuang L, Li S, Bai Y. In vivo microcomputed tomography evaluation of rat alveolar bone and root resorption during orthodontic tooth movement. *The Angle orthodontist*. 2013; 83(3): 402-9.
29. Zhuang L, Bai Y, Meng X. Three-dimensional morphology of root and alveolar trabecular bone during tooth movement using micro-computed tomography. *The Angle orthodontist*. 2011; 81(3): 420-5.
30. Wang C, Han J, Li Q, Wang L, Fan Y. Simulation of bone remodelling in orthodontic treatment. *Computer methods in biomechanics and biomedical engineering*. 2014; 17(9): 1042-50.
31. Campos MJ, de Albuquerque EG, Pinto BC, Hungaro HM, Gravina MA, Fraga MR, et al. The role of orthodontic tooth movement in bone and root mineral density: a study of patients submitted and not submitted to orthodontic treatment. *Medical science monitor: international medical journal of experimental and clinical research*. 2012; 18(12): Cr752-7.
32. Wilding RJ, Slabbert JC, Kathree H, Owen CP, Crombie K, Delport P. The use of fractal analysis to reveal remodelling in human alveolar bone following the placement of dental implants. *Archives of oral biology*. 1995; 40(1): 61-72.
33. Araujo AS, Fernandes AB, Maciel JV, Netto Jde N, Bolognese AM. New methodology for evaluating osteoclastic activity induced by orthodontic load. *Journal of applied oral science: revista FOB*. 2015; 23(1): 19-25.
34. Lee DH, Ku Y, Rhyu IC, Hong JU, Lee CW, Heo MS, et al. A clinical study of alveolar bone quality using the fractal dimension and the implant stability quotient. *Journal of periodontal & implant science*. 2010; 40(1): 19-24.
35. Rothe LE, Bollen AM, Little RM, Herring SW, Chaison JB, Chen CS, et al. Trabecular and cortical bone as risk factors for orthodontic relapse. *American journal of orthodontics and dentofacial orthopedics: official publication of the American Association of Orthodontists, its constituent societies, and the American Board of Orthodontics*. 2006; 130(4): 476-84.
36. Jung YH. Evaluation of peri-implant bone using fractal analysis. *Korean Journal of Oral and Maxillofacial Radiology*. 2005; 35(3): 121-5.
37. Mu TJ, Lee DW, Park KH, Moon IS. Changes in the fractal dimension of peri-implant trabecular bone after loading: a retrospective study. *Journal of periodontal & implant science*. 2013; 43(5): 209-14.
38. Arsan B, Kose TE, Cene E, Ozcan I. Assessment of the trabecular structure of mandibular condyles in patients with temporomandibular disorders using fractal analysis. *Oral surgery, oral medicine, oral pathology and oral radiology*. 2017; 123(3): 382-91.

Corresponding Author:

Gülbahar USTAOĞLU
Bolu Abant İzzet Baysal University
Faculty of Dentistry
Department of Periodontology
Bolu, Turkey
Phone : +90 544 567 51 66
Fax : +90 374 254 66 00
E-mail : gulbaharustaoglu@hotmail.com