



# Resolution of Left Bundle Branch Block Due To Treatment of COVID-19-Related Myocarditis

Mustafa Yıldız<sup>1</sup>, Banu Şahin Yıldız<sup>2</sup>, Ergün Parmaksız<sup>2</sup>, Serap Yadigar<sup>2</sup>

<sup>1</sup> University of Istanbul, Institute of Cardiology, Department of Cardiology, Istanbul, Turkey

<sup>2</sup> Istanbul Kartal Dr. Lutfi Kırdar Training and Research Hospital, Department of Cardiology, Istanbul, Turkey

## ABSTRACT

We present the case of a 67-year-old woman with novel coronavirus-infected pneumonia, who was subsequently diagnosed with coronavirus disease 2019 (COVID-19)-related myocarditis and left bundle branch block (LBBB). COVID-19-infected pneumonia treatment, such as oseltamivir, azithromycin, ceftriaxone, and ascorbic acid, may be related to the reduction of myocarditis lesion. Reduction in lesions' size may improve the conduction system; therefore, LBBB can also be resolved in the treatment of COVID-19-infected pneumonia.

**Key Words:** Left bundle branch block; COVID-19; myocarditis

## COVID-19 İlişkili Miyokardite Bağlı Geri Dönüşümlü Sol Dal Bloğu

### ÖZET

Burada, COVID-19 ilişkili miyokardit ve geri dönüşümlü sol dal bloğu tanısı konan, yeni koronavirüs enfekte pnömonili 67 yaşında bir kadın hasta sunulmuştur. Oseltamivir, azitromisin, seftriakson ve askorbik asit dahil olmak üzere COVID-19 enfekte pnömoni tedavisi miyokardit lezyonunun azalmasıyla ilişkili olabilir. COVID-19 enfekte pnömonide tedavi ile lezyonların boyutunda gerileme iletim sisteminde, dolayısıyla sol dal bloğunda iyileşmeye neden olabilir.

**Anahtar Kelimeler:** Sol dal bloğu; COVID-19; miyokardit

## INTRODUCTION

Left bundle branch block (LBBB), observed on electrocardiogram, is associated with conduction disturbances and a delayed propagation of electrical impulses in the His-Purkinje system. Some clinical conditions observed in LBBB are coronary artery disease, hypertension, valve disease, cardiomyopathy, congenital heart disease, infective endocarditis, myocarditis along with electrolyte disturbances, such as hyperkalemia. Moreover, drugs, such as hydroxychloroquine, are used for treating LBBB<sup>(1)</sup>. Being responsible for the ongoing worldwide pandemic, coronaviruses are enveloped viruses with a single positive-stranded RNA genome<sup>(2)</sup>. Coronavirus disease 2019 (COVID-19) disease presents with a broad clinical spectrum, varying from asymptomatic infection to severe cardiac and/or pulmonary pathologies, which may be visible on chest computed tomography, further leading to acute myocarditis and/or respiratory distress syndrome<sup>(3)</sup>. The severe cardiac and/or pulmonary pathologies have a higher mortality rate and are associated with older age and comorbid diseases such as hypertension and coronary artery disease. A study has reported that cardiac complications, such as myocarditis and arrhythmia, and COVID-19 can coexist together<sup>(4)</sup>. The purpose of this report is to present the case of a patient with novel coronavirus-infected pneumonia, who was subsequently diagnosed with COVID-19-related myocarditis and intermittent LBBB.

## CASE REPORT

A 67-year-old woman (receiving hemodialysis treatment thrice a week) with a four-day history of fever (38°C), dry cough, and hypoxia (oxygen saturation: 94.1%) was admitted to our hospital. Teleradiography and chest computed tomography scans were compatible with

*Cite this article as: Yıldız M, Şahin Yıldız B, Parmaksız E, Yadigar S. Resolved left bundle branch block due to COVID-19-related myocarditis. Koşuyolu Heart J 2020;23(2):144-7.*

## Correspondence

**Mustafa Yıldız**

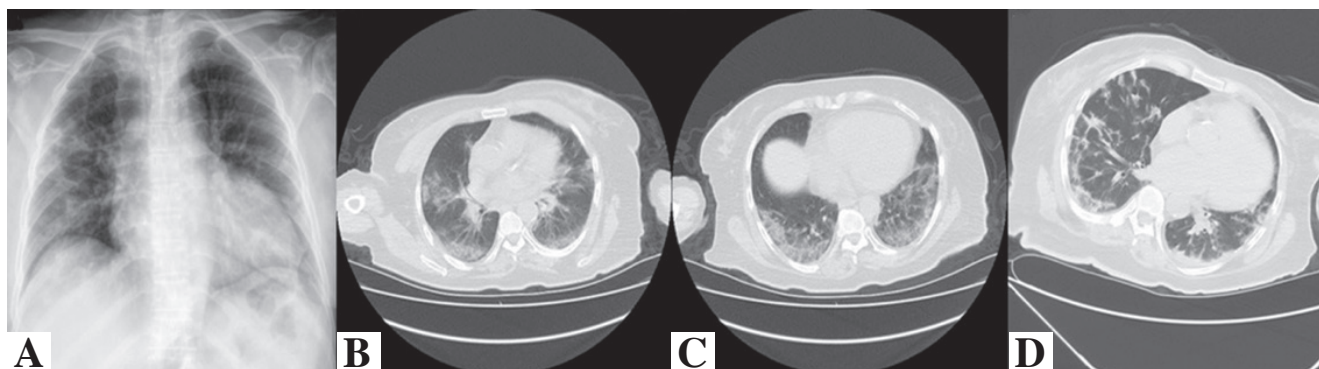
**E-mail:** mustafayildiz@yahoo.com

**Submitted:** 20.07.2020

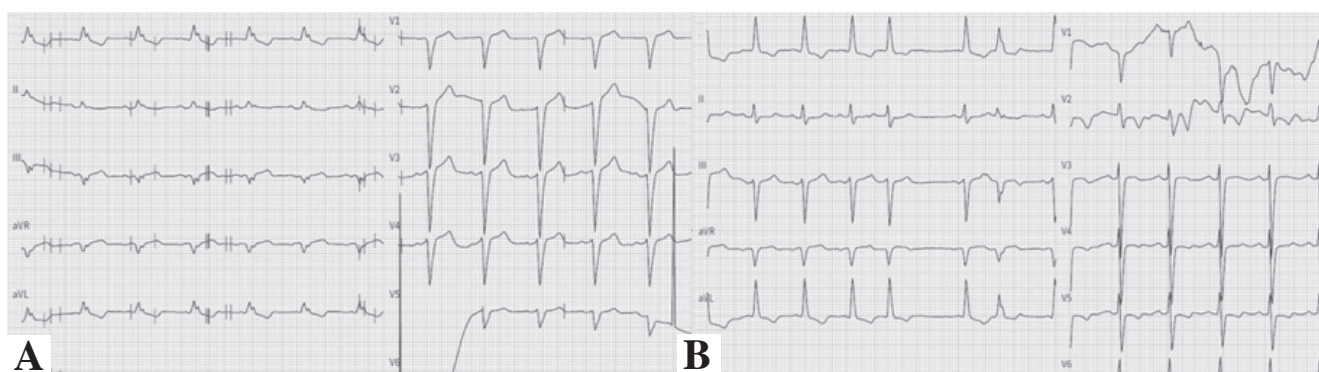
**Accepted:** 20.07.2020

**Available Online Date:** 25.08.2020

© Copyright 2020 by Koşuyolu Heart Journal.  
Available on-line at  
www.kosuyoluheartjournal.com



**Figure 1A-D.** A-C. Teleradiography and chest computed tomography findings were compatible with COVID-19-related pneumonia and showed bilateral ground glass opacification with consolidation in the lungs. D. Improved consolidations after treatment.



**Figure 2A,B.** A. Electrocardiography showed LBBB with sinus rhythm. B. Electrocardiography showed sinus rhythm without LBBB and premature atrial contraction.

COVID-19-related pneumonia and showed bilateral ground glass opacification with consolidation in the lungs (Figure 1A-C). Her electrocardiogram scans showed LBBB with the sinus rhythm (Figure 2A). She was started on the treatment with azithromycin (500 mg/day), hydroxychloroquine (2 x 400 mg loading dose, 200 mg/day for maintenance), oseltamivir (2 x 75 mg/day), ceftriaxone (2 x 1000 mg/day), and ascorbic acid (15 g/day). In fact, these dosages were revised at the glomerular filtration rate. Five days later, there was a considerable improvement in the conduction disturbances, namely LBBB. Her post-treatment electrocardiogram scans showed sinus rhythm without LBBB and premature atrial contraction (Figure 2B). Improvements were also observed in the computerized tomography findings (Figure 1D), troponin and inflammatory markers such as C-reactive protein, lymphocytes, lymphocyte/neutrophil, and procalcitonin. She was discharged from the hospital without any disturbances. Table 1 shows the pre- and post-treatment laboratory values of the patient with novel coronavirus-infected pneumonia, who was subsequently diagnosed with COVID-19-related myocarditis and intermittent LBBB.

## DISCUSSION

Intermittent LBBB may cause the manifestation of different conditions such as bradycardia, tachycardia, acute coronary

syndrome, acute pulmonary embolism, chest trauma, cardiac interventional procedures, and myocarditis. It can be symptomatic and may be associated with left ventricular systolic and/or diastolic dysfunction. The underlying mechanisms of an intermittent blockade are unclear; however, it appears to result from anatomical or physiological disturbances in the conduction system. LMMB was also associated with myocarditis that is related with viruses, especially Coxsackie B and echo viruses, which are highly cardiotoxic for the human myocardium<sup>(5)</sup>. Also, in today's era of COVID-19, the etiology and pathogenesis of pneumonia and myocarditis should be considered in the diagnosis of COVID-19<sup>(3)</sup>. Fever, dry cough, fatigue, shortness of breath, and atypical chest pain are the most common symptoms in the patients with COVID-19. Cardiac complications including myocarditis and electrocardiographic changes such as atrioventricular block and intermittent LBBB can co-exist with COVID-19 as previously reported in a study<sup>(3,6)</sup>. The main mechanisms responsible for myocarditis have been considered to include the direct viral invasion of myocardium and immune-mediated myocardial injury<sup>(5)</sup>. Troponin and inflammatory markers including C-reactive protein, lymphocyte, lymphocyte/neutrophil and procalcitonin can be elevated in pneumonia and rarely in COVID-19-related myocarditis as in our case. Chest computed tomography, cardiac magnetic

**Table 1. Pre- and post-treatment laboratory values of the patient with left bundle branch block and COVID-19**

Parameters	Pre-treatment	Post-treatment
Glucose (mg/dL)	153	109
Urea (mg/dL)	109	44
Creatinine (mg/dL)	6.01	6.62
Calcium (mg/dL)	8.27	8.59
Sodium (mmol/L)	139	140
Potassium (mmol/L)	4.77	4.92
<b>Troponin T hs (<math>\mu\text{g/L}</math>)</b>	<b>0.133</b>	<b>0.087</b>
<b>Procalcitonin (<math>\mu\text{g/L}</math>)</b>	<b>0.490</b>	<b>0.222</b>
<b>C reactive protein (CRP) (mg/L)</b>	<b>154</b>	<b>3</b>
D-dimer ( $\mu\text{g/L}$ )	1210	1130
Ferritin ( $\mu\text{g/L}$ )	237.30	182.80
Fibrinogen (mg/dL)	794 (200-400)	
Thyroid stimulating hormone (mIU/L)	1.06 (0.34-5.60)	
Leucocytes ( $10^3/\mu\text{L}$ )	8500	12.100
<b>Lymphocyte (<math>10^3/\text{mm}^3</math>)</b>	<b>1500</b>	<b>1000</b>
Neutrophil ( $10^3/\mu\text{L}$ )	6100	7000
<b>Lymphocyte/Neutrophil</b>	<b>0.24</b>	<b>0.14</b>
Platelets ( $10^3/\mu\text{L}$ )	296.000	374.000
Hemoglobin (g/dL)	8.5	9.8
Hematocrit (%)	25	29

resonance imaging, and echocardiography are helpful tools for differentiating and describing the heart damage. The common mechanisms underlying the COVID-19-related respiratory distress syndrome and myocarditis may be associated with massive release of cytokines<sup>(7)</sup>. Increased several pro-inflammatory cytokines such as interleukin-6, interleukin-1, and tumor necrosis factor alpha have been demonstrated in the respiratory distress syndrome<sup>(8)</sup>. Antiviral therapy and ascorbic acid may reduce systemic inflammation and immune activation<sup>(9,10)</sup>. Therefore, the treatment of COVID-19-infected pneumonia including oseltamivir, azithromycin, ceftriaxone, and ascorbic acid may be related to the decrease in the myocarditis lesion. Treatment methods such as immunosuppression and antiviral drugs can improve histologic findings and left ventricle function<sup>(10)</sup>. Reduction in lesions' size may improve the conduction system; therefore, LBBB can be resolved in the treatment of COVID-19-infected pneumonia.

#### ACKNOWLEDGEMENT

We would like to thank Yakup Ergul, Assoc Prof for support.

**Informed Consent:** Written informed consent was obtained from the patient who participated in this study.

**Peer-review:** Externally peer-reviewed.

**Author Contributions:** Concept/Design - MY; Analysis/Interpretation - BY, EP, SY; Writing - MY; Critical Revision - MY, BY; Final Approval - MY.

**Conflict of Interest:** The authors have no conflict of interest to declare.

**Financial Disclosure:** The authors declared that this study has received no financial support.

#### REFERENCES

1. Silva AMOCD, Silva EAGLD. Intermittent left bundle branch block reversal to normal conduction during general anesthesia. *Rev Bras Anestesiol* 2017;67:430-4.
2. Denison MR, Graham RL, Donaldson EF, Eckerle LD, Baric RS. Coronaviruses: an RNA proofreading machine regulates replication fidelity and diversity. *RNA Biol* 2011;8:270-9.
3. Cizgici AY, Zencirkiran Agus H, Yildiz M. COVID-19 myopericarditis: It should be kept in mind in today's conditions. *Am J Emerg Med* 2020;S0735-6757(20)30310-7.
4. Jia-Hui Z, Ying-Xia L, Jing Y, Fu-Xiang W, Wei-Bo W, Jin-Xiu L. First case of COVID-19 complicated with fulminant myocarditis: a case report and insights. *Infection* 2020 Apr 10.

5. Burch GE, Giles TD. The role of viruses in the production of heart disease. *Am J Cardiol* 1972;29:231-40.
6. Nakashima H, Honda Y, Katayama T. Serial electrocardiographic findings in acute myocarditis. *Intern Med* 1994;33:659-66.
7. Tian S, Hu W, Niu L, Liu H, Xu H, Xiao SY. Pulmonary pathology of early-phase 2019 Novel Coronavirus (COVID-19) pneumonia in two patients with lung cancer. *J Thorac Oncol* 2020;15:700-4.
8. Conti P, Ronconi G, Caraffa A, Gallenga CE, Ross R, Frydas I, et al. Induction of pro-inflammatory cytokines (IL-1 and IL-6) and lung inflammation by Coronavirus-19 (COVI-19 or SARS-CoV-2): anti-inflammatory strategies. *J Biol Regul Homeost Agents* 2020 Mar 14;34.
9. Ellulu MS, Rahmat A, Patimah I, Khaza'ai H, Abed Y. Effect of vitamin C on inflammation and metabolic markers in hypertensive and/or diabetic obese adult: a randomized controlled trial. *Drug Des Devel Ther* 2015;9:3405-12.
10. Jones SR, Herskowitz A, Hutchins GM, Baughman KL. Effects of immunosuppressive therapy in biopsy-proved myocarditis and borderline myocarditis on left ventricular function. *Am J Cardiol* 1991;68:370-6.