

# Saphenous vein graft aneurysm after coronary artery bypass graft surgery: A case report

## Koroner bypass cerrahisi sonrası gelişen safen ven anevrizması: Olgu sunumu

Hasan Reyhanoglu<sup>1</sup>, Kaan Özcan<sup>1</sup>, Efe Edem<sup>2</sup>

<sup>1</sup> Department of Cardiovascular Surgery,  
University Hospital of Tinaztepe, İzmir,  
Turkey

<sup>2</sup> Department of Cardiology, University  
Hospital of Tinaztepe, İzmir, Turkey

ORCID ID of the author(s)

HR: 0000-0002-2872-3361

KÖ: 0000-0002-4967-8045

EE: 0000-0002-5042-4077

### Abstract

Aneurysm of the saphenous vein, which is the most used graft in coronary bypass surgery, is a rare complication. While saphenous vein dilatation forming in the early or late stages after bypass surgery can be symptomatic, it can also be diagnosed incidentally. Aneurysms forming in the late stages are atherosclerotic while those forming in the initial stages are mostly connected to venous damage. In the present case, a saphenous aneurysm with atherosclerotic causes was detected in a patient 20 years after coronary bypass surgery. The patient was admitted with chest pain, syncope, and dizziness complaints. Examination revealed a saphenous vein aneurysm measuring 28x30 mm. The patient underwent surgery, and the aneurysm was resected.

**Keywords:** Saphenous vein, Aneurysm, Coronary artery bypass

### Öz

Koroner bypass cerrahisinde en sık kullanılan greft olan safen veninin anevrizmaları nadir rastlanan bir komplikasyondur. Erken veya geç dönemde oluşan safen ven dilatasyonları semptomatik olabildikleri gibi bazen tesadüfen de teşhis edilebilir. Geç dönemde oluşan anevrizmalar genellikle aterosklerotik nedenli iken erken dönemde oluşan anevrizmalar sıklıkla ven hasarına bağlı olmaktadır. Bu olguda koroner bypass cerrahisi yapılan hastada 20 yıl sonra aterosklerotik nedenli safen ven anevrizması saptandı. Göğüs ağrısı, baygınlık, baş dönmesi şikayeti ile başvuran hastanın yapılan tetkiklerinde 28x30 mm boyutlarında safen ven anevrizması tespit edildi. Hasta operasyona alındı ve anevrizma rezeksiyonu yapıldı.

**Anahtar kelimeler:** Safen ven, Anevrizma, Koroner arter bypass

## Introduction

The saphenous vein is the most used autogenous graft in coronary bypass and peripheral artery surgeries. If this graft, usually carrying the blood of the venous system, is arterialized, and exposed to higher pressure, it may lead to saphenous vein dilatation and rarely, aneurysm [1-9]. Aneurysm of a saphenous vein graft was first reported by Carrasquilla in patients whose carotid arteries were fixed with veins [2]. Saphenous vein aneurysm developing after coronary bypass was first reported by Riahi in 1975 [3,6,9,10].

We herein report an aneurysm that developed in the saphenous vein 20 years after coronary bypass surgery.

Corresponding author / Sorumlu yazar:

Hasan Reyhanoglu

Address / Adres: Tinaztepe Üniversite Hastanesi,  
Kalp ve Damar Cerrahisi Kliniği, Ahmet Piriştina  
Bulvarı, No: 51, Tinaztepe, Buca, İzmir, Türkiye  
E-mail: hreyhanoglu@hotmail.com

Informed Consent: The authors stated that the written consent was obtained from the patient presented with images in the study.

Hasta Onamı: Yazarlar çalışmada görüntüleri ile sunulan hastadan yazılı onam alındığını ifade etmiştir.

Conflict of Interest: No conflict of interest was declared by the authors.

Çıkar Çatışması: Yazarlar çıkar çatışması bildirmemişlerdir.

Financial Disclosure: The authors declared that this study has received no financial support.

Finansal Destek: Yazarlar bu çalışma için finansal destek almadıklarını beyan etmişlerdir.

Published: 11/19/2020

Yayın Tarihi: 19.11.2020

Copyright © 2020 The Author(s)

Published by JOSAM

This is an open access article distributed under the terms of the Creative Commons Attribution-Non Commercial-NoDerivatives License 4.0 (CC BY-NC-ND 4.0) where it is permissible to download, share, remix, transform, and build upon the work provided it is properly cited. The work cannot be used commercially without permission from the journal.



## Case presentation

A 68-year-old patient who had undergone coronary bypass surgery 20 years ago presented with complaints of chest pain, syncope, and dizziness. An X-ray showed a paracardiac mass, pushing the right hemithorax. A thoracic computed tomography performed after confirmation of the diagnosis showed an aneurysm, defined as a 'saccular aneurysmal vascular structure,' adjoining the right atrium (Figure 1).

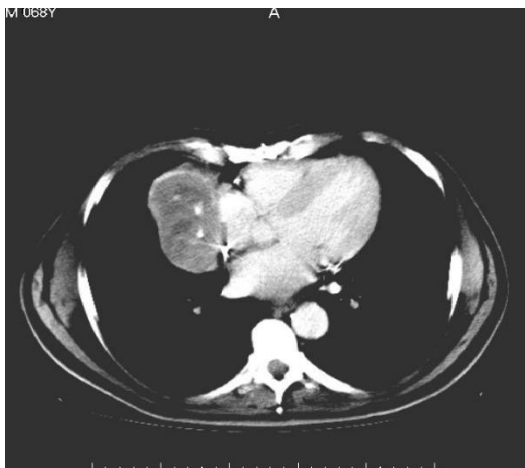


Figure 1: A computed tomography image of the thorax showing the saccular aneurysmal vascular structure

Coronary angiography revealed a saphenous aneurysm measuring 28 × 30 mm in the right saphenous graft (aorta–right coronary artery) (Figure 2).

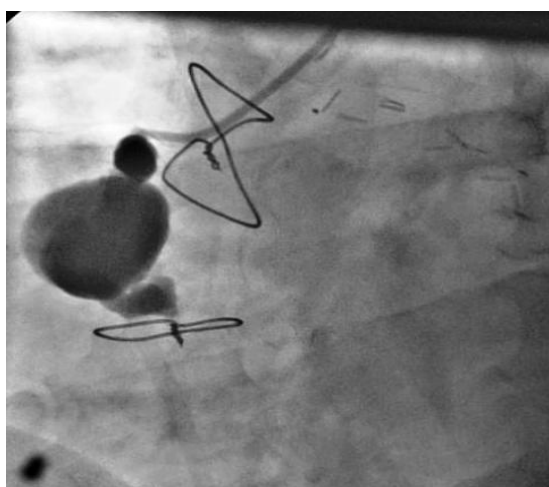


Figure 2: A coronary angiographic image of the saphenous aneurysm.

A right anterolateral thoracotomy was performed. An aneurysm measuring 28 × 30 mm in size was observed adjoining the right atrium and exerting pressure. The sac was incised to show thrombotic and calcified contents (Figure 3). After resecting the aneurysm wall, the right saphenous vein was tied proximally. The distal part of the right coronary artery was explored for bypass; however, there was too much fibrosis and the lumen was not appropriate for grafting. The operation was performed on a beating heart, and cardiopulmonary bypass was not performed. The patient was discharged on the 6<sup>th</sup> postoperative day uneventfully.

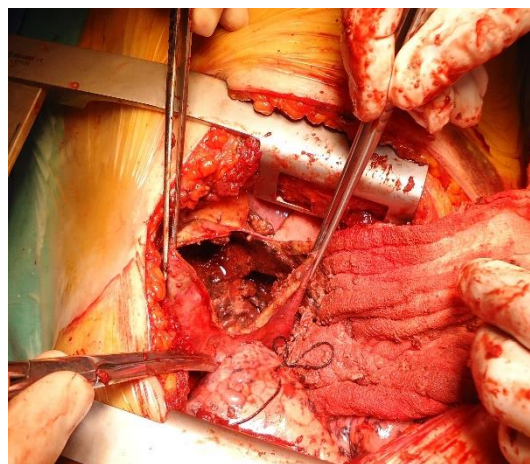


Figure 3: A surgical specimen of the aneurysm sac

## Discussion

Saphenous vein aneurysm developing after coronary bypass surgery is a rarely seen complication [1-3,5-7,9]. Aneurysms developing between 11 days and 21 years and varying in diameter from 1 to 13 cm have been reported [6,10]. In their study on 168 saphenous vein aneurysms, Ramirez et al. [9] reported that 4.2% of the cases were diagnosed within 1 year, 6.1% of the cases within 1–5 years, 21.2%, within 5–10 years, and 68.5%, after 10 years. According to the sizes and localizations of saphenous vein aneurysms, physicians may encounter cardiac symptoms or mediastinal mass pressure [1,9]. Nevertheless, one third of the cases are diagnosed incidentally [9]. These patients may have chest pain related to myocardial ischemia, cardiac failure findings due to compression arrhythmia, hemoptysis, bleeding, hemothorax after sudden rupture, and superior vena cava syndrome [6,7,9-11].

Although the mechanisms underlying aneurysm development are not exactly known, graft necrosis, hypertension, vein damage during graft preparation, atherosclerosis developing on the graft, and weakness in the vein wall are suggested reasons [1,5-7]. Aneurysm is more frequent in right coronary artery grafts and less frequent in left anterior descending and circumflex artery grafts [9]. One of the hypotheses suggested for the more frequent occurrence of aneurysm in the right coronary artery graft is that the saphenous vein is more commonly used in this coronary artery [9]. Another suggested hypothesis is the preference for wider parts of the saphenous vein as there is no diameter disproportion in the right coronary artery.

Aneurysms are classified as early or late stage according to their time of development [9]. Early stage (<12 months) aneurysms are caused by vein damage or weakness of the wall, whereas late-stage aneurysms are caused by atherosclerosis [1,3-7,9,10,12]. Early-stage aneurysms are related to the structure of a pseudoaneurysm, usually saccular, and commonly develop in the first couple months after surgery [6,8-10]. These aneurysms are caused by weakness of the saphenous vein wall, damage during vein removal, or defects in the anastomosis line [7-10,12]. Venous valves extending up to the media layer on the vein wall are weaker, and the smooth muscle layer in this area is longitudinal, not circular. This causes the development of a weak area that may lead to an aneurysm [1,6]. Late-stage aneurysms mostly show the true aneurysm structure [7,8,10,12]. True

aneurysms are fusiform; they are caused by atherosclerosis and contain 3 vascular layers, e.g., vascular aneurysms [7-10,12]. Inside the sac of this type of aneurysm, commonly developed over 8–10 years, thrombosis secondary to atherosclerosis develops and causes graft occlusion [1,6,9]. The aneurysm in the present case was this type of aneurysm with atherosclerotic characteristics.

Saphenous aneurysms can be diagnosed using echocardiography, direct X-ray lung radiography, computed tomography, magnetic resonance scanning, and coronary angiography [1,6,7,10-12]. Computed tomography and magnetic resonance scanning are especially important for determining the pressure exerted on neighboring areas and differential diagnosis [6,8]. Coronary angiography is important to decide whether additional revascularization other than aneurysm resection is necessary [8,12].

In surgical treatment, ligation, aneurysm resection and if necessary, coronary revascularization are performed [6,8,10,11]. Other treatment choices include percutaneous coil embolization and embolization with covered stents [6,7,9-12]. The first percutaneous attempt in this category was reported by Kim et al. in 1983 [13]. Percutaneous embolization may be preferred to prevent the risks of re-sternotomy, especially in patients for whom additional revascularization will not be performed, or in patients with a high surgical risk [6,7,9]. In the present case, we did not try percutaneous closure because of the large size of the aneurysm sac and the possibility of revascularization to the right coronary artery.

### Conclusions

In patients with mediastinal or paracardiac mass after coronary bypass surgery, saphenous aneurysm should not be overlooked during diagnosis. These cases may be associated with cardiac symptoms; occasionally, they can be asymptomatic and diagnosed incidentally. In these patients, the planned surgical treatment will prevent risks, such as sudden rupture, coronary embolism, and cardiac failure.

### References

1. Yavuz S, Celkan A, Turk T, Ozdemir IA. Aneurysm of an aortocoronary saphenous vein bypass graft. *Turkish Journal of Thoracic and Cardiovascular Surgery*. 1999;7:336-8.
2. Carrasquilla C, Weaver AW. Aneurysm of a saphenous vein graft to the common carotid artery. *Vasc Surg*. 1972;6:66-8.
3. Riahi M, Vasu CM, Tomatis LA, Schlosser RJ, Zimmerman G. Aneurysm of saphenous vein bypass graft to coronary artery. *J Thorac Cardiovasc Surg*. 1975;70:358-9.
4. Neitzel GF, Barboriak JJ, Pintar K, Qureshi I. Atherosclerosis in aortocoronary bypass grafts. Morphologic study and risk factor analysis 6 to 12 years after surgery. *Arteriosclerosis*. 1986;6:594-600.
5. Van de Wal RMA, Van Verkum JW, Le cocq d'armandville MC, Plokker HWT, Morshuis WJ. Giant aneurysm of an aortocoronary venous bypass graft compressing the right ventricle. *Neth Heart J*. 2007;15:252-4.
6. Abbasi M, Soltani G, Shomali A, Javan H. A large saphenous vein graft aneurysm one year after coronary artery bypass graft surgery presenting as a left lung mass. *Interactive Cardio Vascular and Thoracic Surgery*. 2009;8:691-3.
7. Pulling TM, Uyesugi WY. Aneurysm of an autologous aorta to right coronary artery reverse saphenous vein graft presenting as a mediastinal mass: a case report. *Cases Journal*. 2008;1:340.
8. Kalimi R, Palazzo RS, Graver LM. Giant aneurysm of saphenous vein graft to coronary artery compressing the right atrium. *Ann Thorac Surg*. 1999;68:1433-7.
9. Ramirez FD, Hibbert B, Simard T, Pourjabbar A, Wilson KR, et al. Natural history and management of aortocoronary saphenous vein graft aneurysms: a systematic review of published cases. *Circulation* 2012;126:2248-56
10. Breton LH, Pavin D, Langanay T, Roland Y, Leclercq C, Beliard JM, et al. Aneurysms and pseudoaneurysms of saphenous vein coronary artery bypass grafts. *Heart* 1998;79:505-8.
11. Boczar KE, Hibbert B, Simard T, Hibbert R, Chan V, O'Brien ER. Giant saphenous vein graft aneurysm presenting as ST-elevation myocardial infarction. *Circ J*. 2014;78:769-71.
12. Nölke L, McGovern E, Wood EA. Saphenous vein graft aneurysms; the true, false and ugly! *Interact Cardiovasc Thorac Surg*. 2004;3:631-3.
13. Kim D, Guthaner DF, Wexler L. Transcatheter embolization of a leaking pseudoaneurysm of saphenous vein aortocoronary bypass graft. *Cathet Cardiovasc Diagn*. 1983;9:591-4.

This paper has been checked for language accuracy by JOSAM editors.

The National Library of Medicine (NLM) citation style guide has been used in this paper.