



Anisakis simplex (Rudolphi, 1809), *Hysterothylacium aduncum* (Rudolphi, 1802) and *Pseodoterranova decipiens* (Krabbe 1878) (Nematoda; Anisakidae) parasites in some commercial fish species from Edremit Bay (Northern Aegean Sea)

Kübra KURAN¹, Hatice TORCU KOÇ^{2*}, Zeliha ERDOĞAN², Mehmet Cemal OĞUZ³

¹Adnan Menderes Üniversitesi, Veteriner Fakültesi, Veteriner Fizyolojisi Anabilim Dalı, Aydın/Turkey

²Balikesir University, Faculty of Science and Arts, Department of Biology, Balikesir/Turkey

³Mardin Artuklu Üniversitesi, Artuklu Yerleşkesi, Mardin/Turkey

This is a part of MSc. thesis named "Research on nematodes of Bogue (*Boops boops*, Linnaeus, 1758) and Sardine (*Sardina pilchardus*, Walbaum, 1792) caught from ayvalık coast, the northern aegean sea"

*E-mail: htorcukoc@hotmail.com

Article Info

Received:

09/10/2020

Accepted:

24/06/2021

Keywords:

- *Anisakis simplex*
- *Hysterothylacium aduncum*
- *Pseodoterranova decipiens*
- *Boops boops*
- *Sardina pilchardus*
- Edremit Bay
- Morphology

Abstract

A total of 120 boggles and 180 sardines were obtained from commercial fishermen in coast of Ayvalık, Edremit Bay fishing ground between September 2014 and 2015 and their intestines were examined parasitologically. It was observed that 74 of 300 fish were infected with endoparasites. A total of 130 nematodes were detected from the intestines of fishes. Here, some morphological characters of Anisakid parasites (*Anisakis simplex*, *Hysterothylacium aduncum* and *Pseodoterranova decipiens*) are given. *A. simplex*, *H. aduncum*, and *P. decipiens* as nematod parasites represent a public health risk in consumption of raw or inadequately cooked fishery products. Besides, this paper presents the first record of *P. decipiens* in *Boops boops* in Turkish Seas.

Kuzey Ege Denizi, Edremit Körfezi'nden Bazı Ticari Balıklardaki *Anisakis simplex* (Rudolphi, 1809), *Hysterothylacium aduncum*, (Rudolphi, 1802) ve *Pseodoterranova decipiens* (Krabbe 1878) (Nematoda; Anisakidae) Parazitleri

Makale Bilgisi

Alınış Tarihi:

09/10/2020

Kabul Tarihi:

24/06/2021

Anahtar Kelimeler:

- *Anisakis simplex*
- *Hysterothylacium aduncum*
- *Pseodoterranova decipiens*
- *Boops boops*
- *Sardina pilchardus*
- Edremit Körfezi
- Morfoloji

Öz

Eylül 2014 ile Şubat 2015 tarihleri arasında Edremit Körfezi Ayvalık kıyısından toplam 120 kupes ve 180 sardalya ticari balıkçılardan temin edildi ve bağırsakları parazitolojik olarak incelendi. 300 balıktan, 74'ünün parazitlerle enfekte olduğu gözlemlendi. Balıkların bağırsaklarından toplam 130 nematod gözlemlendi. Burada, Anisakid parazitlerin (*Anisakis simplex*, *Hysterothylacium aduncum* and *Pseodoterranova decipiens*) morfolojik karakterleri verilir. Nematod parazitler olarak *A. simplex*, *H. aduncum*, and *P. decipiens* çiğ veya yetersiz pişirilmiş balık ürünlerinin tüketiminde halk sağlığı riski oluştururlar. Ayrıca bu çalışma *P. decipiens*'in Türkiye Deniz'lerinden *Boops boops*'taki ilk kaydını verir.

INTRODUCTION

Fish provides a good source of high quality protein, many vital vitamins, and minerals. Recently, there is a high tendency among people to consume fish due to its health benefits such as omega 3 fatty acids (Berland, 1989; Adams et al., 1997). However, this highly important food source can carry a wide variety of pathogens such as Anisakids which cause a great concern to human health when it is consumed raw (European Food Safety Authority, 2010). Furthermore, parasite infection of fish annually impose considerable economical losses and damages to fish farming industry worldwide (Rahimi et al., 2013). Anisakids are responsible for emergent zoonoses called Anisakiasis consumers (Myers, 1976; Plessis et al., 2004). Humans become an accidental host of Anisakid larvae usually as a result of consuming infected raw fish or imperfectly cooked fish (Ivanovic et al., 2017) and are exposed to some abdominal syndromes such as abdominal pain, vomiting, diarrhea and mild fever and also serious allergic reactions such as urticaria, anaphylaxis (Myers, 1976; Audicana et al., 2003; Plessis et al., 2004).

The nematodes of Anisakidae were probably first recognized in fish host as early as the 13th century in marine mammals in the early 1700's, as a more common human infection from North America in the 1970's (Ballard et al., 2005). As marine cosmopolitan parasites, Anisakids are usually found in high amount in the third larval stage on the gut cavity in hosts at various trophic levels of the food chain (Lybmery and Cheah 2007). In their life cycle, there are small crustaceans as an intermediate host, fish and cephalopods as paratenic hosts, and marine mammals as final hosts (Mattiucci et al., 2008). *A. simplex* was determined encysted in stomach wall from the Galway Bay with no information on pathology of this nematode (Henderson and Dunne, 1998). Kijewska et al. (2009) determined this parasite from some fishes such as *Scomber japonicus*, *Sardina pilchardus* from African Shelf. *H. aduncum* is also a common parasite not only of marine fish but also of brackish fish (Fagerholm, 1982). This parasite was found in viscera and intestine of various marine fishes in the Atlantic and Pacific Oceans, respectively (Gaevskaaya and Rodjuk, 1988; Williams and Bunkley-Williams, 1996; Alvarez et al., 2002; Shih and Jeng, 2002; Klimpel and Palm, 2011).

Rello et al. (2008) found only one specimen of *H. aduncum* from Spain. Danyer et al. (2010) reported *H. aduncum* and Anisakis spp. in the stomach contents of harbor porpoises (*Phocoena phocoena*) on the western coast of the Turkish Black Sea. The anisakid nematoda genus, *Pseudoterranova mozgovoi*, 1951 is one of the most important of parasites of fish from north Atlantic (Palm et al., 1999). In the north Atlantic, L3 larvae of *P. decipiens* have been detected in more than 60 different fish species, including cod, haddock, halibut, and sculpin (Jensen and Andersen, 1992), The L3 and L4 larvae and adults are parasitic in invertebrates and some birds, (Marcogliese, 2001; Dzido et al., 2009), and especially, in dolphins, seals (Aspholm et al. 1995) and humans (Mercado et al., 1997; Aznar et al. 2006) while the larvae (L3) known as sealworm or codworm, live mainly in benthic fish species (*Gadus morhua*, *Myoxocephalus scorpius*) as third intermediate hosts (Bristow and Midtgaard et al., 2003; Buchmann and Kania, 2012; Mehrdana et al., 2014; Lunneryd et al., 2015). McClelland et al. (1987) and Andersen (2001) determined *P. decipiens* in *Hippoglossoides platessoides* and *Myoxocephalus scorpius* from Canadian and Norwegian coasts. *P. decipiens* was found at water depths ranging between 80 and 820 m in all examined fish species from the South Shetland Islands. McClelland et al. (1990) determined *P. decipiens* in various fish species. *P. decipiens* demonstrates a low degree of host specificity and a wide pattern of distribution in Antarctic waters (Palm et al., 1999). This species has been recently reported in *Halichoerus grypus*, *Gadus morhua* ve *Myoxocephalus scorpius* from the Baltic Sea (Buchman and Kania, 2012; Lunneryd et al., 2015). *P. decipiens* (Nematoda, Anisakidae) was also recorded in Red spot emperor *Lethrinus lentjan* in the Red Sea (Al-Quraishy et al., 2019).

The bogue, *B. boops* and the sardine *S. pilchardus* are found off the coasts of Europe, Africa, the Azores and the Canary Islands, from Norway to Angola, and in the Mediterranean and Black Seas (Whitehead et al., 1986). Both of them are accepted as the Least Concern (Lc) in Red List of Threatened Species by IUCN (Pollard et al., 2014; Tous et al., 2015).

These nematode species had been previously reported from different fish species in Turkish waters; in Aegean and Marmara coasts of Turkey, *A. simplex* was recorded in *Scomber japonicus* from Saros Bay (Akmirza, 1997); in *Trachurus mediterraneus* (Akmirza, 1998a); in *Mullus surmuletus* (Akmirza, 2000a); in *Diplodus annularis*, *Pagellus erythrinus*, *Oblada melanura*, and *B. boops* (Akmirza, 2001b); in *S. pilchardus*, *Merlangius merlangius*, and *Trachurus trachurus* (Oğuz et al., 2000). *H. aduncum* was also reported in *Pomatomus saltatrix* from Eskişehir (Yetim, 1985); *M. merlangius* from Black Sea (Doğanay, 1994; İsmen and Bingel, 1999); in *Merluccius merluccius*, *Gobius niger* and *T. trachurus* from Marmara Sea and Erzurum (Oğuz, 1995; Keser et al., 2007; Özkan et al., 2010); in *T. mediterraneus* and *E. encrasicholus* from Turkish coasts (Öktener, 2005); in *Diplodus vulgaris* and *Sparus aurata* from northeast (Kalay et al., 2009), Mediterranean Sea; in *Sardinella aurata*, *Scomber japonicus*, *T. trachurus* from Dardanelles (Şahin and Sağlam, 2016); in *Merlangius merlangus exinus* from The Turkish Black Sea (Pekmezci, 2019); in *Scomber scombrus* and *Scyliorhinus canicula* in the Sea of Marmara (Keser et al., 2007; Beceriklisoy et al., 2020; Torcu Koç and Erdoğan, 2021). *Pseudoterranova* spp. was determined in the stomach of harbour porpoises (*Phocoena phocoena*) and striped dolphin, *Stenella coeruleoalba* in the eastern Mediterranean by Danyer et al. (2010) and Aytemiz et al. (2012).

In this study, it was conducted to determine the morphological characters of Anisakids infecting *B. boops* and *S. pilchardus* obtained from Edremit Bay. In addition, our findings are important in the base of first record of *P. decipiens* in *Boops boops* in Turkish Seas.

MATERIALS AND METHODS

The studying area

Edremit Bay in the northern Aegean Sea (26°57'-26°34'E and 39°17'-39°34' N) is a place where two currents meet and it is rich in plankton because of upwelling. In addition, the area is fed by waters rich in nutrient from erosion through the vicinity of the Bay and the Black Sea, with a variety of fish fauna (Toğulga, 1997).

Sample collection and analyses

A total of 120 bogues and 180 sardines which were obtained, were transported immediately in an ice box to the Hydrobiology Laboratory of Biology Department of Faculty of Science and Arts, Balıkesir University. Fish species were identified according to (Whitehead et al., 1984-87; Nelson, 1994). Then, a total of 300 fishes were dissected. It was seen that the intestines of a total of 39 bogues and 35 sardines were infected by 130 Anisakid parasites. The specimens of *A. simplex*, *H. aduncum*, and *P. decipiens* were removed from the intestines of fish samples. All the collected parasites were preserved in 70% ethanol and glycerin for further identification (Marcogliese, 2001). Then, the slides were prepared by closing with glycerin-gelatin according to Kruse and Pritchard (1982). The identification of parasites was based on their morphological and morphometric characteristics according to the keys and descriptions found in the scientific literature (Pritchard and Kruse, 1982; Berland, 1989; Murata et al., 2011) and then, their photographs were taken under a stereomicroscope at x12 and x50 magnifications.

The parasitic nematod specimens were deposited in the Hydrobiology collection of the Department of Biology, University of Balıkesir.

RESULTS AND DISCUSSION

The morphology and anatomy of the *A. simplex*, *H. aduncum*, and *P. decipiens* are described in details by Berland (1989). It was seen that some larvae were free in the body cavity, but most of them were encapsulated in intestines of the examined fishes.

Phylum: Nematoda

Class: Secernentea

Ordo: Ascaridida

Fam: Anisakidae

Anisakis simplex (Rudolphi, 1809)

Host fish species: *Boops boops*, *Sardina pilchardus*

Site of infection: intestine

Locality: Ayvalık, Edremit Bay, northern Aegean Sea

A total of examined fish numbers: 300

Number of boques with parasite: 39

Number of sardines with parasite: 35

A total of parasite: 35

Life cycle of *A. simplex*

This nematod has the adult stage in the stomach of cetaceans where copulation and oviposition take place Eggs pass with feces to the marine environment where eggs hatch and liberate the third stage larvae (Højgaard, 1998). A range of invertebrates may act as the first intermediate host but euphausiaceans and copepods are particularly important (Køie et al., 1995). Fishes face to parasites by ingesting infected invertebrates or smaller infected fish.

Diagnostic Characters

To the naked eye, larvae of *A. simplex* are pinkish-white and cylindrical in form. According to Berland (1989), larval morphological features including the absence of a ventricular appendage and an intestinal caecum are useful for the distinction between several anisakid genera. Similarly, the identification of *A. simplex* L3 larvae were based on the presence of a long ventriculus with an oblique ventricular-intestinal junction, without a ventricular appendage and intestinal caecum and the tip of the tail bears a small spine or mucron (Berland, 1989; Yardımcı et al., 2014) (Figure 1A, 1B). Morphological features were measured (Table 1) and seen to be similar to the relevant literature (Table 2).

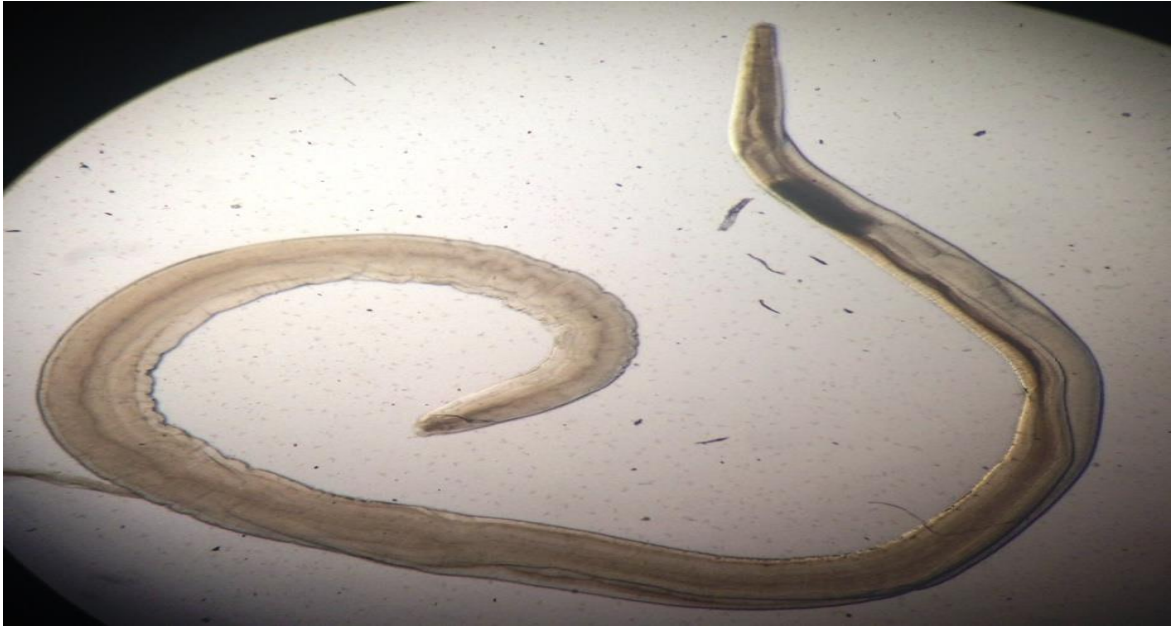

Figure 1A. *Anisakis simplex* (♂) (Original photo)

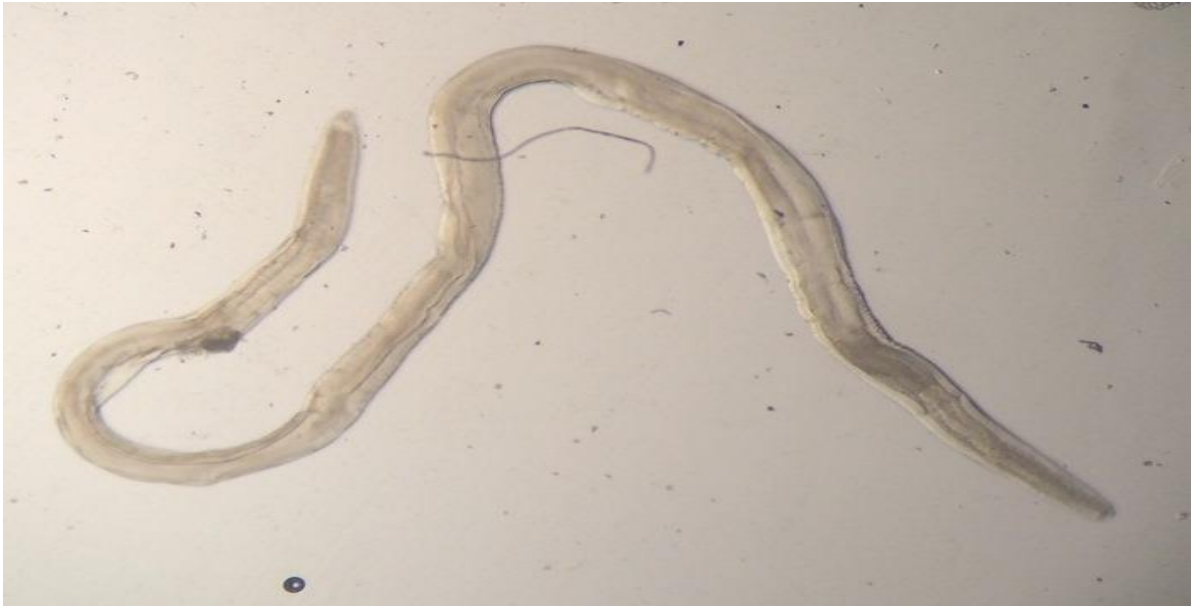

Figure 1B. *Anisakis simplex* (♀) (Original photo)

Table 1. Some measurements (μm) of some morphological characters in third-stage larvae of *Anisakis simplex*.

<i>Anisakis simplex</i>	Min.-Max.
Total Length	(12789-28481) 21244 \pm 4978
Body width	(751-1299) 1046 \pm 225
Oesophagus length	(2091-3167) 2790 \pm 407
Ventriculus Length	(934-1908) 1577 \pm 321
Tail Length	(162-223) 181 \pm 21

Table 2. Comparative measurements (μm) of L3 larvae of *Anisakis simplex* isolated from intestine of bogue *Boops boops* and sardine *Sardina pilchardus* from Edremit Bay (Ayvalık), northern Aegean Sea between September and February 2015, and previous studies (– indicates absence of data)

Morphological characters	Hurst (1984)	Afssa (2006)	Quiazon et. al. (2008)	Felizardo et al. (2009)	Al-Zubaidy (2010)	Tepe and Oğuz (2013)	Yardımcı et al. (2014)	Torcu Koç and Erdoğan (2020)	This study
Total body length	14.0-26.0	18.0-36.0	11.10-26.78	15.3-16.0	12.45-22.5	12.05-17.64	12.80-24.65	12.79-27.69	12.79-28.48
Body width	0.29-0.56	0.3-0.7	0.38-0.60	0.35-0.37	0.13-0.41	0.30-0.54	0.40-0.51	0.42-0.63	0.75-1.30
Oesophagus length	1.57-2.34	-	1.04-2.11	1.53 – 1.62	1.30-2.98	0.69-1.78	0.98-1.87	1.02-2.14	2.09-3.17
Ventriculus length	0.47-0.85	-	0.50-0.78	0.22 – 0.25	0.56-0.99	0.50-0.81	0.53-0.74	0.55-0.84	0.9-1.91
Tail length	0.09-0.15	-	0.05-0.12	0.07 – 0.08	0.09-0.58	0.07-0.21	0.08-0.11	0.09-0.13	0.16-0.22
Spicule (Mucron)	0.015-0.030	-	-	0.02 – 0.03	0.015-0.022	-	-	-	0.015–0.028

Fam: Anisakidae

***Hysterothylacium aduncum* (Rudolphi, 1802)**

Synonym: *Contracaecum aduncum* (Rudolphi, 1802)

Host fish species: *Boops boops*, *Sardina pilchardus*

A total of parasite: 93

As to the morphology and anatomy of *H. aduncum*, they are also identified in details by Berland (1989). *H. aduncum* adults possess a tapering tail without mucron or spicule. The ventriculus short, and the ventricular appendix is longer than the intestinal caecum. The excretory pore opens between subventral lips according to Koyama et al. (1969) and Kikuchi et al. (1970). Body thinner anteriorly. Cuticle transversally striated, lateral alae with support v-shaped in cross-section, starting behind the base of the lips and extending all along the body, becoming narrower posteriorly (Navone et al., 1988) (Figure 2A, 2B). In addition, the reason why that the intestinal caecum of *H. aduncum* was usually shorter than the ventricular appendix confirmed the relevant literature (Table 3 and 4) (Vidal-Martinez et al., 1994). Morphological characters of female and male *H. aduncum* were measured and seen to be in harmony with the previous literature, respectively (Table 3, 4)



Figure 2A. *Hysterothylacium aduncum* (♀) (Original photo)

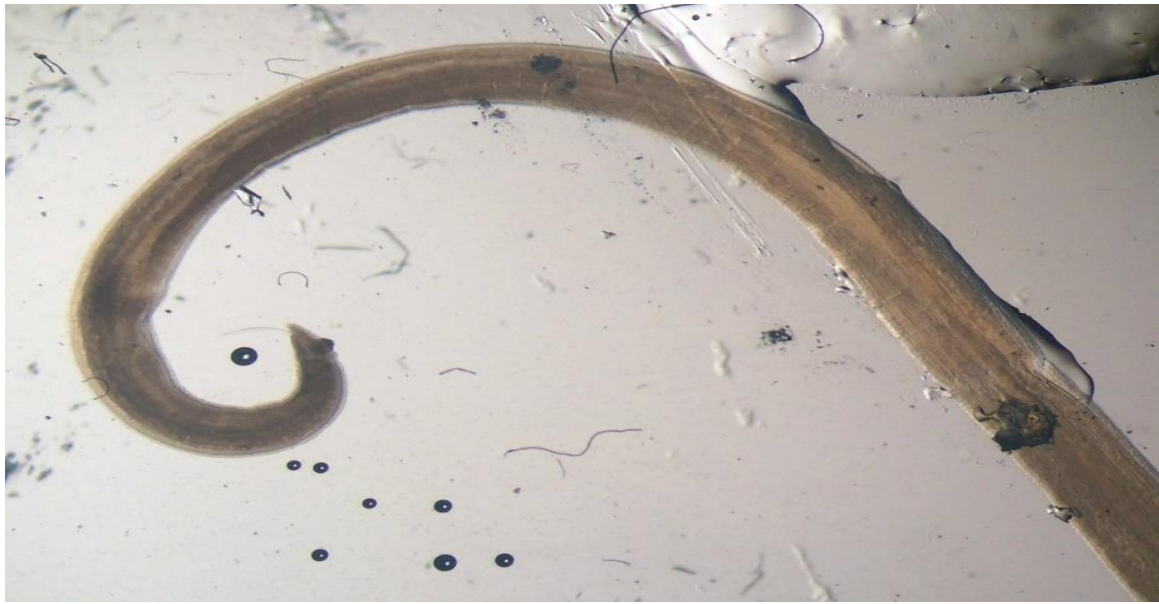

Figure 2B. Posterior part of *Hysterothylacium aduncum* (♂)(Original photo)

Table 3. Comparative measurements (μm) of *Hysterothylacium aduncum* (♀) isolated from intestine of bogue *Boops boops* and sardine *Sardina pilchardus* from Edremit Bay (Ayvalık), northern Aegean Sea between September and February 2015, and previous studies (– indicates absence of data)

Morphological characters	Navone et al. (1988)	Shih and Jeng (2002)	Felizardo et al. (2009)	Tepe and Oğuz (2013)	This study
Total body length	42.4-47.2	22.1 (10.3-43.2)	4.88 – 5.06	30.958–48.029 (37.770± 67.71)	43.65-52.29 (24.06±18.06)
Body width	0.58-0.65	0.33 (0.19-0.42)	0.09 – 0.22	0.03–0.66 (496 ± 138)	0.04-1.4 (0.6±0.5)
Oesophagus length	3.31-3.7	2.31 (1.29-3.37)	0.64 – 0.70	2.31–4.28 (3025 ± 794)	0.93-3.53 (2.18±1.40)
Ventriculus appendage length	0.71-0.75	0.89 (0.64-1.09)	0.15 – 0.17	0.53–1.05 (684 ± 249)	1.02-1.19 (1.12±0.09)
Tail length	0.3-0.35	-	0.23 – 0.25	0.1–0.32 (252 ± 77)	0.1-0.14 (0.12±0.01)
Excretory pore-distal end	-	-	-	0.41–0.56 (479 ± 78)	0.24-0.79 (0.39±0.26)

Table 4. Comparative measurements (μm) of *Hysterothylacium aduncum* (♂) isolated from intestine of bogue *Boops boops* and sardine *Sardina pilchardus* from Edremit Bay (Ayvalık), northern Aegean Sea between September and February 2015, and previous studies (– indicates absence of data)

Morphological characters	Nanove et al. (1998)	Shih and Jeng (2002)	Tepe and Oğuz (2013)	This study
Total body length	23.7-25.8	(8.9-24.8) 18.7	18.879-44.457 (25.544±9661)	10.98-42.77 (33.25±15.13)
Body width	0.27-0.39	(0.12-0.36) 0.26	0.31–0.40 (344 ± 33)	0.8-11.78 (8.53±5.2)
Oesophagus length	1.85-2.02	(1.26-2.96) 1.83	1.76–2.41 (1983 ± 241)	1.42-4.73 (3.49±2.23)
Ventricular appendage length	0.44-0.65	(0.64-0.96) 0.82	0.44–0.61 (498 ± 65)	0.61
Tail length	0.13-0.17	-	0.8–0.20 (134 ± 40)	0.1-0.16 (0.1±0.01)
Excretory pore-distal end	-	-	0.38–0.42 (401 ± 17)	0.81-0.93 (0.9±0.07)
Intestinal caecum length	0.82-1.20	(0.32-0.44) 0.38	0.50–1.00 (569 ± 62)	0.28-2.78 (2.1±1.2)
Spicule (Mucron)	0.69-1.1.41	0.78	0.95	0.6–1.95 (1.46±0.1)

Fam: Anisakidae

***Pseudoterranova decipiens* (Krabbe 1878)**

Host: *Boops boops*

A total of parasite: 2

Life cycle of *P. Decipiens*

The adult worm stage is found in the seal's stomach; released eggs are passed with feces into the marine environment. Third stage larvae hatch from eggs and are ingested by invertebrates (copepods, amphipods) which are subsequently ingested by teleosts to act as transport hosts. Like *A. simplex*, *P. decipiens* can be transmitted from fish to fish (Jensen, 1997). Adult stage develops in seals which ingest infected teleosts (Buchman and Mehrdana, 2016).

Diagnostic Remarks:

Total lengths of the nematod specimens ranged from 47116 µm to 58119 µm (Table 5). The morphological features and anatomy of the anisakid nematode *P. decipiens* are described in detail by Berland (1989). L3 larvae of the parasite are yellowish-brown and larger than *Anisakis* larvae (30–40 mm in length). External structures include an excretory pore, and a longer and more slender terminal mucron or spicule. The ventricle is shorter and joins the intestine via a horizontal junction. A characteristic intestinal caecum projects from the intestine to the anterior end in the ventricular region. The tail is short, conic and pointed. The tail of male *P. decipiens* is different from female, having a spicule (Figure 3B, Table 5). However, the adult worms of Anisakidae examined were characterized by the typical “cactus tail” (Yoshinaga et al., 1987a; Navone et al., 1988). The remaining internal structures are similar to those observed in *A. simplex* (Figure 3A, 3B). Morphological features were measured (Table 5) and not seen to be similar to the previous investigations possibly due to lack of the parasite numbers (Table 6).

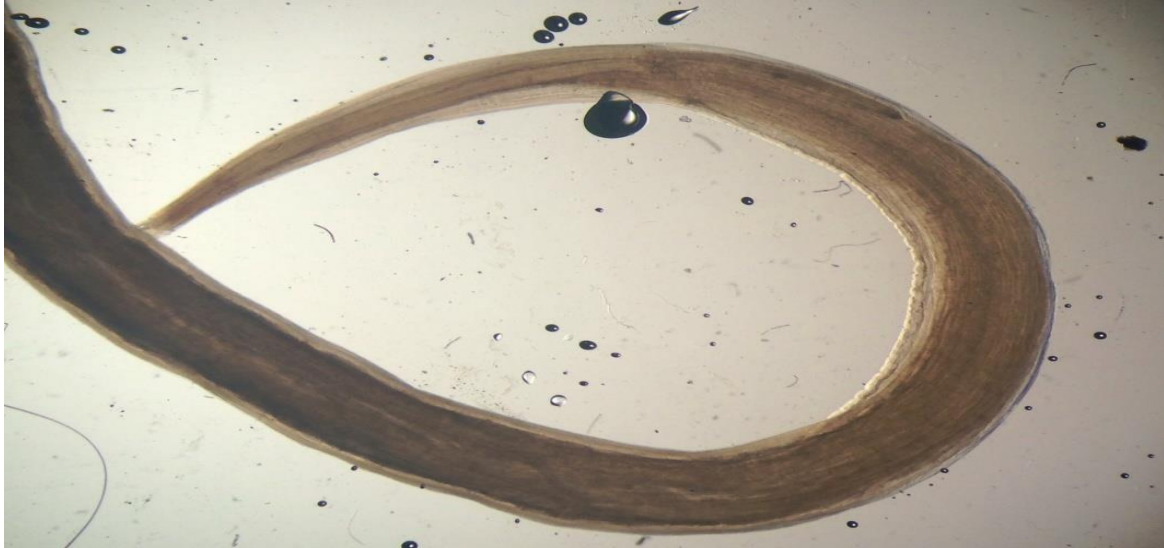


Figure 3A. Anterior part of female *Pseudoterranova decipiens* (Original photo)



Figure 3B. Posterior part of male *Pseudoterranova decipiens* (Male) (Original photo by Kuran)

Table 5. Morphometry (μm) of L3 larvae *Pseudoterranova decipiens* isolated from intestine of bogue *Boops boops* between September and February 2015, Edremit Bay (Ayvalık), northern Aegean Sea. Mean \pm 1 standard deviation (SD) and range. Measurements are in (μm).

Morphometric variables (μm)	Male (1 specimens)	Female (1 specimen)
Body length	47116	58119
Body width	1350	1543
Nerve ring-anterior end	-	1056
Oesophagus length	5116	6090
Ventriculus length	1320	3045
Tail length	183	162
Left spicule	2091	-
Right spicule	1979	-
Excretory pore-distal end	1096	-

Table 6. Comparative measurements (mm) of some morphological characters in L3 larvae of *Pseudoterranova decipiens* (σ) isolated from intestine of bogue *Boops boops* between September and February 2015, Edremit Bay (Ayvalık), northern Aegean Sea and previous studies (- indicates absence of data)

Morphological Characters	Hurst (1984)	Chai et al. (1995)	Mercado et al. (1997)	Felizardo et al. (2009)	Al-Quraishy et al. (2019)	This study
N	19					2
Total body length	28.6-29.8	25.0-28.5	32.2	5.63– 7.75	6.8-8.6 (7.2 \pm 1.1)	58.12 (F) 47.12 (M)
Body Width	0.88-1.18	0.6-0.8	-	0.16– 0.18	0.16–0.21 (0.18 \pm 0.01)	1.5 (F) 1.3 (M)
Oesophagus length	1.91-2.03	-	2.2	0.78– 1.20	0.79-0.96 (0.91 \pm 0.01)	6.09 (F) 5.12 (M)
Ventriculus length	0.76-0.90	-	1.1	0.05– 0.15	-	3.05 (F) 1.32 (M)
Tail length	0.12-0.14	-	0.2	0.10– 0.32	0.10–0.20 (0.15 \pm 0.01)	1.83 (M) 1.62 (F)
Right Spicule	-	-	-	-	-	2.09 (M)
Left Spicule	-	-	-	-	-	1.98 (F)
Nerve ring anterior end	0.36-0.45	-	0.41	0.11– 0.22	-	1.05 (F)
Excretory pore-distal end	-	-	-	-	-	1.1 (M)

DISCUSSION

Sardina (*S. pilchardus*) and boque (*B. boops*) are pelagic fishes that feed on planktonic crustaceans and small fish (Costalago and Palomera, 2014; Shawket et al., 2015) and may be therefore become infected with *A. simplex*, *H. aduncum*, and *P. decipiens* by consuming small crustaceans (euphausiids, amphipods), which are intermediate hosts of these nematodes (Smith, 1983, 1984; Stromnes and Andersen, 1984; Pozzi et al. 1992; Manfredi et al., 2000). The Anisakidae are a family of intestinal roundworms. The third stage larvae (L3) of *A. simplex* and *H. aduncum* were found within the intestine of both boques and sardines while all L3 larvae of *P. decipiens* infected bogues. These observations agreed with data obtained by Klimpel and Palm (2011) and Aytemiz et al. (2012) followed by Najda et al. (2018) whom stated that the digestive tract considered as the preferred site of anisakid infection in marine mammals. The morphology of the present L3 larva of *P. decipiens* parasite includes the same diagnostic generic features of genus *Pseudoterranova* by having an elongated body ending by a short pointed tail and agrees much more with *P. decipiens* described previously by Timi et al. (2013). Al Quraishy et al., (2019) also confirmed the morphological and morphometric data of *P. decipiens* isolated from *Engraulis anchoita* and *Lethrinus lentjan*. In addition, it resembled to records from *Paralichthys isosceles* by Felizardo et al. (2009) and *Lophius gastrophysus* with little difference in measurements by Piña-Vázquez et al. (2012).

Although *P. delicipens* has been monitored to more than 30 marine fish species such as cod, pollock, halibut, and flatfish all over the world, Bristow and Berland (1992) mentioned that *Pseudoterranova* spp. larvae and adults existed in very small numbers compared with other *Anisakis* spp. In this present study, the lower number of *P. decipiens* larvae in *B. boops* suggest that it might penetrate into the gastrointestinal systems of boques with its diet accidentally.

CONCLUSION

This study represented *A. simplex*, *H. aduncum* and *P. decipiens* found in the intestines of boques and sardines in Edremit Bay. Of these parasites, the adults of *P. decipiens* parasites were first found in the intestines of *B. boops*. Parasitological studies are very important for fish diversity in Turkish Seas. In the future, molecular analyses are required to provide more specific information such as their distributions and infection values for parasitological studies and to understand the epidemiology of anisakiasis.

Anisakid parasites can be a potential human pathogen if larvae are eaten alive with raw or inadequately cooked fish. Evidence of hypersensitivity in humans to remnants of Anisakids has been reported, even following cooking (Anadon et al., 2010). There is therefore a potential risk to susceptible individuals (. Aesthetically, severely affected fish are likely to be unattractive to the consumer. Processed fish are screened for the presence of parasites but this is a time consuming and costly process (Smith, and Wooten, 2012). Raw eating of bogues and sardinas caught from Turkish Seas should be avoided so as to prevent human anisakiasis.

Besides, Anisakiasis is a zoonotic disease with a dramatic and serious increase in the view of its reported prevalence throughout the world in the last years (Elarifi, 1982; Chai et al., 2005). Human can act as incidental host by ingestion of raw or undercooked infected fish. Anisakis causes several symptoms such as stomach pain, vomiting (Smith and Wooten, 1978; Mercado et al., 1997; Buchman and Mehrdna, 2016.), allergic reaction in humans (Audicana et al., 2002; Alonso-Gómez et al., 2004). Nematodes should be evaluated as a public health problem by health authorities. The occurrence of Anisakids have reduced the quality and marketing value of fishes (Abollo, 2001). Therefore, for wild and cultured marine fish, these parasites should be taken care of.

Anisakid larvae present in fish flesh would be killed by freezing at $-20\text{ }^{\circ}\text{C}$ for 60 hrs. According to Margolis (1987), cooking 3 cm-thick fish fillets of at $^{\circ}\text{C}60\text{-}^{\circ}\text{C}70$ for 7 or 10 minutes, respectively, will kill any codworm larvae present.

RESPECT TO ETHIC RULES

a)KK wrote the thesis under the supervision of MCO, HTK wrote the manuscript, HTK and ZE drew the tables, all of authors read the final of the manuscript and confirmed.

b) There is no conflict of interest between authors.

REFERENCES

- Abollo, E., Gestal, C. & Pascual, S., (2001). Anisakis infestation in marine fish and cephalopods from Galician waters: an updated perspective. *Parasitology Research Journal*, 87: 492-499.
- Adams, T., Bezner, J. & Steinhardt, M., (1997). The conceptualization and measurement of perceived wellness: Integrating balance across and within dimensions. *American Journal of Health Promotion*, 12: 380-388.
- Agence Francaise De Securite Sanitarie Des Aliments (AFSSA) 2006. *Anisakis* spp. *Pseudoterranova* spp. (Nématodes, Secernentea, Ascaridida, Anisakidés). Agence de l'anisakiase. *EFSSA Journal*, 4 p. (in French).
- Akmirza, A., (1997). Samples from parasites of *Scomber japonicus* Houttuyn, 1786. *Ege Journal of Fisheries and Water Products*, 14 (1-2): 173-181.
- Akmirza, A., (1998a). The Parasite fauna of horse mackerel. III. National Symposium of Aquatic Products, 333-344, Erzurum.
- Akmirza, A., (2000a). Metazoan parasites of red mullet (*Mullus surmuletus*) caught near Gökçeada. *Istanbul Journal of Istanbul Veterinary Sciences*, 26(1): 129-140.
- Akmirza, A., (2001b). Metazoan parasites of striped red mullet (*Mullus surmuletus* L.) from the vicinity of Gökçeada. *Istanbul Journal of Istanbul Veterinary Sciences*, 26(1): 129-140.
- Akmirza, A., (2013). Parasitic nematodes of fishes coasts of Gökçeada. *Journal of Turkish Parasitology*, 3: 199-202, (2013) (In Turkish).
- Al-Quraishy, S., Abdel-Gaber, R. & Dkhil, M.A.M., (2019). First record of *Pseudoterranova decipiens* (Nematoda, Anisakidae) infecting the Red spot emperor *Lethrinus lentjan* in the Red Sea Primeiro registro de *Pseudoterranova decipiens* (Nematoda, Anisakidae). *Brazilian Journal of Veterinary Parasitology*. <https://doi.org/10.1590/S1984-29612019057>
- Alonso-Gómez, A., Moreno-Ancillo, A. & López-Serrano M.C., (2004). *Anisakis simplex* only provokes allergic symptoms when the worm parasitises the gastrointestinal tract. *Parasitological Research*, 93: 378-384.

- Alvarez, F., Iglesias, R., Parama, A. R., Leiro, J. & Sanmartin, M., (2002). Abdominal macroparasites of commercially important flatfishes (Teleostei: Scophthalmidae, Pleuronectidae, Soleidae) in northwest Spain (ICES IXa). *Aquaculture*, 213: 31-53.
- Al-Zubaidy, A., (2010). Third-stage larvae of *Anisakis simplex* (Rudolphi, 1809) in the Red Sea Fishes, Yemen Coast. *King Abdülaziz Journal of Marine Sciences*, 21(1): 95-112.
- Anadon, A. M., Rodriguez, E., Garate, M. T., Cuellar, C., Romaris, F., Chivato, T., Rodero, M., Gonzalez-Diaz, H. & Ubeira, F. M., (2010). Diagnosing human anisakiasis: recombinant *Anisakis* 1 and *Anisakis* 7 allergens versus the UniCAP 100 fluorescence enzyme immunoassay. *Clinic and Vaccine Immunology*, 17: 496– 502.
- Anderson, M.J. (2001). A new method for non-parametric multivariate analysis of variance. *Australian Journal of Ecology*, 1(26): 32–46.
- Aspholm, P. E., Ugland, K. I., Jodestol, K. A., & Berland, B. (1995). Sealworm (*Pseudoterranova decipiens*) Infection in common seals (*Phoca-Vitulina*) and potential intermediate fish hosts from the outer Oslofjord. *International Journal for Parasitology*, 25(3): 367-373.
- Audicana, M.T., Ansotegui, I.J., Corres, L.F. & Kennedy, M.W., (2002). *Anisakis simplex*: dangerous-dead and alive? *Trends in Parasitology*, 18: 20-25.
- Aytemiz, I., Dede A., Danyer E., & Tonay, A.M. (2012). Morphological identification of parasites found in the stomach contents of bycaught striped dolphins (*Stenella coeruleoalba*) from Turkish Eastern Mediterranean Sea coast. *Journal of Black Sea/Mediterranean*, 18: 238-245.
- Aznar, F.J., Fognani, P., Balbuena, J.A., Pietrobelli, M., & Raga, A., (2006) distribution of *Pholeter gastrophilus* (Digenea) within the stomach of four odontocete species: the role of the diet and digestive physiology of hosts. *Parasitology*, 133: 369-380.
- Ballard, W., Mellinger, J. and Lechenault, H., (2005). Series of normal stages for development of *Scyliorhinus canicula* the lesser spotted dogfish (Chondrichthyes: Scyliorhinidae), *Journal of Experimental Zoology*, 267: 318-336.
- Beceriklisoy, Ö.G, Aşti, C. & Gönenç, B., (2020). *Anisakis* spp. infection in Atlantic mackerel (*Scomber scombrus*, Linnaeus 1758) from the Sea of Marmara. *Veteriner Hekimler Derneği Dergisi*, 91(1): 80-85. <https://doi.org/10.33188/vetheder.599455>.
- Berland, B., (1989). Identification of larval nematodes from fish. International Council Exploration Sea, C.M.(F,6), 16-22.
- Bristow, G.A. & Berland, B., (1992). On the ecology and distribution of *Pseudoterranova decipiens* (Nematoda: Anisakidae) in an intermediate host, *Hippoglossoides platessoides*, in Northern Norwegian waters. *International Journal of Parasitology*, 22: 203–208.
- Buchmann, K. & Kania, P., (2012). Emerging *Pseudoterranova decipiens* (Krabbe, 1878) problems in Baltic cod, *Gadus morhua* L., associated with grey seal colonization of spawning grounds. *Journal of Fish Diseases*, 35: 861–866.
- Buchman, K. & Mehrdna, F., (2016). Effects of anisakid nematodes *Anisakis simplex* (s.l.), *Pseudoterranova decipiens* (s.l.) and *Contracaecum osculatatum* (s.l.) on fish and consumer health. *Food and Waterborne Parasitology*, 4: 13-22.
- Chai J.Y., Murrell K.D. & Lymbery A.J. (2005). Fish-borne parasitic zoonoses: Status and issues. *International Journal of Parasitology*, 35, 1233- 1254.
- Costalago, D. & Palomera, I., (2014). Feeding of European pilchard (*Sardina pilchardus*) in the northwestern Mediterranean: from late larvae to adults. *Scientia Marina*, 78, 41-44. <http://dx.doi.org/10.3989/scimar.03898.06D>
- Danyer, E., Aytemiz, I., Tonay, A. M., Dede, A. & Akkaya, H. (2010). Preliminary study of identification of macroscopic parasites in the stomach content of the harbour porpoises (*Phocoena phocoena*) bycaught and stranded in the Turkish Western Black Sea. Proceedings of 12th Conference of International Veterinary Medicine Students Research, Istanbul, pp.74-75.
- Doğanay, A. (1994). *Hysterothylacium aduncum* (Rudolphi 1802) pattern in cods *Merlangius merlangus* which is caught from Black Sea. *Ankara Journal of Veterinary*, 41 (2): 208-217.
- Dzido, J., Kijewska, A., Rokicka, M., Swiatalska-Koseda, A. & Rokicki, J. (2009). Report on anisakid nematodes in polar regions e preliminary results. *Journal of Polar Science*, 3: 207-211.
- Elarifi, A.E. (1982). The histopathology of larval anisakid nematode infections in the liver of whiting, *Merlangius merlangus* (L.), with some observations on blood leucocytes of the fish. *Journal of Fish Diseases*, 5: 411-419.
- European Food Safety Authority (2010). Scientific opinion of the Panel on Biological Hazards on risk assessment of parasites in fishery products. *EFSA Journal*, 8: 10–43. <http://doi.org/10.2903/j.efsa.2010.1543>.
- Fagerholm, H. P. (1982). Parasites of fish in Finland, 6, Nematodes. *Acta Academia Aboensis, Serial B 40*: 1–128.

- Felizardo, N.N., Menezes, R.C., Tortelly, R. Knoff, M., Pinto, R.M. & Gomes, D.C. (2009). Larvae of *Hysterothylacium* sp. (Nematoda: Anisakidae) in the sole fish *Paralichthys isosceles* Jordan, 1890 (Pisces: Teleostei) from the littoral of the state of Rio de Janeiro, Brazil. *Veterinary Parasitology* 166: 175–177.
- Gaevskaya, A. V. & Rodjuk, G. N. (1988). Ecological characteristics of the parasitofauna of the macrourid *Macrourus carinatus* Günther in the South Atlantic. *Nauchnye Doklady Vysshei Shkoli. Biologicheskie Nauki*, 2: 21–25, (in Russian).
- Henderson, A. C. & Dunne, J. J. (1998). The metazoan parasites of the lesserspotted dogfish *Scyliorhinus canicula* (L.) from the Galway Bay area. *Journal of Irish Naturalist's*, 26 (3/4): 104-107.
- Højgaard. (1998). Impact of temperature, salinity and light on hatching of eggs of *Anisakis simplex* (Nematoda, Anisakidae), isolated by a new method, and some remarks on survival of larvae. *Sarsia*, 83: 21-28.
- Hure, M. & Mustac, B. (2020). Feeding ecology of *Sardina pilchardus* considering co-occurring small pelagic fish in the eastern Adriatic Sea. *Marine Biodiversity*, 50 (40).
- Hurst, R. J. (1984). Identification and description of larval *Anisakis simplex* and *Pseudoterranova decipiens* (Anisakidae: Nematoda) from New Zealand waters, *New Zealand Journal of Marine and Freshwater Research*, 18(2): 177-186. <http://dx.doi.org/10.1080/00288330.1984.9516040>.
- Ivanović, J., Baltić, M.Z., Bošković, M., Kilibarda, M., Dokmanović, N., Marković, R., Janjić, J. & Baltić, B. (2017). *Anisakis* allergy in human. *Trends of Food Science and Technology*, 59: 25-29.
- İşmen, A., Bingel, F. (1999). Nematode infection in the whiting *Merlangius merlangus euxinus* off Turkish coast of the Black Sea. *Fisheries Research*, 42: 183–189.
- Jensen, T. & Andersen, K. (1992). The importance of sculpin (*Myoxocephalus scorpius*) as intermediate host and transmitter of the sealworm *Pseudoterranova decipiens*. *International Journal of Parasitology*, 22: 665–668.
- Jensen, T. (1997). Experimental infection/transmission of sculpins (*Myoxocephalus scorpius*) and cod (*Gadus morhua*) by sealworm (*Pseudoterranova decipiens*) larvae. *Parasitological Research*, 83: 380–382.
- Kalay, M., Dönmez, A.E., Koyuncu, C.E., Genç, E. & Şahin, G. (2009). Seasonal variation of *Hysterothylacium aduncum* (Nematoda: Raphidascarididae) infestation in sparid fishes in the Northeast Mediterranean Sea. *Turkish Journal of Veterinary Animal Sciences*, 33(6): 517-523. <http://dx.doi.org/10.3906/vet-0703-12>.
- Keser, R., Bray, R. A., Oğuz, M. C., Çelen, S., Eroğan, S., Doğutürk, S., Aklanoğlu, G. & Marti, B. (2007). Helminth parasites of digestive tract of some teleost fish caught in the Dardanelles at Çanakkale, Turkey. *Helminthologia*, 44(4): 217–221.
- Kikuchi, S., Kosugi, K., Hirabayashi, H. & Hayashi, M. (1970). Six types of *Contracaecum* larvae (Nematoda) found in the sea fishes in Japan. *Journal of Yokohama Medical*, 21: 421-427.
- Kijewska, A., Dzido, J., Shukhgalter, O. & Rokicki, J. 2009. Anisakid parasites of fishes caught on the African Shelf. *The Journal of Parasitology*, 95(3): 639-645.
- Klimpel, S. & Palm, H. W. (2011). Anisakid nematode (Ascaridoidea) life cycles and distribution: increasing zoonotic potential in the time of climate change In: Mehlhorn, H. (Ed.), *Progress in Parasitology. Parasitology Research Monographs*. 2.nd ed. Heidelberg., SpringerVerlag, 201–222.
- Køie, M., Berland, B. & Burt, M.D.B. (1995). Development to third-stage larvae occurs in the eggs of *Anisakis simplex* and *Pseudoterranova decipiens* (Nematoda, Ascaridoidea, Anisakidae). *Canadian Journal of Fisheries and Aquatic Sciences*, 52(S1 Suppl.1): 134-139. <http://dx.doi.org/10.1139/f95-519>.
- Koyama, T., Kobayashi, A., Kumada, M. & Komiya, Y. (1969). Morphological and taxonomical studies on Anisakinae larvae found in marine fishes and squids. *Japanese Journal of Parasitology*, 18: 466–487.
- Kruse, G. O. W. & Pritchard, P. H. (1982). The Collection and preservation of animal parasites. *Technical Bulletin*, 1, The Harold W. Wanter Laboratory.
- Langston, W. J. (1990). Toxic effects of metals and the incidence of marine ecosystems, pp. 102-122. In: Furness, R. W. (Ed.), *Rainbow Heavy Metals in the Marine Environment*. New York, USA: CRC Press. 256p.
- Lunneryd, S.G., Boström, M. K. & Aspholm, P. E. (2015). Sealworm (*Pseudoterranova decipiens*) infection in grey seals (*Halichoerus grypus*), cod (*Gadus morhua*) and shorthorn sculpin (*Myoxocephalus scorpius*) in the Baltic Sea. *Parasitology research*, 114 (1): 257-264. <http://dx.doi.org/10.1007/s00436-014-4187-z>.
- Lymbery, A. J. & Cheah, F.Y. (2007). Anisakid nematodes and anisakiasis. In: Murrell KD, Fried B, editors. *Food-borne parasitic zoonoses: fish and plant-borne parasites*. New York: Springer Science; 2007. p. 185–207.
- Manfredi, M. T., Crosa, G., Galli, P. & Ganduglia, S. (2000). Distribution of *Anisakis simplex* in fish caught in the Ligurian Sea. *Parasitology Research*, 86(7): 551-553.
- Marcogliese, D.J. (2001). Parasites of fish in freshwater; EMAN, Canada. Retrieved on 5 Oct 2016 from <http://www.eman>.

- Margolis, L. (1977). Public health aspects of "codworm" infection: A review. *Journal of Fisheries Research of Board Canada*, 34: 887-898.
- Mattiucci, S., Paoletti, M., De Angelis, M., Sereno, S. & Cancrini G. (2007). Human anisakidosis in Italy: molecular and histological identification of two new cases. *Parasitologia*, 49: 226-240,
- McClelland, G., Misra, R. K. & Martell, D. J. (1987). Temporal and geographical variations in abundance of larval sealworm, *Pseudoterranova* (Phocanema) decipiens in fillets of American plaice (*Hippoglossoides platessoides*) in eastern Canada: 1985–86 surveys. Canadian Technical Report of Fisheries and Aquatic Sciences, 1513: 1-15.
- McClelland, G. (1990). Larval sealworm (*Pseudoterranova decipiens*) infections in benthic macrofauna. *Canadian Bulletin of Fisheries and Aquatic Sciences*, 222: 47–65
- McClelland, G., Misra, R.K. & Martell, D.J. (1990). Larval anisakine nematodes in various fish species from Sable Island Bank and vicinity. pp. 83-118. In: Bowen, W.R. (Ed.), Population biology of sealworm (*Pseudoterranova decipiens*) in relation to its intermediate and seal host. Ottawa: *Canadian Journal of Bulletin of Fisheries and Aquatic Sciences*, Ottawa, 222; 83–118.
- Mercado, R., Torres, P. & Maira, J. (1997). Human case of gastric infection by a fourth larval stage of *Pseudoterranova decipiens* (Nematoda, Anisakidae). *Revista de Saúde Pública*, 31(2): 178-81.
- Mladineo, I. & Poljakb, V. (2014). Ecology and genetic structure of zoonotic *Anisakis* spp. from Adriatic commercial fish species. *Applied and Environmental Microbiology*, 80(4): 1281–1990.
- Murata, R., Suzuki, J., Sadamasu, K. & Kai, A. (2011). Morphological and molecular characterization of *Anisakis* larvae (Nematoda: Anisakidae) in *Beryx splendens* from Japanese waters. *Parasitology International* 60: 193–198.
- Myers, B. J. (1976). Research then and now on the Anisakidae nematodes. *Translations of American Microscopic Society*, 95(2): 137-142.
- Najda K, Kijewska A, Kijewski T, Plauška K. & Rokicki J. (2018). Distribution of ascaridoid nematodes (Nematoda: Chromadorea: Ascaridoidea) in fish from the Barents Sea. *Oceanologic Hydrobiologic stud* 2018; 47(2): 128-139. <https://doi.org/10.1515/ohs-2018-0014>.
- Navone, G. T., Sardella, N. H. & Timi, J. T. (1988). Larvae and adults of *Hysterothylacium aduncum* (Rudolphi, 1802) (Nematoda: Anisakidae) in fishes and crustaceans in the South West Atlantic. *Parasite*, 5: 127-136.
- Nelson, J.S. (1994). *Fishes of the world*. John Wiley and Sons, Interscience Publications, 600 p.
- Oğuz, M. C. (1995). Helminths seen in some teleost fishes in coast of Mudanya. Ph. D. Thesis. Uludağ University, Bursa, Turkey.
- Oğuz, M. C., Güre, H., Özdemir, H., Öztürk, M. O. & Savaş, Y. (2000). Investigation of *Anisakis simplex* of some economically important teleost fishes in coast of Çanakkale. *Journal Turkish Parasitology*, 24(4): 431-434.
- Öktener, A. (2005). A checklist of parasitic helminths reported from sixty-five species of marine fish from Turkey including two new records of monogeneans. *Zootaxa*, 1063: 33–52.
- Özkan, Y., Aksakal, E. & Oguz, M. C. (2010). Determination of compared abundance, intensity, and prevalence of nematod larvae reported from mackerel (*Trachurus trachurus*, L. 1758). *Journal of Biological Sciences*, 1: 145-147.
- Palm, H. W. (1999). Ecology of *Pseudoterranova decipiens* (Krabbe, 1878) (Nematoda: Anisakidae) from Antarctic Waters. *Parasitologic Research*, 85(8-9): 638-646. Pekmezci, G. Z. (2019). Molecular Characterization of *Hysterothylacium aduncum* (Nematoda: Raphidascarididae) Larvae Infecting *Merlangius merlangus euxinus* (Linnaeus, 1758) from the Turkish Black Sea Coast based on mitochondrial small subunit ribosomal RNA gene analysis. *Journal of Veterinary and Microbiology*, 30(1): 64-69
- Piña-Vázquez, C., Reyes-López, M., Ortiz-Estrada, G., de la Gar, M. & Serrano-Luna, J. (2012). Host-Parasite Interaction: parasite-derived and induced proteases that degrade human extracellular matrix. *Journal of Parasitological Reserach*: 1-63.
- Plessis, K., Lopata, A. L. & Steinman, H. (2004). Adverse reactions to fish. *Current Allergy and Clinic Immunology*, 17: 4-8.
- Pollard, D., Carpenter, K.E. & Russell, B. (2014). *Boops boops*. The IUCN Red List of Threatened Species 2014:e.T170251A1301787. <https://dx.doi.org/10.2305/IUCN.UK.20143.RLTS.T170251A1301787.en>. Downloaded on 26 November 2020.
- Pozzi, G., Oggioni, M. R., Manganelli, R. & Fischetti, V. A. (1992). Surface expression of M6 protein in *Streptococcus gordonii* Challis after transcriptional fusion with chromosomal promoters. *Research of Microbiology*, 143: 449-459.
- Pritchard, M. H. & Kruse, G. O. W. (1982). *The collection and preservation of animal parasites*. Lincoln, Nebraska, University of Nebraska Press, 141 p.

- Quiazon, K. M. A., Yoshinaga, T., Ogawa, K. & Yukami, R. (2008). Morphological differences between larvae and in vitro cultured adults of *Anisakis simplex* (sensu stricto) and *Anisakis pegreffii* (Nematoda: Anisakidae). *Parasitology International*, 57: 483–489.
- Rahimi, M. T., Gholami, Z., Esmaeili, H. R. & Mobedi, I. (2013). Survey on ectoparasites of *Aphanius sophiae* (Cyprinodontidae) from southern Iran *Iranian Journal of Coastal Life Medicine*, 1(2): 85-87.
- Rello, F. J., Adroher, F. J. & Adela Valero, A. (2008). *Hysterothylacium aduncum*, the only anisakid parasite of sardines (*Sardina pilchardus*) from the southern and eastern coasts of Spain. *Parasitological Research*, 104:117–121. <https://doi.org/10.1007/s00436-008-1168-0>
- Shawket, N., El Aasri, A., Elmadhi, Y., M'Bareck, I., El Kharrim, K. & Belghyti, D. (2017). *Anisakis simplex* (Nematoda: Anisakidae) from horse mackerel (*Trachurus trachurus*) in Atlantic coast of Morocco. *Asian Pacific Journal of Tropical Disease*, 7(8): 463-466.
- Shih, H. H. & Jeng, M. S. (2002). *Hysterothylacium aduncum* (Nematoda: Anisakidae) infecting a herbivorous fish, *Siganus fuscescens*, off the Taiwanese Coast of the Northwest Pacific. *Zoological Studied-Taipei*, 41: 208-215.
- Smith, J.W. (1983). *Anisakis simplex* (Rudolphi, 1809, Det. Krabbe, 1878) (Nematoda: Ascaridoidea): morphology and morphometry of larvae from euphausiids and fish, and a review of the life-history and ecology. *Journal of Helminthology*, 57: 205-24.
- Smith, J. W. (1984). Larval ascaridoid nematodes in myopsid and oegopsid cephalopods from around Scotland and in the northern North Sea. *Journal of the Marine Biological Association of the United Kingdom*, 64: 563-572.
- Smith, J. W. & Wootten, R. (2012). Anisakis larvae ("herringworm"; Nematoda) in fish. *ICES Identification Leaflets for Diseases and Parasites of Fish and Shellfish. Leaflet*, 8: 5 p.
- Stromnes, E. & Andersen, K., 1984. "Spring rise" of whaleworm (*Anisakis simplex*; Nematoda, Ascaridoidea) third-stage larvae in some fish species from Norwegian waters. *Parasitological Research*, 86 (8), 619-624.
- Şahin, A. G. (2016). Investigation of nematodes in chub mackerel (*Scomber japonicus* Houttuyn, 1782), horse mackerel (*Trachurus trachurus* (Linnaeus, 1758)) and sardines (*Sardinella aurita* Valenciennes, 1847) caught in Çanakkale Region. *Yunus Research Bulletin*, 1. <https://doi.org/10.17693/yunus.58953>.
- Tepe, Y. & Oğuz, M. C. (2013). Nematode and acanthocephalan parasites of marine fish of the eastern Black Sea coasts of Turkey. *Turkish Journal of Zoology*, 37:753–760.
- Toğulga, M. (1997). The studies on population dynamics of red mullet (*Mullus barbatus* Lin. 1758) in İzmir Bay. *Ege Journal of Science, Series B, C.I.S.2*: 175-194.
- Timi, J.T., Sardella, N. H., & Navone, G. T. (2001). Parasitic nematodes of *Engraulis anchoita* Hubbs et Marini, 1935 (Pisces, Engraulidae) off the Argentine and Uruguayan coasts, South West Atlantic. *Acta Parasitologica* 46(3): 186-193.
- Torcu Koç, H. & Erdoğan, Z. (2021). Anisakis spp. (Nematoda: Anisakidae) case in the small spotted dogfish (*Scyliorhinus canicula* (Linnaeus, 1758)) caught from the sea of Marmar (Turkey). *Balikesir Journal of Institute of Science and Technology*, 23(1): 65-71.
- Tous, P., Sidibé, A., Mbye, E., de Morais, L., Camara, Y.H., Adeofe, T.A., Munroe, T., Camara, K., Cissoko, K., Djiman, R., Sagna, A. & Sylla, M. (2015). *Sardina pilchardus*. *The IUCN Red List of Threatened Species* 2015: e.T198580A15542481. <https://dx.doi.org/10.2305/IUCN.UK.20154.RLTS.T198580A15542481.en>. Downloaded on 26 November 2020.
- Vidal-Martinez, V. M., Osorio-Sarabia, D. & Overstreet, R. M. (1994). Experimental infection of *Contracaecum multipapillatum* (Nematoda: Anisakinae) from Mexico in the domestic cat. *Journal of Parasitology*, 80: 576-579.
- Whithead, P. J. P., Bauchot, M. L., Hureau, J. C., Nilsen, J. & Tortonese, E. (1984-1986). Fishes of the Northeastern Atlantic and the Mediterranean. Paris, UNESCO, Vol. I-III, 1473 p.
- Williams, E. H. & Bunkley-Williams, L. (1996). Parasites of offshore big game fishes of Puerto Rico and the western Atlantic. Puerto Rico Department of Natural and Environmental Resources, San Juan, PR, and the University of Puerto Rico, Mayaguez, PR. 382 p.
- Yardımcı, B., Pekmezci, G. F. & Onuk, E. E. (2014). Pathology and molecular identification of *Anisakis pegreffii* (Nematoda: Anisakidae) infection in the John Dory, *Zeus faber* (Linnaeus, 1758) caught in Mediterranean Sea. *Ankara Journal of Veterinary*, 61: 233-236.
- Yetim, M. (1985). The Parasites found in the fish consuming in Eskişehir. MSc. Thesis. Anadolu University, Eskişehir, Turkey.
- Yoshinaga, T., Ogawa, K., & Wakabayashi, H. (1987a). Experimental life cycle of *Hysterothylacium aduncum* (Nematoda: Anisakidae) in fresh water. *Fish Pathology*, 22: 243-251.