

# Tocilizumab-induced anaphylaxis in two patients with COVID-19-induced cytokine storm

Emel Atayık, Gökhan Aytekin

Konya Training and Research Hospital Department of Allergy and Clinical Immunology, Konya, TURKEY

## Abstract

The severe acute respiratory syndrome coronavirus 2 (SARS-CoV-2) is a zoonotic virus which was first discovered in Wuhan, the People's Republic of China in December 2019 and has led to one of the greatest pandemics of world history in a short period of time<sup>1</sup>. SARS-CoV-2 is a rapidly spreading infectious disease with a high mortality rate. The disease has a moderate and severe course in approximately 20% of the patients and mortality reaches up to 62% among these patients<sup>2</sup>. The majority of the patients develop SARS-CoV-2-induced pneumonia and manifestations of pneumonia rapidly progress to respiratory failure. In severe Covid pneumonia, it has been demonstrated that increased plasma concentrations of cytokines including interleukin-6 (IL-6), tumor necrosis factor- $\alpha$  (TNF- $\alpha$ ), and IL-12 are involved in immune response and in cytokine storm caused by the increase in these cytokines lead to mortality<sup>1,3</sup>. Tocilizumab (TCZ) is a promising agent that is used for the treatment of cytokine storm. TCZ is an IgG1 class recombinant humanized monoclonal antibody against IL-6 receptor<sup>3</sup>. It has then been used for the treatment of rheumatic diseases. Due to its mechanism of action, TCZ treatment comes to the forefront particularly in cases of severe COVID-19-induced cytokine pneumonia presenting with cytokine storm<sup>3</sup>. However, potential IgE-mediated immunological reactions against this drug, especially anaphylaxis, may deprive these patients of an important treatment option for the treatment of COVID-19-induced cytokine storm. Although TCZ-induced anaphylaxis has been reported as case reports of indicated rheumatic diseases, TCZ-induced anaphylaxis has not yet been reported in patients using TCZ for SARS-CoV-2-induced cytokine storms<sup>4</sup>. In this case series, we aimed to represent cases of anaphylaxis which developed in two different patients using TCZ for SARS-CoV-2-induced cytokine storm.

**Key words:** anaphylaxis, COVID-19, cytokine storm, drug allergy, Tocilizumab

## Introduction

The severe acute respiratory syndrome coronavirus 2 (SARS-CoV-2) is a zoonotic virus which was first discovered in Wuhan, the People's Republic of China in December 2019 and has led to one of the greatest pandemics of world history in a short period of time<sup>1</sup>. SARS-CoV-2 is a rapidly spreading infectious disease with a high mortality rate. The disease has a moderate and severe course in approximately 20% of the patients and mortality reaches up to 62% among these patients<sup>2</sup>. The majority of the patients develop SARS-CoV-2-induced pneumonia and manifestations of pneumonia rapidly progress to respiratory failure. In severe Covid pneumonia, it has been demonstrated that increased plasma concentrations of cytokines including interleukin-6 (IL-6), tumor necrosis factor- $\alpha$  (TNF- $\alpha$ ), and IL-12 are involved in the inflammatory process and immune response and that the cytokine storm and macrophage activation syndrome caused by the increase in these cytokines lead to mortality<sup>1,3</sup>. Tocilizumab (TCZ) is a promising agent that is used for the treatment of cytokine storm. TCZ is an IgG1 class recombinant humanized monoclonal antibody against interleukin-6 (IL-6) receptor<sup>3</sup>. It has then been used for the treatment of rheumatic diseases including adult-onset Still's disease and systemic juvenile idiopathic arthritis. Due to its mechanism

of action, TCZ treatment comes to the forefront particularly in cases of severe COVID-19-induced cytokine pneumonia presenting with cytokine storm (macrophage activation syndrome)<sup>3</sup>. However, potential IgE-mediated immunological reactions against this drug, especially anaphylaxis, may deprive these patients of an important treatment option for the treatment of COVID-19-induced cytokine storm. Although TCZ-induced anaphylaxis has been reported in the literature as case reports of indicated rheumatic diseases, TCZ-induced anaphylaxis has not yet been reported in patients using TCZ for PCR positive COVID-19-induced cytokine storms<sup>4</sup>. In this case series, we aimed to represent cases of anaphylaxis which developed in two different patients using TCZ for COVID-19-induced cytokine storm.

## Case presentation

### Patient-1

A 48-year-old male patient admitted to the COVID outpatient clinic with complaints of fatigue, joint pain, and high temperature for 1 week. From his background, it was learned that he had a diagnosis with asthma for approximately 20 years. In laboratory tests of the patient, the SARS-CoV-2 PCR test was

**Corresponding Author:** Emel Atayık **e-mail:** emelakinci@yahoo.com

**Received:** 26/10/2020 • **Accepted:** 10/11/2020

**DOI:** 10.33706/jemcr.816161

©Copyright 2020 by Emergency Physicians Association of Turkey - Available online at www.jemcr.com

found to be positive and areas of diffuse ground-glass appearance consistent with COVID pneumonia were detected in his computed tomography (CT) of thorax, after which he was hospitalized (Figure-1). The patient has initiated treatment with hydroxychloroquine (2x200 mg, po, 5 days), favipiravir (loading dose of 2x 800 mg for the first day, 1x800 mg po for consecutive days, a total of 5 days), and anticoagulants (enoxaparin 1x0.6 ml, sc). In addition to the treatment of the patient with asthma, a long-acting beta-2 agonist (Formoterol 12 mcg 2x1, inhalator), inhaled steroids (Budesonide 2x800 mcg, inhalator), ipratropium bromide (4x100 mcg, inhalator) were added. Due to the refractory fever of the patient and detection of an increase in acute phase reactants including C-reactive protein (CRP), ferritin, and fibrinogen, the patient was considered to have COVID-19-induced cytokine storm and macrophage activation syndrome (MAS) and infusion of TCZ at a dose of 8 mg/kg every 12 hours were initiated. Laboratory results of the case are summarized in Table. The patient who described itching has no visible rash about 2 hours after initiation of the infusion. No additional pathologies or changes were observed on cardiac and respiratory system examinations. Pheniramine maleate at a dose of 1x45.5 mg was added to the treatment of the patient who described pruritus. The second infusion of TCZ was determined to be given 24 hours later. On day 2, about 5 minutes after initiation of the second infusion of TCZ, the patient developed shortness of breath, nausea, and a drop in blood pressure, followed by respiratory and cardiac arrest. The infusion was

immediately stopped and for anaphylaxis, intramuscular epinephrine at a dose of 1x0.3 mg, IV pheniramine maleate at a dose of 1x45.5 mg, methylprednisolone at a dose of 0.5 mg/kg/day, and ranitidine at a dose of 1x50 mg were administered. The patient became conscious after epinephrine treatment and cardiopulmonary resuscitation and his blood pressure were stabilized without requiring an additional vasopressor agent. As MAS of the patient carried on, initiation of intravenous immunoglobulin (IVIG) treatment was decided. The patient has initiated IVIG treatment at a dose of 0.5 mg/kg/day. No reaction was observed after IVIG treatment. A significant improvement was observed in clinical and laboratory findings of the patient who received IVIG treatment for 5 days.

## Patient-2

A 52-year-old female patient admitted to the COVID outpatient clinic with complaints of fatigue, diarrhea, shortness of breath, and high temperature for 3-4 days. In laboratory tests of the patient with no additional disease, the SARS-CoV-2 PCR test was found to be positive and areas of diffuse ground-glass appearance consistent with COVID pneumonia were detected in her computed tomography (CT) of thorax, after which she was hospitalized (Figure-2). The patient has initiated treatment with hydroxychloroquine (2x200 mg, po, 5 days), favipiravir

**Table 1.** Demographic and laboratory features of the patients

	Patient-1			Patient-2		
<b>Age, years</b>	52			48		
<b>Gender</b>	Male			Female		
<b>Infusion with reaction</b>	2 <sup>nd</sup> infusion			First infusion		
<b>Comorbidities</b>	Asthma			None		
<b>Anaphylaxis-associated symptoms/signs</b>	Urticarial skin rash, pruritus Nausea Dispnea Hypotension			Urticarial skin rash, pruritus Dispnea Hypotension		
	29.05.20	11.06.20	13.06.20	23.07.20	29.07.20	31.07.20
<b>White cell count, ×10<sup>9</sup> /L</b>	10.68	9.90	3.54	6.62	6.76	4.76
<b>Lymphocyte, %</b>	16.4	15.1	13.8	35.3	20.4	18.6
<b>Lymphocyte, mm<sup>3</sup></b>	1.61	1.62	490	1.68	1.26	1.07
<b>CRP, mg/L</b>	10.9	13.14	68.7	77.5	95.9	130
<b>D-dimer, ng/mL</b>	0.4	0.6	4.3	0.4	0.6	1
<b>Ferritin, ng/mL</b>	1225.1	1533.0	598.7	233.0	262.5	372.4
<b>Fibrinogen, g/L</b>	341.5	245.6	405	400	1000	1010
<b>Procalcitonin, ng/mL</b>	0.042	0.078	0.15	0.056	0.536	0.763

CRP: C-reactive protein

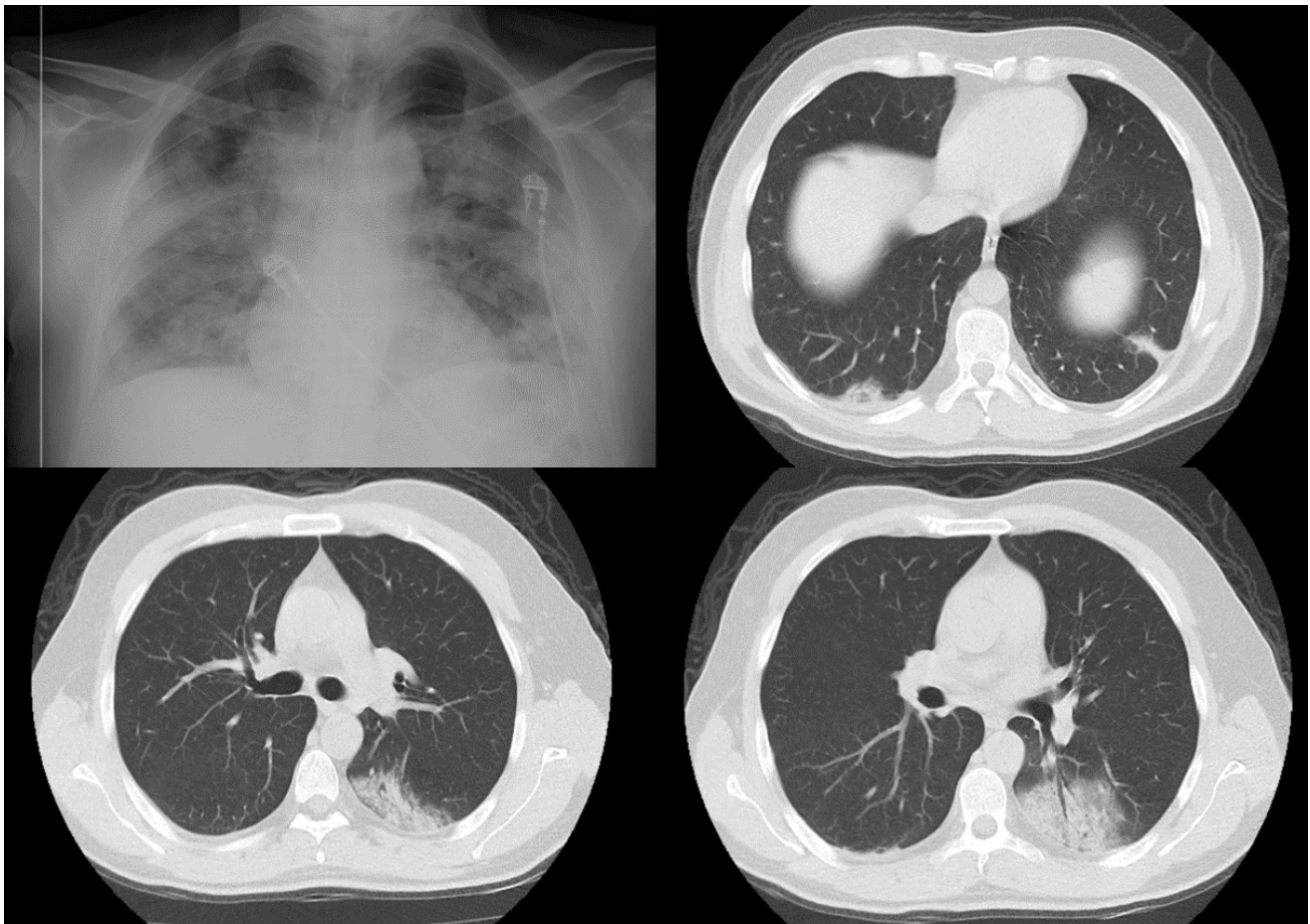
(loading dose of 2x 800 mg for the first day, 1x800 mg po for consecutive days, a total of 5 days), and anticoagulants (enoxaparin 1x0.6 ml, sc). Again, in this patient, the patient was considered to have COVID-19-induced cytokine storm and MAS, as during follow-up, she developed refractory fever, an increase in ferritin, CRP, and fibrinogen levels, and a gradual decrease in oxygen saturation (Table). The patient has initiated an infusion of tocilizumab at a dose of 8 mg/kg. Close to the end of the infusion, the patient who developed whole-body redness, diffuse rash, and worsening shortness of breath was considered to have a drug-induced allergy and the infusion was discontinued. The patient whose blood pressure was determined to be 76/43 was given intramuscular epinephrine at a dose of 1x0.3 mg, IV pheniramine maleate at a dose of 1x45.5 mg, methylprednisolone at a dose of 0.5 mg/kg/day, and ranitidine at a dose of 1x50 mg for anaphylaxis, as well as IV dopamine at a dose of 20 mcg/kg/min as an additional vasopressor agent. The patient whose shortness of breath relieved and became normotensive was considered to have TCZ-induced anaphylaxis. No TCZ treatment was planned for the future for the patient.

The patients whose complaints regarding SARS-CoV-2 and who improved in terms of clinical status, laboratory, and radiologically were discharged. Although the patients were referred to the Allergy outpatient clinic for confirmation of TCZ-induced reactions with skin tests, both of the patients refused to undergo skin testing.

## Discussion

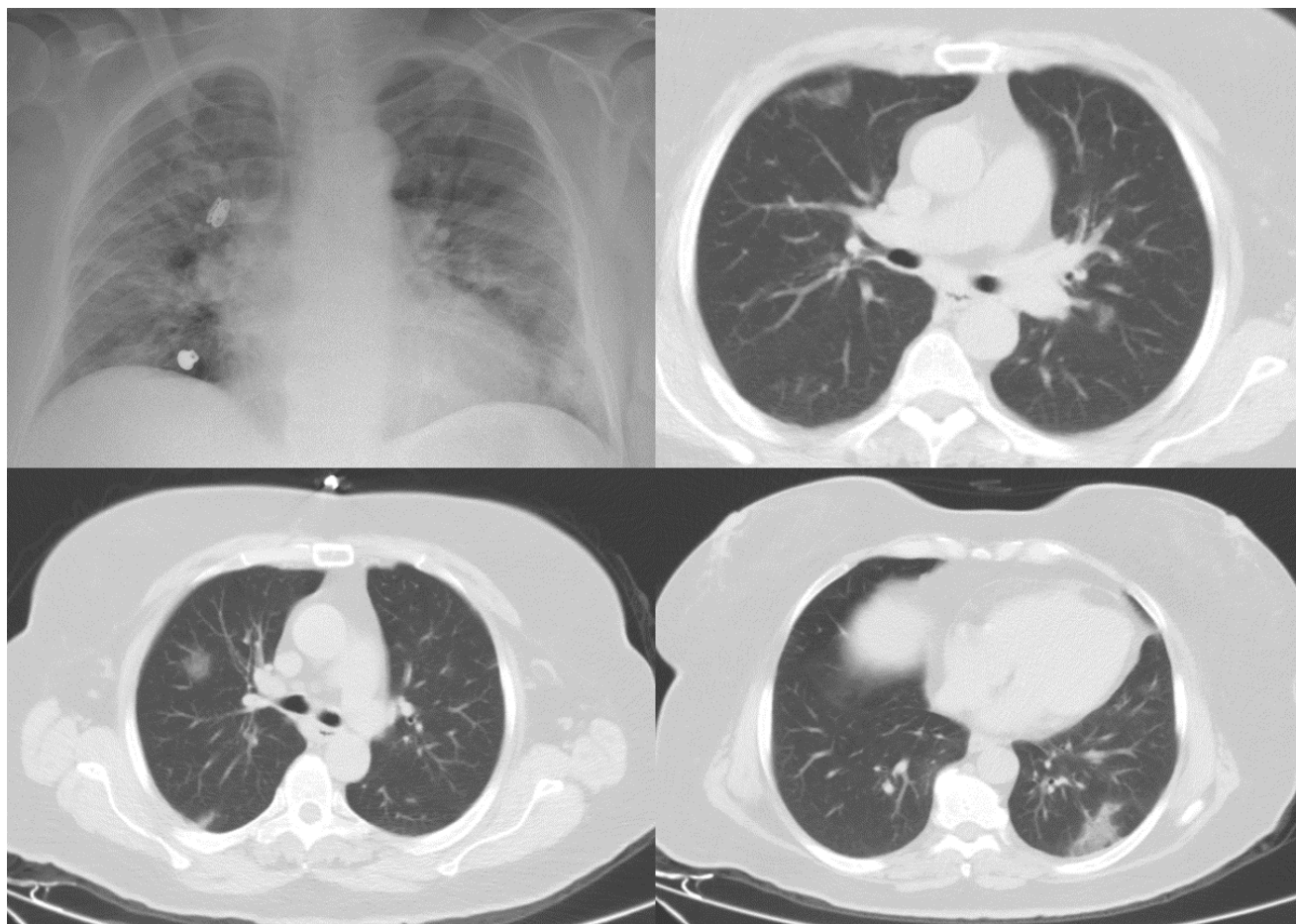
Anaphylaxis is a life-threatening multisystemic hypersensitivity reaction that suddenly occurs due to mediators released into systemic circulation by mast cells. In adults, drugs are one of the most common causes<sup>5</sup>. In this case series, we represented 2 cases presenting with clinical manifestations of anaphylaxis affecting mucocutaneous, respiratory, gastrointestinal, and cardiovascular systems who used TCZ for treatment of COVID-19-induced cytokine storm and MAS. Tocilizumab is a recombinant humanized anti-IL-6 receptor monoclonal antibody which inhibits IL-6 signal transduction and is usually well tolerated. Although TCZ-induced anaphylaxis has already been reported during treatment of various rheumatic diseases<sup>6,7</sup>, TCZ-induced anaphylaxis has not been reported in patients using TCZ for the treatment of COVID-19-induced cytokine storm and MAS. In regard to this, our cases are the first cases reported in the literature.

As in many other drugs, adverse reactions including TCZ-induced urticaria, erythroderma, cutaneous vasculitis, and anaphylaxis have already been reported in patients using TCZ<sup>8</sup>. Park et al. reported that severe infusion-induced reactions developed in 1.9% of patients with rheumatoid arthritis who were using TCZ<sup>6</sup>. Although TCZ-induced anaphylaxis develops after 2nd-5th infusions in the majority



**Figure-1:** Radiological findings of Patient-1





**Figure-2:** Radiological findings of Patient-2

of the patients, there are cases reporting that anaphylaxis developed during the first infusion of TCZ. While infusion-induced reactions that develop during the first infusion have been primarily associated with cytokine release, infusion-induced reactions that develop during 2nd and further infusions have been associated with type 1 hypersensitivity, complement activation, and anti-drug antibodies<sup>7</sup>. Yasuoka et al. reported younger patients, increased white blood cell count, and acute phase reactants as risk factors for TCZ-induced anaphylaxis<sup>9</sup>.

In the case of suspected TCZ-induced anaphylaxis, skin testing such as prick and intradermal tests can be used for direct demonstration of possible drug-specific IgE antibodies. Due to false negativity due to wasting of specific IgEs in blood and intensive degranulation by mast cells, it should be performed 4-6 weeks after the history of anaphylaxis<sup>10</sup>. In our case series, the patients refused to undergo skin testing for the diagnosis of TCZ-induced anaphylaxis. It is a limitation of our study. Treatment of TCZ-induced anaphylaxis in treatment of COVID-19-induced cytokine storm and MAS is not different from treatments of anaphylaxis caused by other reasons and intramuscular administration of adrenaline is the most important and primary treatment option in

this patient group as well [10]. Following rapid recognition of anaphylaxis and immediate discontinuation of the drug infusion in both patients, they responded to the intramuscular administration of adrenaline very well and their clinical condition rapidly improved.

In conclusion, TCZ-induced anaphylaxis may develop also in patients using TCZ for the treatment of COVID-19-induced cytokine storm and MAS. More extensive studies are needed in order to reveal risk factors for TCZ-induced anaphylaxis. Clinicians should be alert not only for current comorbidity of COVID-19 infection but also for TCZ-induced anaphylaxis and it should be remembered that epinephrine treatment is the most important and effective treatment option in TCZ-induced anaphylaxis, as in anaphylaxis caused by other reasons.

## References

1. Xu X, Han M, Li T, et al. Effective treatment of severe COVID-19 patients with tocilizumab. *Proc Natl Acad Sci U S A*. 2020 May 19;117(20):10970-10975. doi: 10.1073/pnas.2005615117. PubMed PMID: 32350134; PubMed Central PMCID: PMC7245089.

2. Zu ZY, Jiang MD, Xu PP, et al. Coronavirus Disease 2019 (COVID-19): A Perspective from China. *Radiology*. 2020 Aug;296(2):E15-E25. doi: 10.1148/radiol.2020200490. PubMed PMID: 32083985; PubMed Central PMCID: PMC7233368.
3. Qin C, Zhou L, Hu Z, et al. Dysregulation of Immune Response in Patients With Coronavirus 2019 (COVID-19) in Wuhan, China. *Clin Infect Dis*. 2020 Jul 28;71(15):762-768. doi: 10.1093/cid/ciaa248. PubMed PMID: 32161940; PubMed Central PMCID: PMC7108125.
4. Salmon JH, Perotin JM, Morel J, et al. Serious infusion-related reaction after rituximab, abatacept and tocilizumab in rheumatoid arthritis: prospective registry data. *Rheumatology (Oxford, England)*. 2018 Jan 1;57(1):134-139. doi: 10.1093/rheumatology/kex403. PubMed PMID: 29069471; eng.
5. Worm M, Eckermann O, Dolle S, et al. Triggers and treatment of anaphylaxis: an analysis of 4,000 cases from Germany, Austria and Switzerland. *Dtsch Arztebl Int*. 2014 May 23;111(21):367-75. doi: 10.3238/arztebl.2014.0367. PubMed PMID: 24939374; PubMed Central PMCID: PMC4075276.
6. Park EH, Lee EY, Shin K, et al. Tocilizumab-induced anaphylaxis in patients with adult-onset Still's disease and systemic juvenile idiopathic arthritis: a case-based review. *Rheumatology international*. 2020 May;40(5):791-798. doi: 10.1007/s00296-019-04456-9. PubMed PMID: 31598752.
7. Salmon JH, Perotin JM, Morel J, et al. Serious infusion-related reaction after rituximab, abatacept and tocilizumab in rheumatoid arthritis: prospective registry data. *Rheumatology (Oxford, England)*. 2018 Jan 1;57(1):134-139. doi: 10.1093/rheumatology/kex403. PubMed PMID: 29069471.
8. Tetu P, Hamelin A, Moguelet P, et al. Management of hypersensitivity reactions to Tocilizumab. *Clin Exp Allergy*. 2018 Jun;48(6):749-752. doi: 10.1111/cea.13142. PubMed PMID: 29603809.
9. Yasuoka R, Iwata N, Abe N, et al. Risk factors for hypersensitivity reactions to tocilizumab introduction in systemic juvenile idiopathic arthritis. *Mod Rheumatol*. 2019 Mar;29(2):324-327. doi: 10.1080/14397595.2018.1457490. PubMed PMID: 29578355.
10. Galvao VR, Castells MC. Hypersensitivity to biological agents—updated diagnosis, management, and treatment. *J Allergy Clin Immunol Pract*. 2015 Mar-Apr;3(2):175-85; quiz 186. doi: 10.1016/j.jaip.2014.12.006. PubMed PMID: 25754718.