



## A Rare Congenital Anomaly: Surgery of Combined Discrete Subaortic Membrane Complicated by the Absence of the Superior Vena Cava

Onur Isık<sup>1</sup>, Olcay Murat Disli<sup>2</sup>, Tolga Bas<sup>1</sup>, Ali Kutsal<sup>1</sup>

<sup>1</sup>Dr. Sami Ulus Maternity and Children's Research and Education Hospital, Department of Cardiovascular Surgery, Ankara, Turkey

<sup>2</sup>Inonu University, Turgut Ozal Medical Center, Department of Cardiovascular Surgery, Malatya, Turkey

### Abstract

Persistent left superior vena cava accompanied by an absent right superior vena cava in viscerotrial situs solitus is an extremely rare congenital anomaly. Although absence of RSVC alone in patients with viscerotrial situs solitus is of no hemodynamic significance, its diagnosis before surgery or other invasive procedure is important to avoid various management difficulties, which include complications such as the implantation of a transvenous pacemaker or defibrillator, placement of pulmonary artery catheter for intraoperative or intensive care unit monitoring, systemic venous cannulation for cardiopulmonary bypass or extracorporeal circulation, cavopulmonary anastomosis, and orthotopic heart transplantation. We present a case with the absence of RSVC along with PLSVC in association with a discrete subaortic membrane, at the end of which the patient was operated successfully.

**Key Words:** Superior Vena Cava; Systemic Venous Return Anomaly; Discrete Subaortic Stenosis; Cardiovascular Surgery.

### Superior Vena Cava Yokluğu ile Birlikte Diskret Subaortik Membran Cerrahisi: Nadir Bir Konjenital Anomali

### Özet

Persistan sol süperior vena kavanın sağ vena cava süperior yokluğuyla beraberliği viseroatriyal situs solituslu hastalarda oldukça nadir gözlenen bir konjenital anomalidir. Bu anomalinin herhangi bir klinik semptomu olmamasına karşın, cerrahi ve diğer invazif prosedürler öncesi tanı konması, transvenöz pacemaker veya defibrilatör yerleştirilmesi, intraoperatif yada monitarizasyon için postoperatif pulmoner arter kateteri yerleştirilmesi, ekstrakorporeal sirkülasyon veya kardiyopulmoner bypass için sistemik venöz kanülasyon, kavapulmoner anastomoz ve ortotopik kalp transplantasyonunu içeren bir çok durumda yönetim zorluklarından kaçınmak için önemlidir. Biz bu makalede süperior vena cava yokluğu, persistan sol süperior vena cava ile diskret subaortik membran birlikteliği bulunan ve başarılı cerrahi uygulanan bir hastamızı sunduk.

**Anahtar Kelimeler:** Süperior Vena Cava; Sistemik Venöz Dönüş Anomalisi; Diskret Subaortik Stenoz; Kalpdamar Cerrahisi.

## INTRODUCTION

Combined discrete subaortic membrane complicated by persistent left superior vena cava (PLSVC) with absent right superior vena cava (RSVC) in viscerotrial situs solitus is a rarely observed anomaly with significant implications for interventional procedures used in cardiovascular surgery. Diagnosis of this condition is important for avoiding any potential complications during surgery. In this paper, we present a case of discrete subaortic membrane accompanied by a PLSVC with absent RSVC.

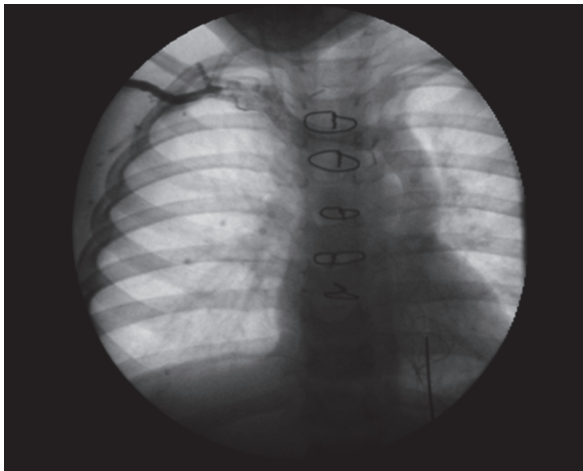
## CASE REPORT

A two-year-old girl with a history of chest pain was admitted to our clinic. Clinical examination of the patient suggested the presence of aortic stenosis. The patient's ECG was normal, except for a left axis deviation. Echocardiography identified a discrete subaortic membrane (DSM) and first degree aortic regurgitation. Angiography further revealed a discrete subaortic

membrane with 50mmHg gradient, along with minimal aortic regurgitation. The patient's clinical examinations and laboratory tests showed no further abnormal findings. Finally, a surgical resection of the DSM with cardiopulmonary bypass was planned.

A median sternotomy was performed during the bypass surgery. After the aortic cannulation, the superior vena cava could not be cannulated through the right atrial appendix. Attempting to localize and dissect the RSVC, it was noted to be absent. The PLSVC was present in its usual location, anterior to the left superior pulmonary vein. The previously placed central venous catheter was in the innominate vein. Thus, a cardiopulmonary bypass was performed on the patient by using the aortic, innominate vein, and inferior vena cava cannulations. Following this, a right atriotomy was then performed on the patient. During the procedure, a dilated coronary sinus was identified, and no ostium was observed at the location where the RSVC would normally be found. A horizontal aortotomy incision was performed, and the subvalvular membrane was resected. The surgery was completed without any complications.

The patient had an uneventful recovery during the postoperative period. On the third postoperative day, an angiogram was performed on the child through the central venous catheter in the right internal jugular vein, which demonstrated the absence of the RSVC, and a dilated left SVC draining to the coronary sinus (Figure 1). The patient was discharged on the fifth postoperative day. No symptoms or complications were observed at her latest follow-up.



**Figure 1.** Angiogram showing absent right SVC

## DISCUSSION

PLSVC with RSVC in visceratrial situs solitus is a rarely observed congenital anomaly. Although it lacks any discernable clinical symptoms, this anomaly has significant implications for cardiovascular surgery and the implantation of pacemakers and defibrillators. In fact, this anomaly is generally identified during the application of complicated cardiovascular surgery procedures (1).

Previous studies have described many variations in the structure of superior systemic veins. The most commonly reported anomalies are double superior vena cava and PLSVCs. The incidence of these anomalies is reported to be 0.3% among the general population. Their incidence is slightly higher among patients with congenital heart disease (2).

Persistent left superior vena cava is observed in 3-10% of cases with congenital heart malformations. Among various types of heart malformations, PLSVC complicated by absent RSVC in visceratrial situs solitus is observed in only 1% of cases with PLSVC, in 0.09% of autopsied cases with congenital heart disease, and in 0.07% of cases that underwent intravenous pacemaker implantation (3).

In a study by Bartram et al. examining 121 patients with PLSVC and absent RSVC, it was demonstrated that 56 (46%) of the patients had heart malformations. The most common of these malformations were atrial septal defects (16%), endocardial cushion defects (11%) and

Fallot's tetralogies (9%). However, most of these patients (n=65, 54%) did not have any heart malformations, which illustrates that PLSVC with absent RSVC is not necessarily accompanied by other concomitant malformations (4).

Although PLSVC with absent RSVC is generally unnoticed, this anomaly can lead to complications during cardiovascular procedures such as the placement of pulmonary artery catheters, implantation of transvenous pacemaker or defibrillator leads, systemic venous cannulation for cardiopulmonary bypass or extracorporeal circulation, cavopulmonary anastomosis, and orthotopic heart transplantation (5, 6, 7). Possible complications that might occur in cases with this anomaly during surgery include the insertion of a blood draining cannula, or the intravenous insertion of a transvenous pacemaker lead.

There are two ways by which a cannula can be inserted into the PLSVC: either the direct insertion of an L-shaped cannula into the PLSVC through the coronary sinuses; or, alternatively, a cannulation on the innominate vein. In cases with complicated PLSVC by the absence of RSVC, the pacemaker near the coronary sinus will be more active due to the dysfunction in the sinus node, which will cause the coronary sinus rhythm to become more dominant. Venting through the coronary sinus to preserve the sinus rhythm is not a suitable approach, since a small surgical area of the right atrium might be blocked in pediatric patients. Furthermore, the technique based on directly cannulating the PLSVC has been associated with thrombogenesis, restriction of the cannula size, and phrenic nerve injury. Thus, it appears that cannulating the innominate vein is the safest approach; and this was technique we employed for our case (8).

Rhythm abnormalities such as sinoatrial (SA) node dysfunction, heart block, and ventricular tachycardia have been observed concomitantly with this anomaly. SA node dysfunction is possibly a consequence of this anomaly. Besides, abnormalities of the conduction system, such as the ones observed in the SA node, the atrioventricular node and the His bundle, may be associated the dilated coronary sinus observed with PLSVC. Although these rhythm abnormalities are not necessarily related to PLSVCs, careful identification and management of certain types of arrhythmias during perioperative assessment might be necessary (9).

As PLSVC with absent RSVC has significant implications for cardiovascular surgery, prior assessments for determining whether RSVC is absent should be performed in cases suspected with PLSVC. Cardiovascular surgeons must be knowledgeable regarding the main conduction pathway of the coronary sinus and the position of the left phrenic nerve position. For these reasons, we concluded that the innominate vein cannulation is the safest cannulation site for patients who have PLSVC with absent RSVC.

## REFERENCES

1. Kurisu K, Ochiai Y, Kumeda H, Kimura S, Tanaka K, Tominaga R. Coronary artery bypass grafting with Absent right superior vena cava in visceratrial situs solitus. *Jpn J Thorac Cardiovasc Surg* 2004;52:191-3.
2. Akai H, Noda M, Sugiyama S, Gotou N, Shirouzu I, Machida T. Congenital absence of superior vena cava associated with high position of aortic arch. *E J. Radiol Extra* 2006;59:81-3.
3. Sato Y, Yokoyama H, Watanabe M, Hamada O. A Surgical Case of Combined Valvular Disease Complicated by Absent Right Superior Vena Cava and Persistent Left Superior Vena Cava *Ann Thorac Cardiovasc Surg* 2003;9:401-5.
4. Bartram U, Van Praagh S, Levine JC, Hines M, Bensky AS, Van Praagh R. Absent right superior vena cava in visceratrial situs Solitus. *Am J Cardiol* 1997;80:175-83.
5. Menendez B, Garcia del Valle S, Marcos RC, Azofra J, Gomez-Arnau J. Left superior vena cava: A vascular abnormality discovered following pulmonary artery catheterization. *Can J Anaesth* 1996;43:626-8.
6. Mooney DP, Snyder CL, Holder TM. An absent right and persistent left superior vena cava in an infant requiring extracorporeal membrane oxygenation therapy. *J Pediatr Surg* 1993;28:1633-4.
7. Neema PK, Manikandan S, Rathod RC. Absent right superior Vena Cava and Persistent Left Superior Vena Cava: The Perioperative Implications. *International Anaesthesia Research Society* 2007;105(1):40-2
8. Bernardis C, Chatzis A, Treasure T. Absence of the right superior caval vein associated with disease of the sinus node. *Int J Cardiol* 1992;36:115-7.
9. Morgan DR, Hanratty CG, Dixon LJ, Trimble M, O'Keeffe DB. Anomalies of cardiac venous drainage associated with abnormalities of cardiac conduction system. *Europace*. 2002;4(3):281-7

Received/Başvuru: 23.07.2013, Accepted/Kabul: 25.09.2013

### Correspondence/İletişim

**Olçay Murat DİŞLİ**  
Inonu University, Turgut Ozal Medical Center, Department of Cardiovascular Surgery, MALATYA, TURKEY  
E-mail: olcay.disli@inonu.edu.tr



### For citing/Atf için

**Isik O, Disli OM, Bas T, Kutsal A. A rare congenital anomaly: surgery of combined discrete subaortic membrane complicated by the absence of the superior vena cava. J Turgut Ozal Med Cent 2014;21:139-41 DOI:**