

## Case of Malleable Penile Prosthesis Fracture Possibly Due to Wrong Surgical Technique

Fatih Oğuz<sup>1</sup>, Ahmet Soylu<sup>2</sup>, Ramazan Altıntaş<sup>1</sup>, Ali Beytur<sup>1</sup>, Aliseydi Bozkurt<sup>3</sup>

<sup>1</sup>Inonu University School of Medicine, Department of Urology, Malatya, Türkiye

<sup>2</sup>Private Gozde Hospital, Department of Urology, Malatya, Türkiye

<sup>3</sup>Erzincan University School of Medicine, Department of Urology, Türkiye

### Abstract

Mechanical fracture is an unusual complication of malleable penile prosthesis. In the present case, we reported that a 29-year-old man, using the AMS 650 malleable penile prosthesis since 2004, was presented. The patient described that there was deformity at the right side of the penis. Pain and difficulty during sexual intercourse was described. Right root of the penile prosthesis was found to be fractured in the physical examination and then it was removed by surgical exploration. It was determined that the right root of the penile prosthesis was misplaced on front-backward plane. A new AMS 650 malleable penile prosthesis was implanted. Because of previous prosthesis was shorter than needed, a new prosthesis was used 3 cm longer than the previous. The patient was discharged a day after the operation without any complication.

**Key Words:** Penile Prosthesis; Mechanical Fracture; Surgically Misplacement.

**Yanış Cerrahi Uygulama Nedeniyle Malleable Penil Protezin Kırılması: Olgu Sunumu**

### Özet

Malleable penil protezin mekanik olarak kırılması çok nadir görülen ve beklenmedik bir komplikasyondur. Burada 2004 yılından beri komplikasyonsuz AMS 650 malleable penil protez kullanan 29 yaşında bir erkek hasta sunuldu. Hasta penis sağ yan kısımda deformite, cinsel ilişkide ağrı ve güçlük şikayeti ile başvurdu. Fizik muayenede penil protezin sağ kolunun kırık olduğu tespit edildi. Penil protez cerrahi işlemle çıkarıldı. Penil protezin sağ kolunun ön-arka düzlemde yanlış yerleştirilmiş olduğu fark edildi. Hastaya yeni AMS 650 malleable penil protez takıldı. Çıkarılan protez gereğinden daha kısa olduğu için yeni takılan protez 3 cm daha uzundu. Hastada hiçbir komplikasyon olmaksızın ameliyat sonrası gün taburcu edildi.

**Anahtar Kelimeler:** Penil Protez; Mekanik Fraktür; Cerrahi Yerleşim Kusurları.

## INTRODUCTION

Penile prosthesis is a functional option that provides artificial erection, satisfactory for sexual intercourse. It will be particularly beneficial for the patient experiencing failure in medical and intracavernosal therapies. Malleable penile prosthesis is a good alternative for many patients due to high technical success rates, high long-term mechanical reliability, and good patient and partner satisfaction rates (1).

Although penile prosthesis can be implanted in a simple surgery, sometimes, it can be tricky when complications arise. For malleable implants, mechanical failure due to the fracture of the prosthesis is a rare complication of penile prosthesis. In this case, we reported a 29 years old male patient with root fracture of the malleable penile prosthesis, as a result of misplacement of the prosthesis in the implantation surgery.

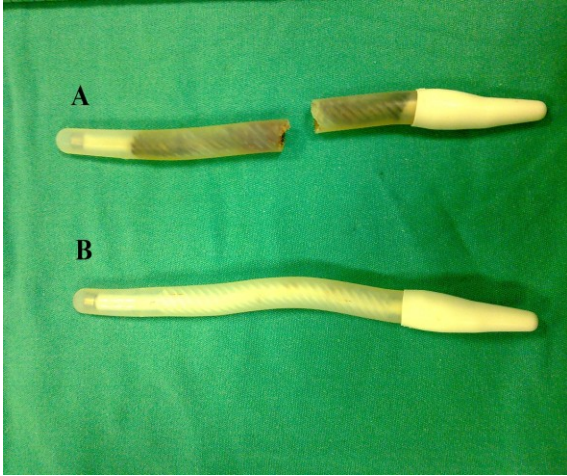
## CASE REPORT

A 29-year-old male with impotence secondary to diabetes mellitus underwent implantation of AMS 650

malleable penile prosthesis via a subglandular approach eight years ago. In November 2011, he noticed a pain on his penis and penile deformity after sexual intercourse. The patient was admitted to our clinic with those complaints and denied trauma to the penis or abnormal use. The right root of the penile prosthesis was found to be broken during physical examination. There was minimal local tenderness and minimal ecchymosis but no swelling.

On surgical exploration, both roots of penile prosthesis were removed (Figure 1), and we noticed that each root of penile prosthesis was misplaced in implantation surgery.

The patient wanted a new prosthesis and, we implanted a new AMS 650 malleable penile prosthesis. The new prosthesis was 3 cm longer than previous, because previous was shorter than needed. He was discharged one day after the surgery. He declared that there were no complications after the third week of the surgery.



**Figure 1** A. Completely fractured right rod of the penile prosthesis 1 B. Intact left rod of the penile prosthesis

### DISCUSSION

The AMS malleable penile prosthesis consists of a single-piece pair of tapered silicone elastomer roots. There are stainless-steel wire bundles with stainless-steel end caps and they are covered with a synthetic braid within prosthesis. To increase durability for breakage, steel wires are wrapped in synthetic material (2).

The prosthesis implantation has several complications, either intraoperative or postoperative. Intraoperative complications consist of perforation of the tunica albuginea and urethral damage (3). Postoperative complications consist of wound hematomas, superficial wound infections, prosthesis infection, mechanical failure, protrusion, erosion and deformity of the penis (4-7).

Mechanical failure due to root fracture is a rare problem of AMS malleable penile prosthesis. Until now, only one case was reported in the literature and it was indicated that the cause of root fracture was not clear (8). In the present case, we detected that the right root of the prosthesis was fractured most likely due to misplacement or/and shortness of prosthesis at implantation surgery. This malposition possibility caused instability on the prosthesis, and this situation led to breakage. We believe that this complication would not have occurred, if it were implanted properly. Therefore, penile prosthesis implantation should be performed by experienced surgeons to achieve benefit and long use during life.

### REFERENCES

1. Wespes E, Amar E, Hatzichristou D, Hatzimouratidis K, Montorsi F, Pryor J et al. EAU Guidelines on erectile dysfunction: an update. *Eur Urol* 2006;80:6-15.
2. T. Dorflinger, R. Bruskewitz. AMS malleable penile prosthesis. *Urology* 1986;28:480-5.
3. Sadeghi-Nejad H. Penile prosthesis surgery: a review of prosthetic devices and associated complications. *J Sex Med* 2007;4:296-309.
4. Droggin D, Shabsigh R, Anastasiadis AG. Antibiotic coating reduces penile prosthesis infection. *J Sex Med* 2005;2:565-8.
5. Bishop JR, Mod JW, Sihelnik SA, Peppas DS, Gormley TS, McLeod DG. Use of glycosylated hemoglobin to identify diabetics at high risk for penile periprosthetic infections. *J Urol* 1992;147:386-8.
6. Brown ET, Saunders SE, Zaslau S. Penile prosthesis pump tubing erosion into urethra appearing as inability to catheterize: a case report. *J Sex Med* 2008;5:2960-2.
7. Wilson SK, Cleves MA, Delk 2nd JR. Ultrex cylinders. Problems with uncontrolled lengthening (the S-shaped deformity). *J Urol* 1996;155:35-7.
8. Akand M, Ozayar A, Yaman Ö, Demirel C. Mechanical failure with malleable penile prosthesis. *Urology* 2007;70:1007.

Received/Başvuru: 21.01.2013, Accepted/Kabul: 05.03.2013

### Correspondence/İletişim

Fatih OĞUZ  
İnönü Üniversitesi Tıp Fakültesi, Üroloji Anabilim Dalı,  
MALATYA,  
E-mail: drfoguz@gmail.com

### For citing/Atıf için:

Oguz F, Soylu A, Altintas R, Beytur A, Bozkurt A. A case of malleable penile prosthesis fracture possibly due to wrong surgical technique. *J Turgut Ozal Med Cent* 2013;20(3):260-261 DOI: 10.7247/jtomc.20.3.14