



## An Unusual Infection of *Chryseomonas luteola*: Infective Endocarditis in a Patient with Ventricular Septal Defect

Gülây Yetkin\*, Mehmet Refik Bayraktar\*, Nasir Sivri\*\*, Feridun Kosar\*\*

\*İnönü University Faculty of Medicine, Department of Clinical Microbiology, Malatya, Turkey

\*\* İnönü University Faculty of Medicine, Department of Cardiology, Malatya, Turkey

*Chryseomonas luteola* has been recognized as an uncommon cause of bacteremia and infections in patients with underlying diseases or in association with foreign body. We presented an infective endocarditis in a patient with ventricular septal defect due to *C. luteola* in the absence of known risk factors.

**Key Words:** *Chryseomonas luteola*, Ventricular septal defect

**Ventriküler Septal Defekti Olan Hastada *Chryseomonas luteola* İle Oluşan İnfektif Endokardit:Vaka Sunumu**

*Chryseomonas luteola*: altta yatan bir hastalığı olan veya vücutta yabancı cisimle bağlantılı infeksiyonlara ve bakteriyemiye neden olan nadir etken mikroorganizmalardandır. Biz burada ventriküler septal defekti olan ve bilinen risk faktörlerinin herhangi birisini taşımayan hastada gelişen *Chryseomonas luteola* endokarditini sunduk.

**Anhatar Kelimeler:** *Chryseomonas luteola*, Ventriküler septal defekt

*Chryseomonas luteola* or *Pseudomonas luteola* formerly classified as CDC group Ve-1 is rarely described as a human pathogen. It has been recognized as an uncommon cause of bacteremia and infections in patients with underlying medical problems and in association with foreign materials such as catheters or prostheses.<sup>1,2</sup>

Congenital heart disease may be substrate for infective endocarditis in 10 to 20 percent of younger adults and 8 percent of older adults.<sup>3</sup> Among adults the predisposing risks are patent ductus arteriosus, ventricular septal defect, and bicuspid aortic valve.<sup>4,5</sup> We presented here in a patient with ventricular septal defect complicated with infective endocarditis due to *C. luteola*.

### CASE REPORT

Twenty one year old man was admitted to the hospital with the complaints of fever and dyspnea lasting for several weeks. On physical examination, the patient appeared to be in poor condition, weak and pale. His body temperature was 38.2 °C; blood pressure, 110/60 mmHg; pulse rate, 100 beats/min; and respiratory rate, 27/min. A systolic thrill was palpated in the precordial area. On auscultation, there was grade 4/6 systolic murmur at the left sternal border. There was no other physical finding. The chest radiograph showed an enlarged heart shadow and increased bronchovascular appearance. The electrocardiogram indicated sinus tachycardia and left ventricular hypertrophy. Laboratory studies yielded the following results: white blood cell count,  $15.6 \times 10^9/L$ ; neutrophils, 80%; hemoglobin, 11.39 g/dL; and erythrocyte sedimentation rate (ESR), 112 mm/h and C-reactive protein (CRP) 70mg/dL. Transthoracic echocardiography revealed a perimembranous ventricular septal defect and two small vegetations (0.5x.6cm and 0.4x0.6 cm in size) at the right side of the ventricular septal defect attached to the septal leaflet of the tricuspid valve (figure 1). There was no valvular pathology other than mild to moderate tricuspid regurgitation on transthoracic echocardiography. Before initiating an empirical therapy with combination of ampicillin and gentamisin, three sets of blood samples were cultured on BACTEC 9120 blood culturing system (Becton Dickinson Diagnostic Instrument, USA) and all of them gave positive signals within 24 hours. Growth appeared aerobically in human blood agar and chocolate agar at 37°C as dry yellow-orange tiny colonies after 24

hours that became more apparent after 48 hours incubation. The organism was gram-negative motile rod, oxidase-negative, esculin-positive and appeared as non-fermenter on triple sugar iron medium. It was identified as *C. luteola* (99.6%) by API 20 NE kit (bioMerieux, Marcy-1' Etiole, France). Susceptibility test to a range of antimicrobial disks (Oxoid, Basingstoke, Hampshire, England) was performed by a Kirby-Bauer disk diffusion method.<sup>6</sup> The organism was found to be resistant to ampicillin but susceptible to gentamicin, tobramisin, piperacillin, ceftriaxone, ceftazidime, cefuroxime, cefoperazon-sulbactam, meropenem, aztreonam, trimethoprim-sulfamethoxazole, and ciprofloxacin. *Chryseomonas luteola* was isolated and antibiotic treatment was changed to ceftazidime and gentamicin. On the third day of treatment, fever disappeared. Two weeks after hospitalization, CRP and ESR levels were returned to normal values and control blood cultures yielded no growth. In echocardiographic evaluation, a clear decrease in vegetation size was demonstrated. At the end of the 1-month of post antibiotic treatment, the patient underwent a successful operation in patch closure and tricuspid valve repair. The patient was completely recovered and vegetation on heart was disappeared. Subsequent blood cultures were negative.

## DISCUSSION

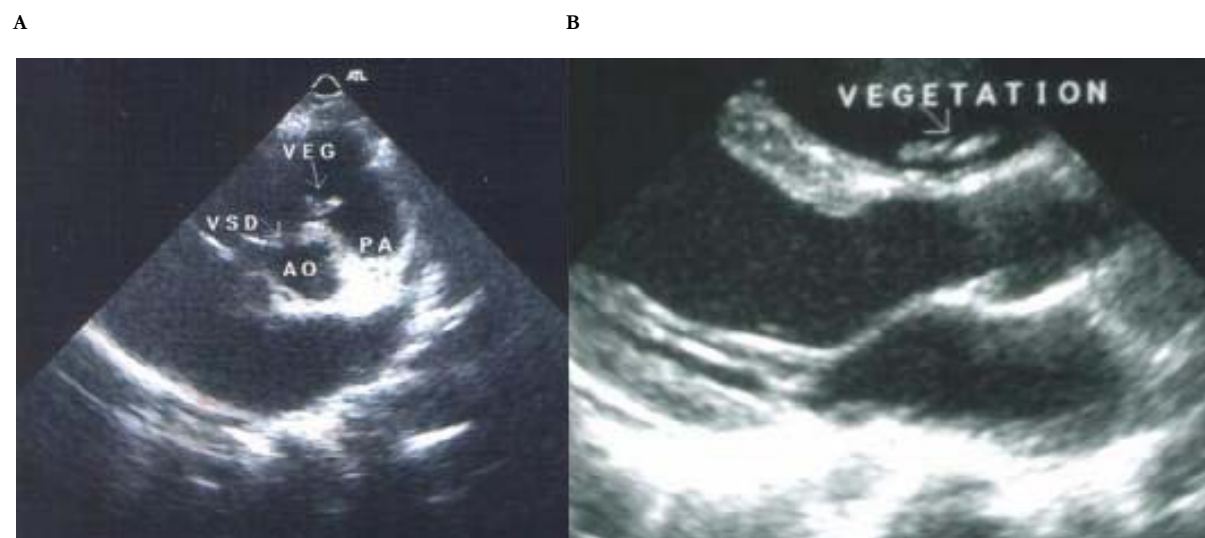
*Pseudomonas* has recently been classified as species in the genus. *Chryseomonas luteola*.<sup>3</sup> Although *C. luteola* belongs to bacteria normally found in soil and water environments, it is uncommonly isolated from either

human or animals. Sporadic reports have revealed that the saprophyte *C. luteola* is a rare human pathogen implicated in a number of cases of bacteremia, peritonitis and wound infections, usually in association with indwelling catheters or prostheses.<sup>7-13</sup> Leg ulcer due to *C. luteola* in a patients with sickle cell disease and fascial cellulitis due to *C. luteola* in an otherwise healthy people have also been reported.<sup>14,15</sup>

There is only one case of infective endocarditis caused by *C. luteola* in the literature. This case has been reported in a patient with prosthetic heart valve.<sup>16</sup> This is apparently the first case of infective endocarditis in a patient with ventricular septal defect due to *C. luteola*. Although ventricular septal defect may be predisposing factor for *C. luteola* infective endocarditis, the source of bacteremia was unclear. Our patient had none of the risk factors known such as indwelling catheters, wound, or prosthesis. The outcome of infection caused by *C. luteola* is usually good. The organism is generally resistant to first and second generation cephalosporins, but sensitive to third generation cephalosporins, aminoglycosides, ureidopenicillins and quinolones,<sup>17</sup> with variable sensitivity to ampicillin and tetracycline. Our isolate was susceptible to the all antibiotics except ampicillin.

This case implies that *C. luteola* can cause infective endocarditis in patients with ventricular septal defect as well as other cardiac pathology in the absence of the known risk factors for *C. luteola*, so the source of *C. luteola* infection is not merely depended on them.

**Figure-I. A :** Parasternal short axis view of the ventricular septal defect and vegetation. VSD: Ventricular septal defect, AO: Aorta, PA: Pulmonary artery, VEG: Vegetation. **B:** Parasternal long axis view of the two small vegetations in right side of the interventricular septum.



## An Unusual Infection of *Chryseomonas luteola*: Infective Endocarditis in a Patient with Ventricular Septal Defect

### REFERENCES

1. Gilardi GL, Hirschl S, Mandel M. Characteristics of yellow-pigmented nonfermentative bacilli (groups Ve-1 and Ve-2) encountered in clinical bacteriology. *J Clin Microbiol* 1975;1:384-9.
2. Kodama K, Kimura N, Komagata K. Two new species of *Chryseomonas*: *C. oryzihabitans* isolated from rice paddy and clinical specimens and *C. luteola* isolated from clinical specimens. *Int J Syst Bacteriol* 1985;35:467-74.
3. Kiska DL, Gilligan PH. *Chryseomonas*. In Murray PR, Baron EJO, Pfaller MA, Tenover FC, Tenover RH, editors. *Manual of Clinical Microbiology*, 7th Edition, Washington DC: American Society for Microbiology 1999:517-25.
4. Hogevik H, Olaison L, Andersson R, et al. Epidemiological aspects of infective endocarditis in urban population: A five year prospective study. *Medicine* 1995;74:324-39.
5. Sandre RM, Shafran SD. 1996. Infective endocarditis: Review of 135 cases over 9 years. *Clin Infect Dis* 1996;22:276-86.
6. National Committee for Clinical Laboratory Standards (NCCLS). *Methods for Dilution Antimicrobial Susceptibility Tests for Bacteria that Grow Aerobically*. Approved Standard M7-A5. Wayne PA. 2000.
7. Berger SA, Siegman-Igra Y, Stadler J, Campus A. Group VE-1 septicemia. *J Clin Microbiol* 1983;17: 926-7.
8. Connor BJ, Kopecky RT, Frymoyer PA, Forbes BA. Recurrent *Chryseomonas luteola* (CDC Group Ve-1) peritonitis in a patient undergoing continuous ambulatory peritoneal dialysis. *J Clin Microbiol* 1987;25:1113-4.
9. Engel JM, Alexander FS, Pachucki CT. Bacteremia caused by CDC group Ve-1 in previously healthy patient with granulomatous hepatitis. *J Clin Microbiol* 1987;25, 2023-4.
10. Freney J, Hansen W, Etienne J, Vandenesch F, Fleurette J. Postoperative infant septicemia caused by *Chryseomonas luteola* (CDC Group Ve-1) and *Chryseomonas oryzihabitans* (CDC Group Ve-2). *J Clin Microbiol* 1988;26:1241-3.
11. Ghosh, SK. A rare infection caused by *Chryseomonas luteola*. *J Infect* 2000;41:109-10.
12. Hawkins RE, Moriarty RA, Lewis DE, Oldfield EC. Serious infections involving the CDC group Ve bacteria *Chryseomonas luteola* and *Flavimonas oryzihabitans*. *Rev Infect Dis* 1991;13:257-60.
13. Kostman JR, Solomon F, Fekete T. Infection with *Chryseomonas luteola* (CDC group Ve-1) and *Flavimonas oryzihabitans* (CDC group Ve-2) in neurosurgical patients. *Rev Infect Dis* 1991;13:233-36.
14. Rastogi, S, Sperber SJ. Facial cellulitis and *Chryseomonas luteola* bacteremia in an otherwise healthy patient. *Diagn Microbiol Infect Dis* 1998;32:303-5.
15. Tsakris A, Hassapopoulou H, Skoura HI, Pournarase S, Doubovasc J. Leg ulcer due to *Pseudomonas luteola* in a patient with sickle cell Disease. *Diagn Microbiol Infect Dis* 2002;42:141-3.
16. O'Leary T, Fong IW. Prosthetic valve endocarditis caused by Group Ve-1 bacteria. *J Clin Microbiol* 1984;20:995.
17. Fass RJ, Barnishan J. In vitro susceptibilities of nonfermentative gram negative bacilli other than *Chryseomonas aeruginosa* to 32 antimicrobial agents. *Rev Infect Dis* 1980;2:841-53.

### For Correspondence:

Dr.Gülay Yetkin  
Inonu University Faculty of Medicine,  
Department of Clinical Microbiology  
E.mail :gyetkin@inonu.edu.tr