

Huge Gluteal Soft Tissue Mass Due to Hydatid Cyst

Dr. Adnan Hasanoğlu¹, Dr. N. Engin Aydın², Dr. M. Akif Kaygusuz³, Dr. Kaya Saraç⁴,
Dr. Ertan Bülbüloğlu¹

A 9 cm cystic mass located in the left gluteal region of a 28-year-old man was operated with a presumptive diagnosis of soft tissue abscess. Operative findings and pathological examination confirmed that the mass was a hydatid cyst. Hydatid cyst must be taken into consideration in the evaluation of soft tissue masses where the infestation is endemic. [Journal of Turgut Özal Medical Center 1997;4(2):212-214]

Key Words : Soft tissue mass, hydatid cyst, Echinococcosis, abscess

Gluteal kasta yerleşmiş büyük bir kist hidatik olgusu

Sol gluteal bölgede 9 cm civarında kitle palpe edilen 28 yaşındaki erkek hasta , yumuşak dokuda abse ön tanısı ile ameliyat edildi. Operasyon sırasında ve patolojik inceleme sonucunda kitlenin kist hidatik olduğu belirlendi. Kist hidatik;özellikle endemik olduğu bölgelerde yumuşak doku kitlelerinin ayırıcı tanısında akla gelmelidir. [Turgut Özal Tıp Merkezi Dergisi 1997;4(2):212-214]

Anahtar Kelimeler: Kist hidatik, abse, kitle, yumuşak doku, Echinococcus granulosus

The cyst stage of Echinococcus granulosus (hydatid cyst) is an important parasitic infestation in various sheep and cattle raising areas of the world (1). The cysts are most commonly located in the liver or lungs, however cysts can be found in any organ or tissue. Hydatid cysts located in the muscular soft tissues has been regarded as the third common location (1,2).

In this report we present a case which was discovered as a soft tissue mass in the left gluteal region of a young man.

CASE REPORT

A 28-year-old man complaining of pain and swelling in his left buttock for a period of one year was hospitalized for evaluation. On physical examination an immobile 9 cm mass with a smooth surface and ill defined margins was found in the left gluteal region . Biochemical and hematological laboratory tests were within normal limits. Ultrasonographic evaluation of the mass revealed a 8x6 cm cystic lesion 2.5 cm below the skin in the gluteal muscle. The mass had multiple septa and had well defined borders. A computerized

¹ İnönü University School of Medicine Department of General Surgery, Malatya

² İnönü University, School of Medicine, Department of Pathology, Malatya

³ İnönü University, School of Medicine, Department of Orthopedics, Malatya

⁴ İnönü University, School of Medicine, Department of Radiology, Malatya

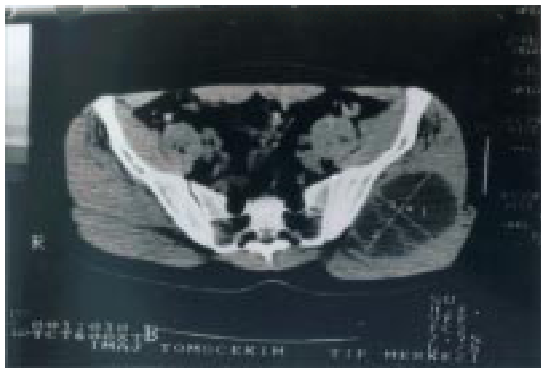

Figure 1. Computerized tomography revealed 8x6 cm cystic lesion with well defined border 2.5cm below the skin in the gluteal muscle.

tomography confirmed these findings (Figure 1). Fine needle aspiration of the cystic mass revealed only neutrophils in moderate amounts. Bacteriological cultures were also negative.

Clinical, radiological and cytological findings all pointed to a presumptive diagnosis of an encapsulated abscess of the left gluteal region since this was one of the frequently encountered situations in our medical practice due to inappropriate injections. However, the patient denied any recent intramuscular injection on that region.

The patient was operated on for diagnostic and therapeutic purposes. After spinal anesthesia a mass of 15 cm was excised from the left gluteal muscles (Figure 2, 3). An immediate pathological evaluation with frozen section was requested for the intact mass. Upon sectioning, multiple grape like vesicles and white semi-viscous cyst fluid along with detached opaque acellular membrane in a unilocular cyst was found (Figure 4). Microscopic examination revealed a necrotic inner border facing the fragmented parasitic membrane of hydatid cyst and a well formed fibrous host tissue encapsulation.

The patient followed an uneventful recovery period and was discharged from the hospital on the seventh postoperative day and was given albendazole 10 mg/kg/day for three months. In the monthly evaluations for the three month period after the operation the patient was in complete health. Any other cystic or mass lesion could not be found in systemic evaluations. Upon questioning the patient reported close contact with dogs for the last two years.

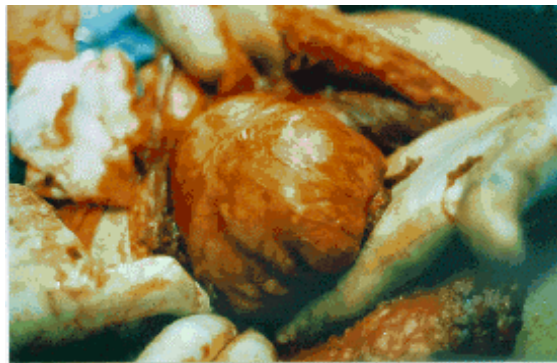


Figure 2. The excision of the mass from the left gluteal muscle

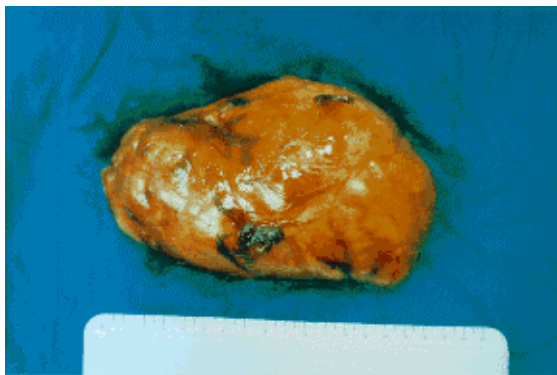


Figure 3. Length of the mass was approximately 15 cm.

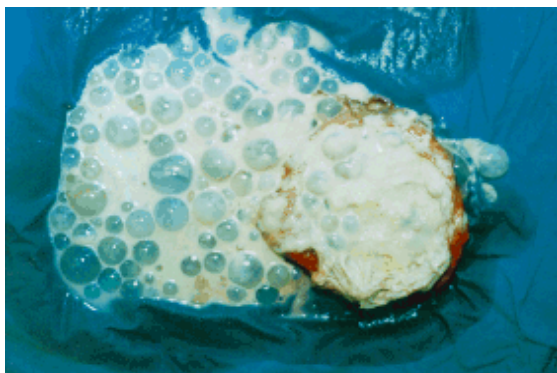

Figure 4. Multiple grape like vesicles and white semiviscous cyst fluid was demonstrated in the mass.

DISCUSSION

Echinococcal hydatid disease is known to affect almost any organ or tissue but reports regarding involvement of the muscular soft tissues are rare and these are mostly located in peripheral muscle groups (3-7). The maximum incidence of muscle location has been estimated as about 5% of all organ involvements (1,2). This present case of

gluteal muscle involvement has unique features in several aspects. The huge size besides symptoms of relatively short duration (one year) were mimicks of a soft tissue tumor. In humans, hydatid cysts grow approximately 1 cm/year (1) so the lesion must have been present for a long time. However it has been noticed as a painful mass only for the last year before hospitalization. The patient also confirmed contact with dogs for the last two years.

Radiological examinations pointed to a multiloculated cystic lesion but could not yield a definitive diagnosis. Ultrasonographic findings may be suggestive (5) but magnetic resonance imaging has been considered more helpful and diagnostic in lesions which mimick soft tissue masses due to a complex or solid pattern (4). Fine needle aspiration cytology is also another non-invasive method and may yield scolices and/or hooklets (6) confirming the diagnosis in suspected cases. However, the aspiration in this case yielded only neutrophil leucocytes and thus an encapsulated abscess cavity was thought preoperatively. The definitive diagnosis was made after morphological examination of the excised mass, i.e. daughter vesicles and acellular membrane of hydatid cyst. However, since bacteriological studies were negative and due to necrosis of the cyst wall we suggest that the white colored fluid filling the cyst cavity was due to a sterile inflammation of the hydatid cyst. Easily traumatized location of the mass could have resulted in closed perforation and gradual leakage of the cyst with sterile inflammation. This sterile inflammation has also prevented preoperative diagnosis with fine needle aspiration cytology.

Turkey is one of the countries where both multilocular (alveolar) and unilocular hydatid diseases are seen (8). Multilocular form of the disease is restricted to the northeastern part where as unilocular disease can be encountered in every region. We also suggest that in the differential

diagnosis of cystic soft tissue masses in patients from Turkey hydatid cysts must be kept in mind (7).

REFERENCES

1. Gutierrez Y, Smith JH. Metazoan diseases, in Anderson's pathology, 10 th edition, Editors; Ivan Damjanov, James Linder, Mosby-Year Book, Inc., St.Louis, 1996;1036.
2. Di Gesu G, Picone A, La Bianca A, Massaro M, Vetri G. Idatidosi muscolare e sottocutanea. *Minerva Med* 1987; 78: 835-40.
3. Duncan GJ, Tooke SM. Echinococcus infestation of the biceps brachii. *Clin Orthop* 1990; 261: 247-50.
4. Martin J, Marco V, Zidan A, Marco C. Hydatid disease of the soft tissues of the lower limb: findings in three cases. *Skeletal Radiol* 1993; 22:511-4.
5. Lamine A, Kikry T, Zryouil B. L'hydatidose primitive des muscles peripheriques. A propos de 7 cas. *Acta Ortop Belg* 1993; 59:184-8.
6. Giuffre G, Mondello P, Inferra A, Furchi A, Gentile HM, Speciale G. Unexpected cytological diagnosis of two cases of echinococcosis. *Pathologica* 1993; 85:747-53.
7. Yorukoglu Y, Zengin M, Dolgun A, Nazlıel K, Salman E, Pasaoglu E, Yucel E. Primary muscular hydatid cyst causing arterial insufficiency: case report and literature review. *Angiology* 1993; 44:399-401.
8. Uysal V, Paksoy, N. Echinococcosis multilocularis in Turkey. *Journal of Tropical Medicine and Hygiene* 1986; 89:249-55.

Correspondence: Adnan HASANOĞLU, M.D.
 İnönü Üniversitesi Tıp Fakültesi
 Turgut Özal Tıp Merkezi
 Genel Cerrahi ABD
 Kampüs, Malatya 44069
 Email address: ahasanoglu@ihlas.net.tr
 Phone & Fax: 90 422)341-0565