

## Jugular Phlebectasia in Children : A Case Report

Dr. Mehmet Demircan<sup>1</sup>, Dr. M. Harun Gürsoy<sup>1</sup>, Dr. Sema Uğuralp<sup>1</sup>, Dr. Mustafa Aydınç<sup>1</sup>,  
Dr. Bahar Müezzinoğlu<sup>2</sup>

*The authors report on a case with external jugular phlebectasia which is a rare entity in children. It is important to include it in the differential diagnosis of neck masses in children. Colour-doppler ultrasonography is a simple and valid diagnostic method to distinguish this pathology. Surgical removal of the involved segment was performed. [Journal of Turgut Özal Medical Center 1997;4(1):107-108]*

**Key Words:** Vascular anomalies, neck masses

### Çocukluk çağında jugular flebektazi : bir vaka raporu

*Çocuklarda nadir görülen bir antite olan external jugular flebektazili bir vaka sunulmuştur. Boyun kitlelerinin ayırıcı tanısında akla gelmesi önemlidir. Renkli Doppler ultrasonografi basit ve geçerli bir tanı metodudur. Dahil olan segmentin cerrahi olarak çıkartılması uygulanmıştır. [Turgut Özal Tıp Merkezi Dergisi 1997;4(1):107-108]*

**Anahtar Kelimeler:** Vasküler anomaliler, boyun kitleleri, cerrahi

Congenital dilatation involving veins of the superior vena caval system is rare in children (1-6). They appear as a soft, compressible swelling in the neck during straining or crying.

In this paper, a child with congenital external jugular phlebectasia was reported on and discussed.

**Case:** MK, an 18-month-old, admitted with a soft, compressible cyst-like mass at the right lateral aspect of the neck appearing only on straining or crying. There were no history of trauma or infection. On physical examination, a soft, non-tender mass became evident when he was crying. Doppler ultrasonography showed fusiform dilatation of the external jugular vein. Excision of the dilated segment of the vein was performed for cosmetic purpose.

Histopathologic examination of the excised segment of the vein showed diffuse fibrosis on the wall of the vein. Elastic fibers were thin and showed a disrupted architecture (Fig 1). Patients has all remained well after surgery.

### DISCUSSION

Venous ectasia in the neck is a rare entity, especially in children. The internal and external jugular veins are generally affected. A fusiform, soft, cystic mass manifested by straining, coughing, crying, or sneezing and on Valsalva maneuver appears in the neck (1-6).

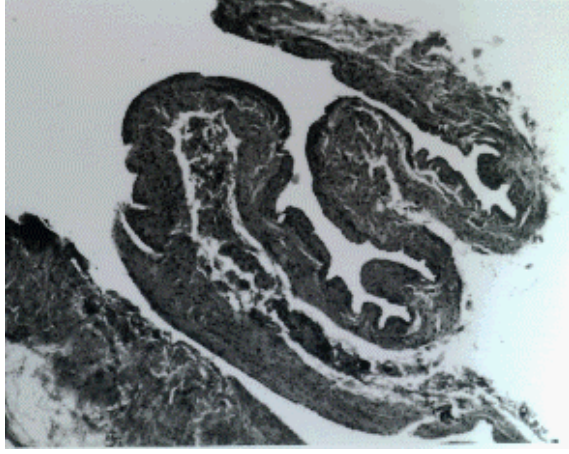
Neck lesions in children are not uncommon and accurate diagnosis of the mass is important. Three

---

<sup>1</sup> İnönü University School of Medicine Department of Pediatric Surgery, Malatya

<sup>2</sup> İnönü University School of Medicine Department of Pathology, Malatya

types of swelling distend on Valsalva and disappear completely at rest : (a) tumors or cyst of the superior mediastinum, (b) external laryngeal diverticulum and laryngocele, and (c) venous enlargement of the superior vena caval system (1-6).



**Figure 1.** The histopathologic appearance of the excised segment showing thinned and tortuous vessel wall (H&E x 40)

The etiology of jugular phlebectasia is unknown but is presumed to be due to an inherent weakness in the vessel wall. Histologic examination has failed to clarify the etiology of the venous ectasia. Histologically, diffuse fibrosis and disrupted architecture of the elastic tissue suggest the results of a mechanical effect (1,3,4)

Colour-doppler ultrasonography is a non-invasive accurate and readily reproducible imaging technique to distinguish the jugular venous enlargement and, in our case, it defined the extent of the lesion and its relationship with surrounding structures in the neck. Two comparable examination on doppler can be made for differential diagnosis; first, when the child is on Valsalva maneuver, and second, at rest. Computerized

tomography, or percutaneous venography may show dilatation, but they are considered unnecessary (1,6)

Surgical excision is mostly performed for cosmetic purpose, but Balık et al. reported a case who had jugular phlebectasia with thrombosis, and suggested surgical removal of the involved segment without delay because of thrombosis and some other unknown potential complications (1).

We concluded that colour-doppler ultrasonography is particularly enough for the diagnosis of jugular phlebectasia and appropriate surgical management should be undertaken.

## REFERENCES

1. Balık E, Erdener A, Taneli C ve ark. Jugular phlebectasia in children. *Eur J Pediatr Surg* 1993;3:46-7.
2. Danis RK. Isolated aneurysm of the internal jugular vein: a report of three cases. *J Pediatr Surg* 1982;17:130-1.
3. Gordon DH, Rose JS, Kottmeir P, Levin DC: Jugular venous ectasia in children. *Radiology* 1976;118:147-9.
4. Gilbert MG, Greenberg LA, Brown WT, et al. Fusiform venous aneurysm of the neck in children: a report of four cases. *J Pediatr Surg* 1972;7:106-11.
5. La Monte SJ, Walker EA, Noran WB: Internal jugular phlebectasia. *Arch Otolaringol* 1976;102:706-8.
6. Nwako FA, Aguga NEN, Udeh CA, Osuorji RI: Jugular phlebectasia. *J Pediatr Surg* 1989;24:303.

### Correspondence address:

Mehmet DEMİRCAN, MD  
İnönü University School of Medicine,  
Department of Pediatric Surgery  
44300 MALATYA