

## Role of Radiotherapy in Parotid Pleomorphic Adenoma: Two Case Reports and a Review of the Literature

Öztun Temelli<sup>1</sup>, Cemal Ekici<sup>2</sup>

<sup>1</sup>İnönü University, Faculty of Medicine, Department of Radiation Oncology, Malatya, Turkey

<sup>2</sup>İnönü Üniversitesi, Faculty of Medicine, Department of Medical Biology and Genetics, Malatya, Turkey

### Abstract

Pleomorphic adenoma is the most common benign salivary gland neoplasm (%75-80). It is found mostly in the parotid gland in middle-aged women. The optimal treatment is superficial or total parotidectomy with facial nerve preservation, which results in local control rates of 95% or higher. Radiotherapy (RT) is indicated for ositive margins, unresectable tumours, and multifocal recurrences after prior resection. Local control rates after RT for microscopic and gross residual tumour are approximately 80% to 85% and 40% to 60%, respectively. In this article, we share our experience of 2 cases of recurrent pleomorphic adenoma.

**Key Words:** Pleomorphic Adenoma; Radiotherapy; Treatment.

### Parotis Pleomorfik Adenomunda Radyoterapinin Yeri: İki Olgu Sunumu ve Literatürün Gözden Geçirilmesi

### Özet

Pleomorfik adenomlar tükürük bezlerinin en sık görülen iyi huylu neoplazmlardır (%75-80). Genelde orta yaşlı kadınlarda ve parotis bezinde bulunur. Optimal tedavi şekli fasial siniri koruyarak yapılan superfisyal veya total parotidektomidir. Cerrahi ile %95 ve üzerinde başarı vardır. Radyoterapi(RT) pozitif cerrahi sınırdaki, unrezekektabl hastalıkta ve cerrahi sonrası multifokal nüksde kullanılır. RT sonrası lokal kontrol mikroskopik hastalıkta %80-85 ve gros rezidüel hastalıkta %40-60 arasındadır. Biz de bu makalede cerrahi sonrası nüks eden 2 olguyu adjuvan RT deneyimimizi paylaştık.

**Anahtar Kelimeler:** Pleomorfik Adenom; Radyoterapi; Tedavi.

## INTRODUCTION

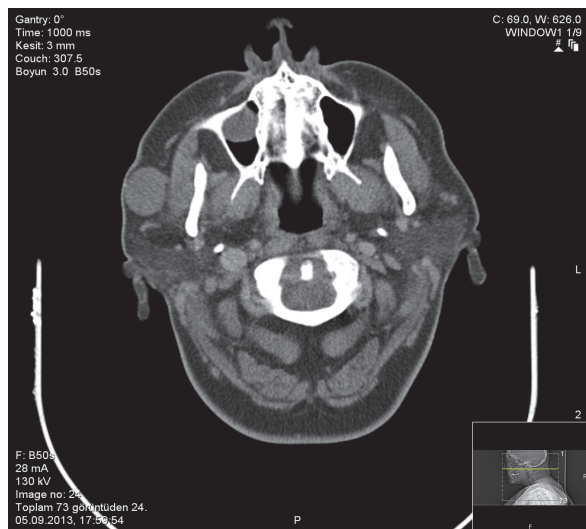
Pleomorphic adenomas are the most common benign neoplasms of the salivary glands (75-80%) (1). The term pleomorphic defines the epithelial and connective tissue structures from which tumours originate. Although pleomorphic adenoma is often found in the parotid gland, it can also be seen in the submandibular, sublingual, or minor salivary glands. It is usually seen between 30-60 years of age and is more common in women than it is in men (2, 3). Patients usually present with complaints of painless, slow-growing masses. About 3-4% of pleomorphic adenomas can turn into carcinoma, causing metastases and even death (4). Rarely, benign pleomorphic adenomas can also metastasize (5). The etiology is unclear. A study conducted in Brazil on 60 submandibular pleomorphic adenoma cases reports negative results for both Ki-67 and p53 gene mutations (6). Hamada et al.'s study on 9 recurrent pleomorphic adenoma patients and 40 patients without recurrence after surgery examines mucin expressions like MUC1, MUC2, MUC4, MUC5AC, and MUC6 and, after observing increase in MUC1/DF3 expression (by  $p=0,011$ ) in 4 of the 9 recurrent patients and 3 of the 40 patients without recurrence, it concludes that this indicator may be used as a marker in predicting recurrence after surgery (7).

In this study, we aim to review 2 patients who experienced relapse after surgery along with a survey of the related literature.

## CASE REPORT

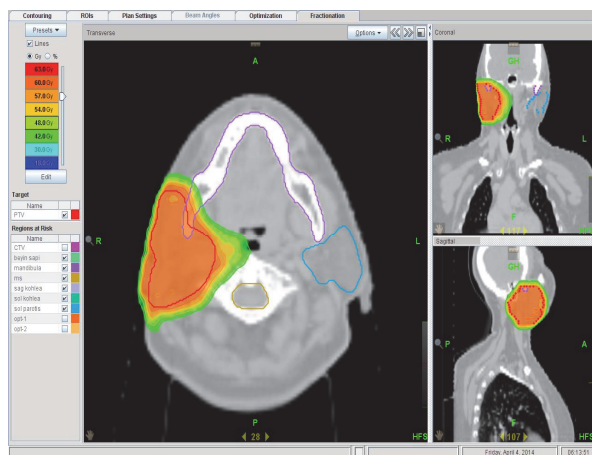
**Case 1:** A twenty-seven-year-old female patient was admitted to the hospital 6 years ago with swelling under the right ear. The CT imaging showed parotid masses. The patient underwent total parotidectomy due to parotid pleomorphic adenoma and was regularly followed. The imaging conducted 1,5 years showed that the patient had developed parotid mass. Considering the case as a relapse, the patient was taken to the Ear, Nose and Throat department for re-operation. The pathology result was assessed as pleomorphic adenoma. The hospital council then decided to administer postoperative radiotherapy for the patient.

**Case 2:** A forty-nine-year-old female patient was admitted to the hospital because of a swelling behind the ear 7 years ago. The patient underwent total parotidectomy twice for parotid pleomorphic adenoma on the right side; one seven years ago and another five years ago. Due to the recurrence of the swelling, the patient was re-admitted and the CT imaging showed another mass upon which the patient was operated for a third time (Figure 1).



**Figure 1.** CT image showing the recurrent mass in Case 2.

The pathology result was assessed as pleomorphic adenoma. Once again, the hospital council then decided to administer postoperative radiotherapy for the patient. During our radiotherapy planning, we defined the tumour lodge (bed) in clinical target volume (CTV) while the planned target volume (PTV) was defined as CTV+1cm. Critical organ doses did not exceed the tolerance doses. We planned to have a target dose of 95% of PTV. Before each treatment, we obtained images with megavoltage computed tomography (MV-CT) and set the PTV localisation (localization). The patients were treated with a helical tomotherapy device. Case 1 patient received a total dose of 50Gy with a 2Gy fraction dose while our second patient was applied a radiotherapy of 54Gy (Figure 2).



**Figure 2.** Helical tomotherapy dose distribution in Case 2.

The treatment was well tolerated by the patients; apart from grade 1 skin reactions, we did not observe any acute complications. The critical organ doses were kept at the desired dose ranges. The magnetic resonance (MR) imaging applied 10 (12) months after the treatment did not reveal any residual tumours.

## DISCUSSION

Pleomorphic adenoma is a benign kind of neoplasm that is usually seen in parotid gland and rarely seen in submandibular, sublingual, and minor salivary glands (1). Surgical excision is the optimal treatment method for curing pleomorphic adenoma. However a neat surgical excision with clear margins is difficult to achieve because it is located next to the facial nerve (8). Laccourre et al.'s study of 229 patients treated with surgery alone relates a control rate of 99.6% within a span of 10 years (2). Enucleation and extracapsular dissection were the preferred methods to treat pleomorphic adenoma in the past though today practitioners have adopted superficial or total parotidectomy as the standard surgical approach to preserve the facial nerve. Radiotherapy is indicated only when positive surgical is marginal or in cases of gross residual disease or recurrent multifocal disease. Suspicious tumor margins or tumour cultivation are no longer evaluated as RT indications. RT can be administered to inoperable patients or to patients who do not accept surgery as an option. Radiation doses in such patients are higher than the level of malignancy. In microscopic residual diseases, it is recommended to apply a single daily fraction of 66 Gy/33 fractions or two 1.2 Gy fractions with a total of 69,2-74,4 Gy per day. In gross residual diseases, the suggested daily application options are either 70Gy/35 fractions or a total dose 74,4Gy at a fraction dose of 1,2Gy. In addition, it should be kept in mind that re-excision prior to adjuvant RT may also increase the local control rate (1).

RT and surgical resection should be combined in recurrent pleomorphic adenoma because salvage surgery is less effective than complete resection at the time of initial diagnosis. In their study conducted on 108 recurrent pleomorphic adenoma patients, Wittekindt et al. have found single recurrence in 32 and multiple recurrence in 56 patients (9). In a 25-patient study at the University of Florida, 68% of the patients have failed to be treated until the fourth surgical intervention while those who received RT have responded better to local control (8).

RT's influence on achieving local control in recurrent pleomorphic adenoma has been demonstrated in various series. Dawson and Orr's study on 311 patients between 1950 and 1971 shows that these patients were treated with surgery and adjuvant RT. In this study, 279 patients were applied 55-60Gy brachytherapy with radium needles. 28 patients were applied 50-60Gy external beam radiotherapy whereas 4 patients underwent both brachytherapy and external beam radiotherapy. Despite the secondary malignancies in 4 patients (1%) (sarcoma after 14 years in one of them; adenocarcinoma in 2 patients in 18 and 30 years, respectively; and carcinoma ex pleomorphic adenoma in the fourth patient), this study has achieved a local control rate of 97% in 301 of 311 patients along with a local control rate of 92% in 20 years (10). A series of 34 patients with recurrence have been applied an average of 50Gy of RT at the University of California (between

the first and sixth recurrence) and the local control was reported to be 94% in 20 years in this study (11). Liu et al's 29-patient series on cases with local recurrence reports a 10-year local control rate of 82% after administering 45Gy of RT (12).

Approximately 3-4% of pleomorphic adenoma cases may turn to carcinoma (4, 5). Makeieff et al. have determined malignant transformation in 10 of 62 patients they had operated for recurrent pleomorphic adenoma (13). Wittekindt et al., on the other hand, do not report any malignant transformations in 108 patients undergoing surgery for recurrence (9). The study at the University of Florida reports malignant transformation in 2 of the 7 patients who formerly underwent adjuvant RT for recurrent pleomorphic adenoma with further recurrence after RT (8). Due to lack and inconsistency of data in retrospective series, it is difficult to determine prognostic factors for malignant transformation though it is likely that the duration of lesions may be increasing the likelihood of malignant transformations.

As a result, it should be stated that surgical treatment is the main option in treating pleomorphic adenoma. Adjuvant RT is useful and generally well tolerated in positive surgical margins and multi-nodular recurrence. While helical tomotherapy and intensity-modulated radiotherapy achieve target volume, desired dose, and homogeneity especially in tumours located in risky areas like the head and neck, it is possible to achieve doses within tolerance limits in the critical organ doses.

## REFERENCES

- Mendenhall WM, Mendenhall CM, Werning JW, Malyapa RS, Mendenhall NP. Salivary gland pleomorphic adenoma. *Am J Clin Oncol* 2008;31(1):95-9.
- Laccourreye H, Laccourreye O, Cauchois R, et al. Total conservative parotidectomy for primary benign pleomorphic adenoma of the parotid gland: a 25-year experience with 229 patients. *Laryngoscope* 1994;104:1487-94.
- Satar B, Gerek M, Yetişer S, Akkaya A, Özkaptan Y. Major Tükürük Bezi Tümörleri: 93 Olgunun Analizi. *Türkiye Klinikleri J E.N.T* 2001;1(3):123-8.
- Ohtake S, Cheng J, Ida H, et al. Precancerous foci in pleomorphic adenoma of the salivary gland: recognition of focal carcinoma and atypical tumor cells by P53 immunohistochemistry. *J Oral Pathol Med* 2002;31:590-7.
- Nouraei SA, Ferguson MS, Clarke PM, et al. Metastasizing pleomorphic salivary adenoma. *Arch Otolaryngol Head Neck Surg* 2006;132:788-93.
- Alves FA, Perez DE, Almeida OP, et al. Pleomorphic adenoma of the submandibula gland: clinicopathological and immunohistochemical features of 60 cases in Brazil. *Arch Otolaryngol Head Neck Surg* 2002;128:1400-03.
- Hamada T, Matsukita S, Goto M, et al. Mucin expression in pleomorphic adenoma of salivary gland: a potential role for MUC1 as a marker to predict recurrence. *J Clin Pathol* 2004;57:813-21.
- Wallace AS, Morris CG, Kirwan JM, Werning JW, Mendenhall WM. Radiotherapy for pleomorphic adenoma. *Am J Otolaryngol* 2013;34(1):36-40.
- Wittekindt C, Streubel K, Arnold G, et al. Recurrent pleomorphic adenoma of the parotid gland: analysis of 108 consecutive patients. *Head Neck* 2007;29:822-8.
- Dawson AK, Orr JA. Long-term results of local excision and radiotherapy in pleomorphic adenoma of the parotid. *Int J Radiat Oncol Biol Phys* 1985;11(3):451-5.
- Chen AM, Garcia J, Bucci MK, et al. Recurrent pleomorphic adenoma of the parotid gland: long-term outcome of patients treated with radiation therapy. *Int J Radiat Oncol Biol Phys* 2006;66:1031-5.
- Liu FF, Rotstein L, Davison AJ, et al. Benign parotid adenomas: a review of the Princess Margaret Hospital experience. *Head Neck* 1995;17:177-83.
- Makeieff M, Pelliccia P, Letois F, et al. Recurrent pleomorphic adenoma: results of surgical treatment. *Ann Surg Oncol* 2010;17:3308-13.
- Ravasz LA, Terhaard CH, Hordijk GJ. Radiotherapy in epithelial tumors of the parotid gland: case presentation and literature review. *Int J Radiat Oncol Biol Phys* 1990;19(1):55-9.
- Barton J, Slevin NJ, Gleave EN. Radiotherapy for pleomorphic adenoma of the parotid gland. *Int J Radiat Oncol Biol Phys* 1992;22(5):925-8.
- Samson MJ, Metson R, Wang CC, et al. Preservation of the facial nerve in the management of recurrent pleomorphic adenoma. *Laryngoscope* 1991;101:1060-2.
- Hodge CW, Morris CG, Werning JW, et al. Role of radiotherapy for pleomorphic adenoma. *Am J Clin Oncol* 2005;28:148-51.
- Douglas JG, Einck J, Austin-Seymour M, et al. Neutron radiotherapy for recurrent pleomorphic adenomas of major salivary glands. *Head Neck* 2001;23:1037-42.

Received/Başvuru: : 14.07.2014, Accepted/Kabul: 09.10.2014

Correspondence/İletişim

Öztun TEMELLİ  
İnönü Üniversitesi Tıp Fakültesi, Radyasyon Onkolojisi  
Anabilim Dalı, MALATYA, TÜRKİYE  
E-mail: droztun@gmail.com

For citing/Atf için

Temelli O, Ekici C. Role of radiotherapy in parotid pleomorphic adenoma: two case reports and a review of the literature. *J Turgut Ozal Med Cent* 2015;22:125-7 DOI: 10.7247/jtomc.2014.2297