



A Rare Cause of Childhood Anaemia: Idiopathic Pulmonary Hemosiderosis

Çocukluk Çağı Anemisinin Nadir Bir Nedeni: İdiopatik Pulmoner Hemosiderozis

Velat Şen¹, Müsemma Karabel¹, Tuba Tuncel², Selvi Kelekçi¹, İlyas Yolbaş¹, Fuat Gürkan³

¹Dicle University Faculty of Medicine, Department of Pediatrics, Diyarbakır, Turkey

²Katip Celebi University Faculty of Medicine, Department of Pediatric Allergy and Immunology, Izmir, Turkey

³Dicle University Faculty of Medicine, Department of Pediatric Pulmonary Diseases, Diyarbakır, Turkey

Dear Editor,

Often seen in childhood, idiopathic pulmonary hemosiderosis (IPH) is a rare cause of alveolar haemorrhage with unknown etiology. It is characterised by recurrent hemoptysis, iron deficiency anaemia, and diffuse parenchymal infiltration in chest radiography (1). The incidence rate of IPH in children is between 0,24 and 1,26 in a million and this explains the very few number of reported cases in the literature (2).

A seven-year-old male patient was admitted to a hospital with shortness of breath, fever, cough, and blood coming from the mouth. The patient was diagnosed with and treated for pneumonia for 23 days in the hospital but, showing no clinical signs of betterment, he was eventually referred to our clinic. We learnt that the patient had been hospitalised many times for prolonged cough, shortness of breath, and blood coming from the mouth. The patient also had three blood transfusions due to anaemia. Physical examination results were as follows: blood pressure 98/65 mm Hg; pulse 97/minute; body temperature 37°C; respiratory rate 43/min. His skin, mucous membranes, and conjunctiva were pale. There were widespread crackles in the lower parts of both of his lungs. Other system examinations were normal. The laboratory results were as follows: erythrocyte sedimentation rate 38mm/hr; leukocytes 7780/mm³; platelets 543.000/mm³; hemoglobin 12,2g/dL; and hematocrit 35,5%. The peripheral blood smear showed the following values: neutrophils at a level of 68%; lymphocytes were at a level of 32%; and erythrocyte morphology was hypo-chromic microcytic. The urinalysis was normal. The liver and renal functions as well as the serum electrolyte levels were also normal. The serum iron level was 38 ug/dl while the serum iron binding capacity

was 210 ug/dl. The immunological test results were as follows: total IgE 4,35 IU/mL; IgG 1880 mg/dL; IgA 239 mg/dL; IgM 230 mg/dl, which were all in the normal range for his age. The skin prick test result was normal, too. In addition, the patient's ANA, anti-ds-DNA, anti-BM, p-ANCA, and c-ANCA levels were all negative. We observed restriction during the pulmonary function tests. The electrocardiography was in normal sinus rhythm but the echocardiography showed a 4mm secundum atrial septal defect. We determined reticulonodular opacity increase in the bilateral middle and lower zones in the posterior-anterior chest radiograph (Figure a).

The thoracic computed tomography (CT) showed widespread reticulonodular infiltration areas in both lungs, interlobular septal thickening in the posterobasal segment, and patchy focal consolidation (Figure b). We applied bronchoalveolar lavage (BAL) accompanied with flexible bronchoscopy but did not observe any endobronchial lesions. The smear examination for fluid resistance acid bacilli (AFB) during the bronchoalveolar lavage was negative. There was no production in the nonspecific bronchoalveolar lavage fluid culture. Cytologically, we observed hemosiderin-laden macrophages in BAL spreads and these symptoms were evaluated as alveolar haemorrhage.

Because the case lacked secondary pathologies to rule out alveolar haemorrhage, we agreed on IPH as the diagnosis. We started a steroid treatment of 1 mg/kg/day. The patient responded to the treatment so we gradually reduced the dose and discontinued the medication in the 6th month of the treatment. The patient has been followed for 16 months now with no further complaints (Figure c).

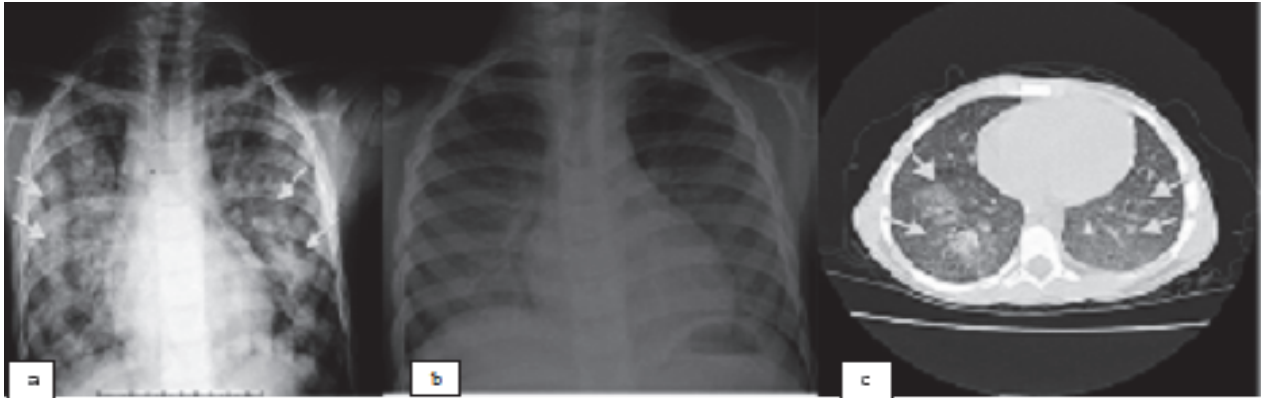


Figure a. Reticulonodular opacity has increased in the bilateral middle and lower zones in the posterior-anterior chest before the treatment.

Figure b. The thoracic computed tomography (CT) showing widespread reticulonodular infiltration areas in both lungs, interlobular septal thickening in the posterobasal segment, and patchy focal consolidation.

Figure c. The CT image after a 16-month-follow-up; lesions have significantly decreased.

The etiology of the disease is not known. Many allergic, environmental, genetic, and autoimmune factors have been implicated in the pathophysiology of the disease (1). There are many reported cases of IPH that accompanies Goodpasture's syndrome, celiac disease, glomerulonephritis, autoimmune haemolytic anaemia, and rheumatoid arthritis (3, 4). In our patient, the autoimmune antibodies were negative and there were no accompanying autoimmune diseases.

There is familial clustering and an increased incidence rate of IPH in consanguinity though there are no identified genes suggesting a genetic predisposition (5). The allergy-based hypothesis depends on the idea of frequent association between IPH and cow's milk allergy (6). Our patient did not have consanguineous marriage in his medical history as his allergy tests were also negative. Because the disease has rare and various clinical presentations, its diagnosis is often delayed. Kiper et al. believe that diagnosis may require a time period from 4 months up to 10 years after the onset of symptoms (7). In our patient, too, there was a two-year delay until the diagnosis.

There may be no infiltration on the initial chest radiography. However, there may be bilateral alveolar consolidation that do not occupy the apices during acute attacks. In the active period of the disease, thoracic CT reveals alveolar infiltration, patchy areas of ground glass in the subacute phase, and diffused nodules (1). In our case, the thoracic CT showed visible ground-glass appearance on each side of the hemi-thorax in the middle and lower zones and septal peribronchovascular thickening.

Lung biopsy, the gold standard for diagnosis, is an invasive procedure. However, after determining hemosiderin-laden macrophages in the BAL fluid, practitioners can decide on the diagnosis by ruling out other causes of the diffused alveolar hemorrhage (8). Iron deficiency anemia, hemoptysis, and diffuses infiltrates in chest X-rays have been reported to be typical signs of

the disease (3). Iron deficiency anaemia may be the first symptom and other symptoms may occur after several months. Isolated iron-deficiency anaemia may respond to iron therapy within 1 month but IPH may not necessarily respond to iron therapy and may require repeated transfusions (9). Our patient also had a long-standing iron-deficiency anaemia that did not respond to the treatment which was also the reason why the patient had to have blood transfusion for three times.

Evidence-based treatment recommendations are unfortunately limited. Corticosteroids found in case series with small numbers of patients and several case reports are the basis of treatment options of IPH. Corticosteroids have been associated with reduction in pulmonary haemorrhage relapses and pulmonary fibrosis (8). The recommended starting dose is about 1 mg/kg/day of prednisolone treatment for 2 months until the new alveolar infiltrates decline (3). Corticosteroids are effective in the acute phase but their effects are uncertain in chronic phases. In patients who do not respond to steroids, immunosuppressant agents can be considered.

Small series of patients, short observation periods, and inadequate follow-ups are the reasons that make it difficult to assess the prognosis of IPH. While some patients are in clinical remission with occasional episodes of hemoptysis, others may have progressive pulmonary fibrosis. Two major causes of death in IPH are pulmonary haemorrhage accompanied by acute respiratory failure and ongoing pulmonary hemosiderosis with fibrosis-related chronic respiratory failure. Long-term use of immunosuppressive therapy may provide improvement in prognosis. We still know very little about IPH and there is need for prospective study with series with large numbers of patients. However, because it is a very rare disease, multi-central studies should be encouraged. Due to its high mortality risk, early diagnosis and treatment are very important in IPH. Respiratory symptoms may initially be quite faint. Therefore, while monitoring children with recurrent respiratory symptoms and

persistent anaemia, practitioners should ask for chest radiography and keep IPH in mind in the differential diagnosis in the presence of bilateral infiltrates.

Presented at the 49th Turkish Pediatrics Congress (10-13 June 2013, İstanbul)

REFERENCES

1. Clement A, Nathan N, Epaud R, Fauroux B, Corvol H. Interstitial lung diseases in children. *Orphanet J Rare Dis* 2010;5:22-7.
2. Saeed MM, Woo MS, MacLaughlin EF, Margetis MF, Keens TG. Prognosis in pediatric idiopathic pulmonary hemosiderosis. *Chest* 1999;116:721-5.
3. Ioachimescu OC, Sieber S, Kotch A. Idiopathic pulmonary hemosiderosis revisited. *Eur Respir J* 2004;24:162-170.
4. Nuesslein TG, Teig N, Rieger CH. Pulmonary haemosiderosis in infants and children. *Paediatr Respir Rev* 2006;7:45-8.
5. Beckerman RC, Taussig LM, Pinnas JL. Familial idiopathic pulmonary hemosiderosis. *Am J Dis Child* 1979;133:609-11.
6. Moissidis I, Chaidaroon D, Vichyanond P, Bahna SL. Milk-induced pulmonary disease in infants (heiner syndrome). *Pediatr Allergy Immunol* 2005;16:545-52.
7. Kiper N, Gocmen A, Ozcelik U, Dilber E, Anadol D. Long-term clinical course of patients with idiopathic pulmonary hemosiderosis (1979-1994): prolonged survival with low-dose corticosteroid therapy. *Pediatr Pulmonol* 1999;27:180-4.
8. Bulucea C, Sorin D. Idiopathic pulmonary hemosiderosis in children: a Romanian experience. *Pediatrics* 2008;12:158-9.
9. Yao TC, Hung IJ, Wong KS, Huang JL, Niu CK. Pitfalls in the diagnosis of idiopathic pulmonary haemosiderosis. *Arch Dis Child* 2002;86:436-8.

Received/Başvuru: 24.09.2014, Accepted/Kabul: 20.10.2014

Correspondence/İletişim

Velat SEN
Dicle Üniversitesi Tıp Fakültesi, Çocuk Sağlığı ve Hastalıkları
Anabilim Dalı, DİYARBAKIR, TÜRKİYE
E-mail: drvelatsen@hotmail.com

For citing/Atf için

Sen V, Karabel M, Tuncel T, Kelekci S, Yolbas I, Gurkan F.
A rare cause of childhood anaemia: idiopathic pulmonary
hemosiderosis. *J Turgut Ozal Med Cent* 2015;22:145-7- DOI:
10.7247/jtomc.2014.2397