



Cerebral venous thrombosis associated with childhood ulcerative colitis

Günsel Kutluk¹, Nilüfer Eldeş Hacıfazlıoğlu², Hilal Horozoğlu², Deniz Ertem¹, Yüksel Yılmaz²

¹Marmara University, Medical Faculty, Division of Pediatric Gastroenterology, İstanbul, Turkey

²Marmara University, Medical Faculty, Division of Pediatric Neurology, İstanbul, Turkey

Summary

Ulcerative colitis (UC) can be complicated by various extra-intestinal manifestations such as thromboembolic disease. Most thrombotic events occur in lower extremities, whereas the incidence of cerebral venous involvement is very rare and serious in children. We present a case of a nine years old boy with UC and cerebral venous thrombosis diagnosed at the same time. A nine years old boy with a 3- week history of bloody diarrhea and abdominal pain was admitted to our hospital. On admission his laboratory data showed anemia, leukocytosis, thrombocytosis and elevated erythrocyte sedimentation rate. Colonoscopic evaluation revealed severe active pancolitis with diffuse ulceration. The day after colonoscopy he had complained of severe headache. Neurological examination revealed ptosis of the left palpebra and bilateral papilledema. Magnetic resonance (MR) imaging and MR venography revealed thrombosis in the left transvers sinus and sigmoid sinus. The patient was treated immediately with heparin. At the same time he was diagnosed with severe active UC based upon histopathological findings and managed initially with mesalamin and prednisolon. He also had been screened for thrombophilia. Protein C, protein S, antithrombin III, factor VIII, homocystein, prothrombin II and fibrinogen levels were in the normal range but he was heterozygous for the methylene tetrahydrofolate reductase gene mutation. After two weeks of therapy his bloody diarrhea was controlled, headache and neurological findings were improved. His treatment was continued with mesalamin, prednisolon, azathioprin and low molecular weight heparin, but repeated MRI and MRI venography showed neither extension nor improvement of the thrombosis. (*Turk Arch Ped* 2013; 48: 160-164)

Key words: Cerebral venous thrombosis, complication, ulcerative colitis

Introduction

Inflammatory bowel diseases (IBD) are a disease group which involves the gastrointestinal system, but also causes extra-gastrointestinal systemic findings. This disease group is characterized with chronic inflammation and genetic and environmental factors are involved in the etiology (1).

Crohn disease which is included in inflammatory bowel diseases is primarily characterized with chronic diarrhea, growth-development retardation and extra-bowel findings, while typical findings including bloody diarrhea, defecation at night and abdominal pain are prominent in ulcerative colitis (UC). Symptoms may occur at any age, but the disease onset is most frequently observed in the late adolescence-early adulthood (2).

The diagnosis of inflammatory bowel disease is based on the medical history, clinical assessment and typical endoscopic and histological findings (3).

Thromboembolism is a known but substantially rare extra-intestinal complication of IBD and is observed in 1.3-6.7% of all patients (4).

Increased inflammatory response during the course of the disease, procoagulant activity of which the cause is unknown, long-term immobility and fluid loss are the main factors which increase the risk of thromboembolism (5). In most cases, involvement of the pelvic, pulmonary and peripheral arteries and veins is observed. Central nervous system involvement and related neurological complications are observed substantially rarely. Brain vein thrombosis is observed rarely in children with inflammatory bowel

disease, but its early diagnosis and treatment constitute an urgent condition in terms of decreasing the morbidity and mortality rates (6).

Case

A 9-year-old male patient presented to Marmara University Medical Faculty, Division of Pediatric Gastroenterology because of abdominal pain, bloody and mucous defecation and malaise. It was learned that his complaints continued for three weeks, he had a similar bloody diarrhea attack two years ago which lasted shorter and he was treated with metronidazole. The personal history of the patient was normal. It was learned that he had no easy bleeding, ecchymosis, drug or food allergy, usage of non-steroid antiinflammatory drugs, skin eruption, joint complaint or visual disturbance. There was no familial history of polip, IBD or colon cancer. His parents were first-degree cousins. His growth and development was found to be normal (height- weight: 75-90th percentile). Physical examination revealed no pathology except for mild palor and increased intestinal sounds. No fissure, fistula or polip was found on anorectal examination.

Laboratory tests were as follows: WBC: 14 300/ mm³, Hgb: 9. g/dL, Hct: 29%, MCV: 74,7 fL, Platelets: 485 000/ mm³, Fe: 22 ug/dL (N>26), TIBC: 423 ug/dL (N:110-370), Ferritin: 7.69 ng/mL (N:30-400), Erythrocyte sedimentation rate: 35 mm/saat (N<15), CRP: 2.12 mg/dL (N<0.8), PT: 12.9s, PTT: 30.4 s. Liver function tests, renal function tests and electrolytes were within the normal limits. On stool examination, abundant erythrocytes and leukocytes were observed. Culture and parasite investigations were found to be negative. In the serological tests, p/c- ANCA was found to be negative. Colonoscopic examination performed because of chronic bloody diarrhea revealed pancolitis with diffuse bleedings and ulcers covered with exuda in places in the whole mucosa from the rectum to the cecum (Picture 1).

After colonoscopy the patient was observed to be weak and pale. He was internalized in the ward because of persistent, pulsating headache localized in the frontal and left occipital region which increased for the last three days in severity and monitored with intravascular fluid support. Laboratory investigations revealed anemia (7.5 mg/dL), leukocytosis (22 400/mm³) and thrombocytosis (548 000/mm³). On neurological examination, ptosis of the left palpebra at the level of the pupilla and bilateral first degree papilledema were observed. Brain magnetic resonance imaging (MTI) and MR-venography which were performed urgently to elucidate the etiology in the patient who had findings of increased intracranial pressure revealed thrombosis in the left transverse and sigmoid sinus (Figure 2 and 3). PT, PTT, protein C, protein S, antithrombin III, Factor VIII, fibrinogen, homocystein and prothrombin

I levels were investigated in terms of predisposition to thrombosis and were found to be within the normal limits. Factor Leiden mutation which causes genetic predisposition to thrombophilia was found to be negative and MTHFR mutation was found to be heterozygously positive. No other characteristic which would lead to brain vein thrombosis was found in the patient except for IBD.

Colonoscopic biopsies revealed severe inflammation localized in the submucosa and mucosa histopathologically, cryptitis and diffuse active colitis with local ulcerations. No granuloma was found (Figure 4). With these findings the patient was diagnosed as brain vein thrombosis together with the diagnosis of ulcerative colitis.

Steroid 2 mg/kg/day and mesalasin 50 mg/kg/day for treatment of ulcerative colitis and intravenous heparin for treatment of brain vein thrombosis were started. On the 10th day of treatment, headache decreased and papilledema and ptosis disappeared. On the 14th day of heparin treatment, low-molecular-weight heparin was initiated. The patient who responded to corticosteroid treatment, but experienced exacerbation when the dose was reduced because of severe side effects and did not respond well to immunosuppressive treatment (azathioprine) is still receiving azathioprine 2 mg/kg/day and mesalasin 50 mg/kg/day. In the first year of treatment, MR venography was performed in the patient who had no neurological defect, but whose primary disease could not be controlled completely and it was found that there was no change in the thrombosis found in the left transverse and sigmoid sinus radiologically.

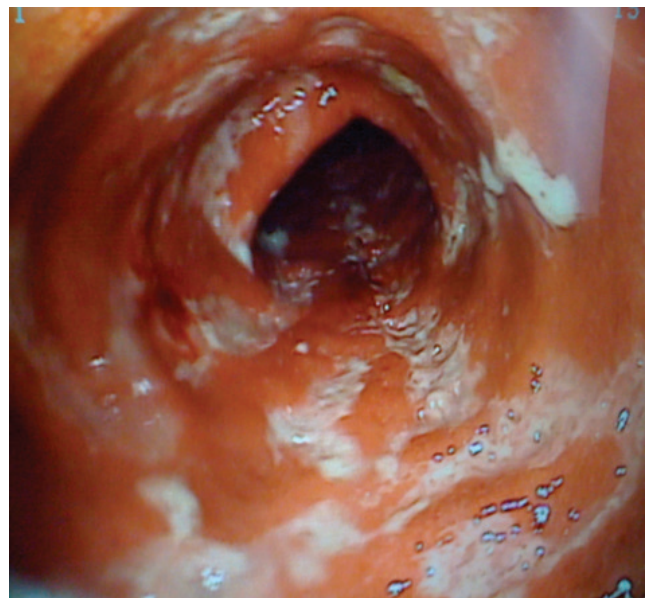


Figure 1. Extensive bleedings and ulcers covered with exuda in places in the whole mucosa

Discussion

During the course of inflammatory bowel diseases, extra-intestinal complications can be observed in 25-40% of the patients (7). Thromboembolism is a rare one among these complications and is observed in 1.3-6.4% of all IBD patients (4). Guerra Montero et al. (8) found the rate of thromboembolic complication to be 2.9% and the mortality rate due to this cause to be 6.7% in their retrospective research including 515 patients.

In 2% of the patients with brain vein thrombosis, the underlying cause is IBD (6,9). The data about the pediatric patient group are limited with the low number of cases reported in the literature and the prevalence is not known exactly. Three (two Crohn and one UC) of 32 patients who has been followed up in our unit since 1995 including the patient who is being discussed experienced thromboembolic event in the central nervous system. Barclay et al. (10) observed that four patients (2.6%) experienced thromboembolic event in the brain during a time period of 5 years in their retrospective research which included 154 pediatric IBD cases. In the same study, the publications belonging to the period before and after 2000

were screened and it was found that the rate of stroke was increased markedly especially in pediatric patients with Crohn's disease in the last ten years.

Thromboembolic complications generally develop in the pelvic, pulmonary and peripheral arteries and veins and they are in the third order with a rate of 17% among reasons for hospitalization in the intensive care unit in patients with inflammatory bowel disease (11). Central nervous system involvement and related neurological complications carry a high morbidity and mortality risk, though they occur with a lower frequency (6).

Although the mechanism of predisposition to thrombosis in patients with IBD can not be explained fully, prothrombotic factors, endothelial activation, increase in expression of tissue factor and defect in inhibition of coagulation have been proposed as the factors which are involved in the etiology (1,12). In patients with active IBD, increase in thrombocytosis, fibrinogen, factor V and factor VIII levels and decrease in antithrombin III level have been reported in parallel to increased inflammatory response (12). Endogenous thrombin potential which increases markedly in the active disease period causes to dysfunction in natural anticoagulant pathways by accelerating thrombin formation and increases predisposition to thrombosis (13,14). In addition to all these factors, increase in production of tumor necrosis factor (15) and decrease in production of glycosaminoglycan in the intestines may also have procoagulant effect (16). Deficiency of protein C has also been observed in some adult patients (17). Increased anticardiolipin antibody, prothrombin 20210 and prothrombin gene mutation and high dose corticosteroid treatment may trigger excessive coagulation (18,19). In a

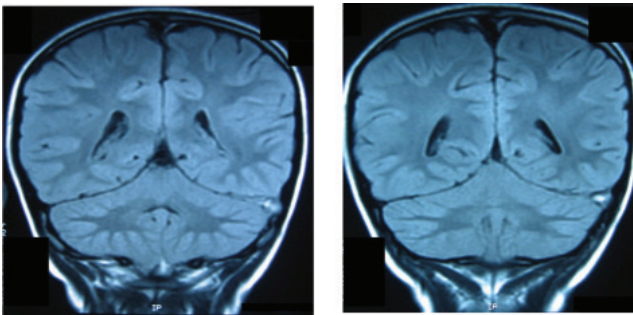


Figure 2. T-1-weighted cranial MRI: Filling defect showing hyperintense signal change compatible with thrombosis in the left transverse sinus in coronal sections

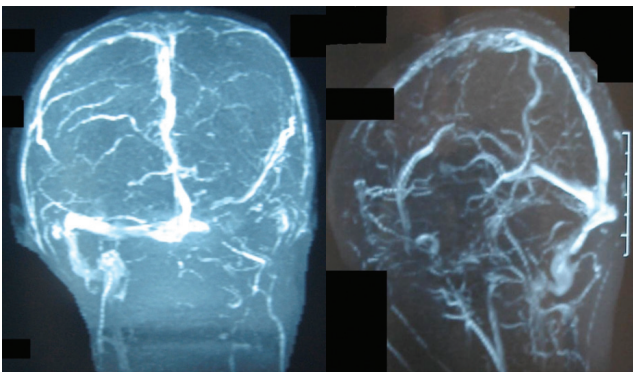


Figure 3. Loss of signal compatible with thrombosis in the 1/3 distal part of the superior sagittal sinus and in the left transverse sinus

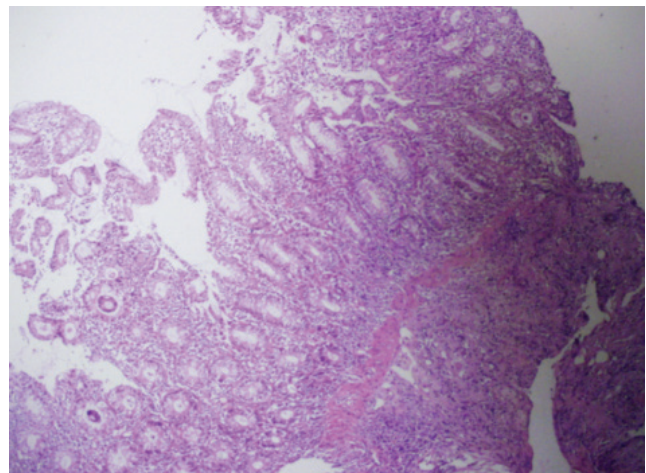


Figure 4. Severe inflammation, cryptitis, crypt abscess and focal ulcerations localized in the mucosa and submucosa (with hematoxyline and esoin stain at x100 magnification)

study performed by Akbulut et al. (20), a lower folate level and hyperhomocysteinemia were found especially in UC patient compared to the control group, but the relation of this condition with predisposition to thromboembolism could not be demonstrated. Studies have shown that factor V Leiden and prothrombin gene mutation which are among the genetic causes of thrombophilia are not observed more frequently in IBD patients who experience thromboembolic attack and this is not a factor which predisposes IBD patients to thrombosis (21). In our patient who was assessed in terms of genetic and acquired thrombophilia, heterozygous MTHFR gene mutation which does not carry a significant risk in terms of thrombophilia was found (22).

Guerra Montero et al. (8) reported that 53.3% of the patients who developed thrombosis were in the active disease period. Barclay et al. (10) reported 100% of the patients were in the active disease period in their study which included pediatric patients. It is thought that fibrinogen, prothrombin fragment F1+2, platelets, plasminogen activator inhibitor-1 antigen and soluble thrombomodulin which increase in the active disease period are responsible of development of thrombosis (12,23).

In addition to excessive coagulation which develops in relation with the disease activity, immobility and fluid loss do also contribute to development of vascular complications (24). In our patient who had active pancolitis which could be controlled with high dose steroid treatment, prolonged bloody diarrhea, persistent lying because of active disease, immobility and fluid loss due to inadequate fluid intake were also thought to be involved in development of thrombosis.

Findings may occur at any age in inflammatory bowel disease, but the disease onset is mostly observed in the late adolescence-early adulthood. In the literature, the youngest patient who developed thrombosis secondary to IBD was 10 years old (24). Our patient who developed thromboembolic complication at the age of 9 and was diagnosed UC is one of the youngest patients reported in the literature in this aspect.

Development of thrombosis in the course of IBD has generally been reported in patients who had been diagnosed before and who are under treatment and especially in the periods of acute exacerbations (4,5). In our patient who developed headache following bloody diarrhea, UC and brain thrombosis were found simultaneously. The most common complaint is headache in the cases reported in the literature. Papilledema, impaired consciousness and hemiparesia are the most commonly reported neurological examination findings in these patients (1,6,25,26). Our patient also had persistent, pulsatile headache which was localized in the frontal and left occipital regions which increased in severity for the last three days. Neurological examination revealed ptosis and papilledema. On brain MR

and MR venography performed urgently, thrombosis was found in the transverse and sigmoid sinus. In the literature, brain thrombosis has been reported most commonly in the lateral and saggital sinus in patients followed up because of IBD. It has been reported with a lower rate only in the cortical veins (1,6,26).

Treatment of brain vein thrombosis which develops in relation with IBD includes supportive symptomatic treatments including fluid support, appropriate antibiotic treatment when necessary, controlling of the seizures and increased intracranial pressure (27). It has been reported that anticoagulant treatment (heparin and low molecular weight heparin) can be used safely, ifa PTT and Factor Xa levels can be monitored. However, this information is limited with case presentations and small multi-center studies (1,6,25,26,28). The patient who was started on intravascular heparin treatment was switched to low molecular weight heparin after the neurological findings disappeared. Although there is no consensus on the time of anticoagulant treatment, long-term preventive treatment is recommended because of predisposition to coagulation (6,29).

The prognosis is substantially poor especially in the colitis group in patients who develop brain vein thrombosis related with inflammatory bowel disease (30,31). Patients in whom neurological findings improved and control MR venographies revealed no thrombosis after intravenous heparin treatment started have been reported (20,32), while there are also patients in whom neurological sequelae were observed or who were lost (1,3,9). In a study in which 42 cases of development of thrombotic complication in the brain related with ulcerative colitis were reviewed, permanent sequela or mortality were reported in 75% of the patients (9). Although our patient had intermittent headache during the follow-up period of one year, he had no neurological sequela. However, thrombosis persisted on control MR venography imaging. Since brain vein thrombosis was diagnosed and treated early in our patient, he had no neurological sequela. However, the primary disease could not be controlled fully and he is still being monitored with azathioprine, mesalazine and low molecular weight heparin.

The risk of thromboembolism is higher in patients with inflammatory bowel disease especially in the active period compared to the normal population because of predisposition to hypercoagulation. Brain vein thrombosis should be considered in the differential diagnosis in these patients when signs and symptoms including headache, cranial nerve involvement, papilledema, loss of motor function accompany the picture of colitis. Early diagnosis, appropriate treatment and close monitoring of this complication can decrease the risk of morbidity and mortality.

References

- Umit H, Asil T, Celik Y, Tezel A, Dokmeci G, Tuncbilek N, Utku U, Soylu AR. Cerebral sinus thrombosis in patients with inflammatory bowel disease: a case report. *World J Gastroenterol* 2005; 11: 5404-5407.
- Stange EF, Travis SP, Vermeire S, Reinisch W, Geboes K, Barakauskiene A, Feakins R, Fléjou JF, Herfarth H, Hommes DW, Kupcinskas L, Lakatos PL, Mantzaris GJ, Schreiber S, Villanacci V, Warren BF; European Crohn's and Colitis Organisation (ECCO). European evidence-based consensus on the diagnosis and management of ulcerative colitis: Definitions and diagnosis. *J Crohns Colitis* 2008; 2(1): 1-23.
- Dejaco C, Oesterreicher C, Angelberger S, Püspök A, Birner P, Poetzi R, Gangl A, Oberhuber G. Diagnosing colitis: a prospective study on essential parameters for reaching a diagnosis. *Endoscopy* 2003; 35(12): 1004-1008.
- Miehlsler W, Reinisch W, Valic E, Osterode W, Tillinger W, Feichtenschlager T, Grisar J, Machold K, Scholz S, Vogelsang H, Novacek G. Is inflammatory bowel disease an independent and disease specific risk factor for thromboembolism? *Gut* 2004; 53(4): 542-548.
- Hudson M, Chitolie A, Hutton RA, et al. Thrombotic vascular risk factors in inflammatory bowel disease. *Gut* 1996; 38(5): 733-737.
- Kao A, Dlugos D, Hunter JV, Mamula P, Thorarensen O. Anticoagulation therapy in cerebral sinovenous thrombosis and ulcerative colitis in children. *J Child Neurol* 2002; 17(7): 479-482.
- Al-Malik H, Green MR. Cerebral venous thrombosis as a complication of Crohn disease: a case report. *J Pediatr Gastroenterol Nutr* 2001; 32(2): 209-211.
- Guerra Montero LJ, Ingver A, Casañas A, Sosa C, Iade B. Clinical characteristics of patients with inflammatory bowel disease and thromboembolic events. *Acta Gastroenterol Latinoam* 2010; 40(2): 134-141.
- Sébire G, Tabarki B, Saunders DE, Leroy I, Liesner R, Saint-Martin C, Husson B, Williams AN, Wade A, Kirkham FJ. Cerebral venous sinus thrombosis in children: risk factors, presentation, diagnosis and outcome. *Brain* 2005; 128(3): 477-489.
- Barclay AR, Keightley JM, Horrocks I, Garrick V, McGrogan P, Russell RK. Cerebral thromboembolic events in pediatric patients with inflammatory bowel disease. *Inflamm Bowel Dis* 2010; 16: 677-683.
- Huber W, Herrmann G, Schuster T, Phillip V, Saugel B, Schultheiss C, Hoellthaler J, Gaa J, Hartel M, Schmid RM, Reindl W. Life-threatening complications of Crohn's disease and ulcerative colitis: a systematic analysis of admissions to an ICU during 18 years. *Dtsch Med Wochenschr* 2010; 135(14): 668-674.
- Scaldaferri F, Lancellotti S, Pizzoferrato M, De Cristofaro R. Haemostatic system in inflammatory bowel diseases: new players in gut inflammation. *World J Gastroenterol* 2011; 17(5): 594-608.
- Saibeni S, Saladino V, Chantarangkul V, Villa F, Bruno S, Vecchi M, de Franchis R, Sei C, Tripodi A. Increased thrombin generation in inflammatory bowel diseases. *Thromb Res* 2010; 125(3): 278-282.
- Bernhard H, Deutschmann A, Leschnik B, Schweintzger S, Novak M, Hauer A, Muntean W. Thrombin generation in pediatric patients with Crohn's disease. *Inflamm Bowel Dis* 2011; 17(11): 2333-2339.
- Murch SH, Braegger CP, Walker-Smith JA, MacDonald TT. Location of tumour necrosis factor alpha by immunohistochemistry in chronic inflammatory bowel disease. *Gut* 1993; 34(12): 1705-1709.
- Murch SH. Sulphation of proteoglycans and intestinal function. *J Gastroenterol Hepatol* 1995; 10(2): 210-212.
- Urgesi R, Zampalatta C, Masini A, Pelecca G, Pastorelli A, De Lorenzo A, Faggiani R. Spontaneous right ventricular thrombus in a patient with active ulcerative colitis and protein C deficiency: a review with a case report. *Eur Rev Med Pharmacol Sci* 2010; 14(5): 455-463.
- Twig G, Zandman-Goddard G, Szyper-Kravitz M, Shoenfeld Y. Systemic thromboembolism in inflammatory bowel disease: mechanisms and clinical applications. *Ann N Y Acad Sci* 2005; 1051: 166-173.
- Danese S, Papa A, Saibeni S, Repici A, Malesci A, Vecchi M. Inflammation and coagulation in inflammatory bowel disease: The clot thickens. *Am J Gastroenterol* 2007; 102(1): 174-186.
- Akbulut S, Altıparmak E, Topal F, Ozaşlan E, Kucukazman M, Yonem O. Increased levels of homocysteine in patients with ulcerative colitis. *World J Gastroenterol* 2010; 16(19): 2411-2416.
- Turri D, Rosselli M, Simioni P, Tormene D, Grimaudo S, Martorana G, Siragusa S, Mariani G, Cottone M. Factor V Leiden and prothrombin gene mutation in inflammatory bowel disease in a Mediterranean area. *Digest Liver Dis* 2001; 33(7): 559-562.
- Papa A, Danese S, Grillo A, Gasbarrini G, Gasbarrini A. Review article: inherited thrombophilia in inflammatory bowel disease. *Am J Gastroenterol* 2003; 98(6): 1247-1251.
- Wakefield A, Cohen Z, Levy G. Procoagulant activity in gastroenterology. *Gut* 1990; 31(2): 239-241.
- Ertem D, Ozguven E, Acar Y, Alper G, Pehlivanoglu E. Thromboembolic complications in children with Crohn's disease. *J Pediatr Gastroenterol Nutr* 1999; 28(5): 540-541.
- Yakaryılmaz F, Guliter S, Degertekin B, Tuncer C, Unal S. Cerebral sinus thrombosis in a patient with active ulcerative colitis and double heterozygosity for Factor V Leiden and prothrombin gene mutations. *Neurol India* 2009; 57: 188-190.
- Kupfer SS, Rubin DT. Inflammatory bowel disease and cerebral venous sinus thrombosis. *Gastroenterology and Hepatology* 2006; 2: 917.
- Koutroubakis IE. Therapy insight: vascular complications in patients with inflammatory bowel disease. *Nat Clin Pract Gastroenterol Hepatol* 2005; 2(6): 266-272.
- deVeber G, Chan A, Monagle P, et al. Therapy in pediatric patients with sinovenous thrombosis: a cohort study. *Arch Neurol* 1998; 55(12): 1533-1537.
- Roach ES, Golomb MR, Adams R, Biller J, Daniels S, Deveber G, Ferriero D, Jones BV, Kirkham FJ, Scott RM, Smith ER; American Heart Association Stroke Council; Council on Cardiovascular Disease in the Young. Management of stroke in infants and children: a scientific statement from a Special Writing Group of the American Heart Association Stroke Council and the Council on Cardiovascular Disease in the Young. *Stroke* 2008; 39(9): 2644-2691.
- deVeber GA, MacGregor D, Curtis R, Mayank S. Neurologic outcome in survivors of childhood arterial ischemic stroke and sinovenous thrombosis. *J Child Neurol* 2000; 15(5): 316-324.
- De Veber G, Andrew M, and the Canadian Pediatric Ischemic Stroke Study Group. The epidemiology and outcome of sinovenous thrombosis in pediatric patients. *N England J Med* 2001; 345: 417-423.
- Murata S, Ishikawa N, Oshikawa S, Yamaga J, Ootsuka M, Date H, Kitani M, Inatsu H, Eto T. Cerebral sinus thrombosis associated with severe active ulcerative colitis. *Intern Med* 2004; 43(5): 400-403.