

A seven-year-old boy with a tumour on his right upper leg

Mehmet Hanifi Okur¹, Ibrahim Uygun¹, Hayati Güneş², İlyas Yolbaş³, Selçuk Otçu¹

¹Dicle University, Medical Faculty, Department of Pediatric Surgery, Diyarbakır, Turkey

²Namık Kemal University, Medical Faculty, Department of Medical Microbiology, Tekirdağ, Turkey

³Dicle University, Medical Faculty, Department of Pediatric Surgery, Diyarbakır, Turkey

Case

A 7-year-old boy living in a rural area presented with a complaint of swelling in the right upperleg which was present for 1.5 years, but increased in size in the last 3 months and caused pain and difficulty in walking. On physical examination, a soft mass of 4x6 cm without erythema was found in the adductor region of the right thigh. The patient had no history of trauma, surgery or disease.

Eosionphilia (15.4%), leucocytosis (14000/mm³) and a CRP value of 37.7 mg/dL were found in the laboratory tests.

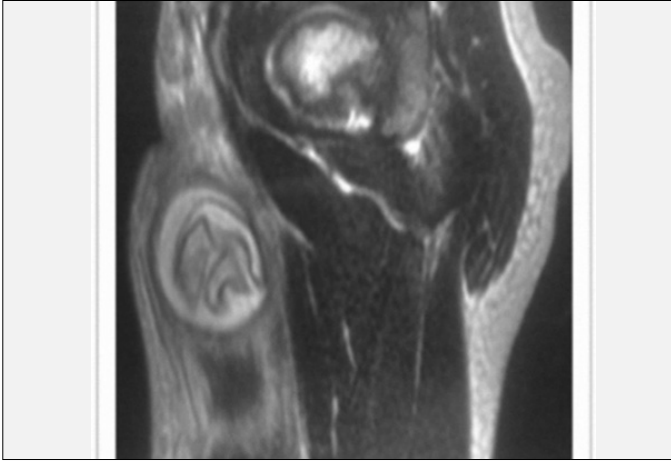
Ultrasonography (USG) revealed a lesion area with a size of 24x44 mm including extensive internal septations with a thick capsule localized in the muscle in the anterior-medial region of the right thigh compatible with cystic criteria. At this stage, necessary blood tests and magnetic resonance imaging were performed.

Diagnosis: Hydatid cyst

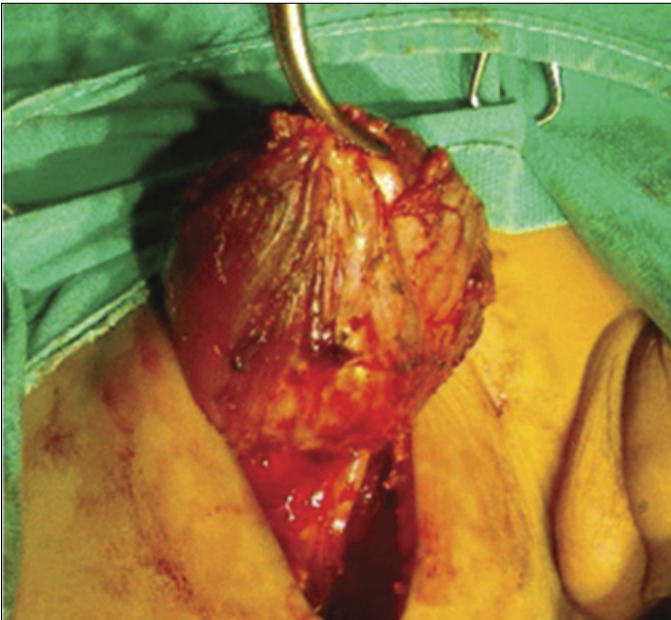Elisa test performed for echinococcus was found to be positive.

Magnetic resonance (MR) imaging revealed a cystic lesion with regular borders with a size of 28x44 mm including internal septations in the anterior-medial region of the right thigh (Hydatid cyst?). The lesion was hypodense on T1 weighted images, hyperdense on T2 weighted images and showed no marked contrast uptake following IV contrast injection. Contrast uptake was observed in the peripheral region of the lesion (inflammation) (Picture 1).

Postoperatively, 10 mg/kg albendazole was given for 10 days. After obtaining informed consent from the patient operation was performed under general anesthesia and it was observed that the cyst was localized between adductor and sartorius muscles.



Resim 1. Sağ uyluk bölgesi MR görüntüleme



Resim 2. Kitlenin tümünün çıkarılışı

The cystic mass was excised completely without damaging the mass (Picture 2) and the area was rinsed with hypertonic saline. Afterwards, the mass was opened and it was observed that germinative membrane and hydatid fluid were present (Picture 3). No problem occurred postoperatively. The patient was given 10 mg/kg/day albendazole for three months.

Discussion

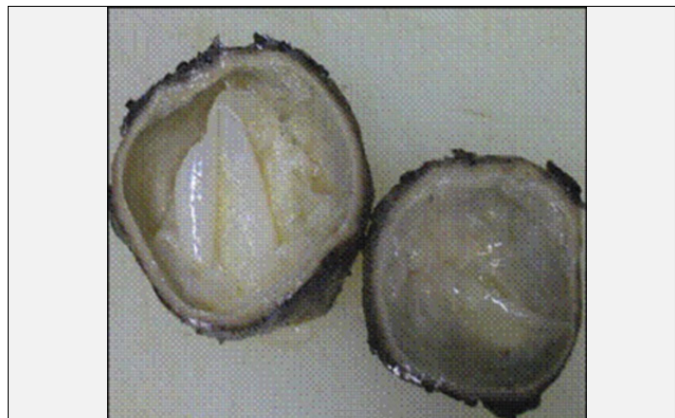Hydatosis is a parasitic infection known since the old times. Four different parasites lead to this disease. These include *Echinococcus granulosus*, *E. Multilokularis*, *E. Vogeli* ve *E.oligarthus*. The first two have clinical significance. The other two parasites rarely cause infection in humans (1). The disease is endemic in many regions including Mediterranean countries, the Middleeast, Australia and South America. The annual incidence in Turkey is 12/100000 (2).

Hydatid cyst is found with a rate of 64% in the lungs and with a rate of 28% in the liver in children. In addition, the brain, peritoneal cavity, spleen, heart and bone can also be involved (3). It is believed that primary infection occurring in the muscle tissue in the childhood is due to *E. Granulosus*. It is observed rarely in children and frequently in the adulthood, because the cyst grows slowly and symptoms arise in later years (4).

Primary skeletal muscle hydatid cyst is observed rarely (with a rate of 0.5-4.7%). The cyst uses oxygen to grow. However, muscles contain lactic acid and this environment is not appropriate for the growth of the cyst (4). The pathogenesis related to skeletal muscle localization of hydatid cyst has not been elucidated fully. Some authors propose that it occurs by bite of an infected dog and some others propose that the embryo reaches the skeletal muscle after passing two organs acting as filters namely the lungs and liver (7).

There are approximately 60 cases of primary skeletal muscle hydatid cyst reported in the literature and the patients are mostly adults (5). It occurs very rarely in children (69).

It is difficult to diagnose primary intermuscular hydatid cyst except for endemic areas. Abscess, hematoma, soft tissue tumor and other lesions should be considered in the differential diagnosis. Biopsy should not be performed, since it would be



Resim 3. Kitle içinde jermatif membran

harmful in terms of leading live scolexes to enter the circulation and causing anaphylaxis by extending and infecting other compartments. Therefore, primarily imaging is very important in swellings (8).

Our patient is the second pediatric case reported in the literature with its intermuscular localization and a size of 5 cm.

Although muscular hydatid cyst is observed rarely, it is still important in urban regions in endemic areas. Radiologic imaging tests and serologic tests may be helpful in the diagnosis of muscular hydatid cyst with an extraordinary localization. It may sometimes be confused with abscess on ultrasonography. Marked hypodense borders of the hydatid cyst can be observed on MRI (9).

Serologic tests can be used to confirm the diagnosis. The common techniques used include indirect immunofluorescence antibody test, ELISA, immunoelectrophoresis and immunoblast tests (10). The diagnosis of our patient was confirmed radiologically, serologically and histopathologically.

Conclusively, hydatid cyst should not be ignored in patients presenting with cystic mass in areas where hydatid cyst occurs endemically and radiologic and serologic tests for hydatid cyst would be performed before performing biopsy. If hydatid cyst is considered, the cyst should be excised totally and drainage should not be done.

References

1. Merkle EM, Schulte M, Vogel J, Tomczak R, Rieber A, Kern P, Goerich J, Brambs HJ, Sokiranski R. Musculoskeletal involvement in cystic Echinococcosis: report of eight cases and review of the literature. *AJR Am Roentgenol* 1997;168:1531-1534.
2. Republic of Turkey Ministry of Health. Health statistics. Ankara: Research planning and Coordination Council; 1997.
3. Tsakayiannis E, Papis C, Moussatos G. Late result of the conservative surgical procedures in hydatid disease of the lung in children. *Surgery* 1970; 68: 379-382.
4. García-Díez AI, Ros Mendoza LH, Villacampa VM, Cózar M, Fuertes MI. MRI evaluation of soft tissue hydatid disease. *Eur Radiol* 2000; 10: 462-466.
5. Mseddi M, Mtaoumi M, Dahmene J, Ben Hamida R, Siala A, Moula T, Ben Ayeche ML. Hydatid cyst in muscles: eleven cases, *Rev Chir Orthop Reparatrice Apar Mot* 2005; 91: 267-271.
6. Cankorkmaz L, Ozturk H, Koyluoglu G, Atalar MH, Arslan MS. Intermuscular hydatid cyst in a 4-year-old child: a case report. *J Pediatr Surg* 2007; 42: 1946-1948.
7. Melis M, Marongiu L, Scintu F, Pisano M, Capra F, Zorcolo L, Casula G. Primary hydatid cyst of psoas muscle. *ANZ J Surg* 2002; 72: 443-445.
8. Duncan GJ, Tooke SM. Echinococcus infestation of the biceps brachii. A case report. *Clin Orthop Relat Res* 1990; 261: 247-250.
9. Pedrosa I, Saiz A, Arrazola J, Ferreiro J, Pedrosa CS. Hydatid disease: radiologic and pathologic features and complications. *Radiographics* 2000; 20: 795-817.
10. Zhang W, Li J, McManus DP. Concept in immunology and diagnosis of hydatid disease. *Clin Microbiol Rev* 2003; 16: 18-36.