

A case of Edward's syndrome with esophageal atresia and meningocele

Selvi Gülaşı, Ali Haydar Turhan, Yalçın Çelik, Etem Akbaş, Aytuğ Atıcı

Mersin University Department of Pediatrics, Mersin, Türkiye

Summary

Most patients die within one year of age in Edward's syndrome. More than 130 different anomalies have been reported in infants with trisomy 18. A female preterm infant weighing 1400 grams was presented, because esophageal atresia together with meningocele has not been reported to date in Edward's syndrome. (*Turk Arch Ped* 2011; 46: 167-9)

Key words: Esophageal atresia, meningocele, newborn, trisomy 18

Introduction

Edward's syndrome (Trisomy 18) which is the second most common syndrome among otosomal trisomies after Down syndrome has an incidence of 1/6000-1/8000 live births (1). Specific findings include intrauterine growth retardation, dismorphic head, micrognathism, short neck, low ear position, small mouth, flexion disorder in the fingers, external prominence of the heels, inguinal hernia, narrow pelvis and cardiac and renal structural disorders (2). Most babies die during the neonatal period (80%) and others die during the first year of life frequently because of cardiac disorders (3). In surviving infants, mental retardation is observed which is more severe in girls (4). The syndrome is reported to be more frequent in girls (5).

More than 130 structural anomalies accompanying Edward's syndrome have been reported and esophageal atresia and meningocele are among the rarely observed findings. However, association of esophageal atresia and meningocele which are two rare findings has not been found in the reported cases. Therefore, we considered our case to be worth presenting.

Case report

A baby born at the 40th week by cesarean section from a healthy and 22 years old mother was referred to

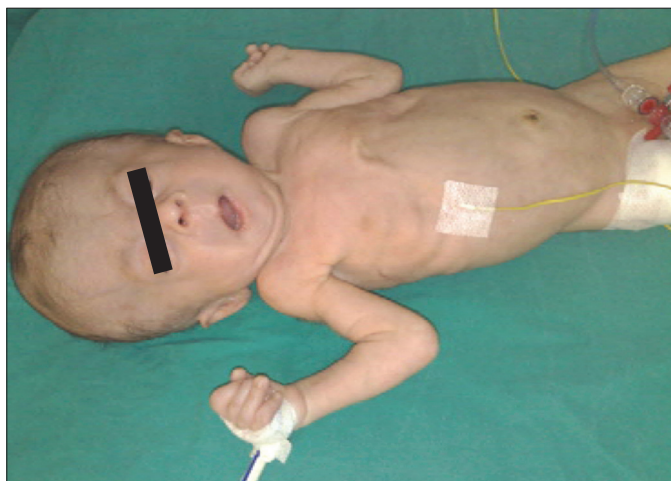our hospital with respiratory distress and suspicious esophageal atresia. Physical examination revealed the following: body weight: 1400 grams (<3%), height: 40 cm (<3%), head circumference: 30 cm (<3%), body temperature measured in the axilla: 36,7 °C, apical heart beat: 160/min, respiratory rate: 70/min and blood pressure: 70/40 mmHg. General state was not well, findings of marked respiratory distress were present. Ears had a low position and were dysmorphic, micrognathism and short and webbed neck were present (Picture 1). A meningocele with dimensions of 5 x 5 cm was present in the occipital region (Picture 2). The index finger was overlapped on the middle finger in both hands (Picture 3). The second and third toes were adhered to each other and external prominence of the heels were noted (Picture 4). Respiratory sounds could be heard equally in both sides of the chest and crepitan ralles were heard on both sides. A systolic murmur of II/VI^o was present at the mesocardiac area. Examination of other systems revealed no pathology.

Chromosome analysis was found to be 47, XX+18 (Picture 5).

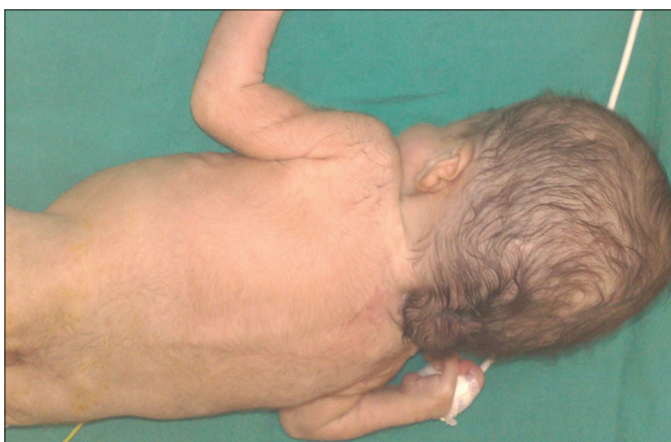Echocardiographic examination revealed patent ductus arteriosus and ventricular septal defect (VSD);

cranial magnetic resonance imaging revealed occipital meningocele, thinning of corpus callosum, Dandy Walker variant; chest tomography revealed high left diaphragma and esophageal graphy with barium revealed esophageal atresia. Other laboratory tests were found to be normal.

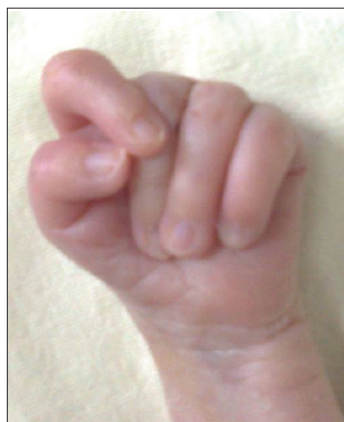The infant was internalized in the neonatal intensive care unit and intubated. Ventilatory support was provided. Esophageal atresia and accompanying tracheoesophageal fistula were corrected adequately. No problem related to the operation was experienced. Patent ductus arteriosus was closed by giving oral ibuprofen. Lung infection and cardiac failure developed during the follow-up. Although appropriate antibiotics and inotropic treatment were administered, full recovery could not be achieved and oxygen requirement persisted. The infant was referred to a secondary care neonatal unit for maintenance of care and treatment on the 102nd day of life by receiving informed consent from the family. Genetic consultancy was provided for the family.



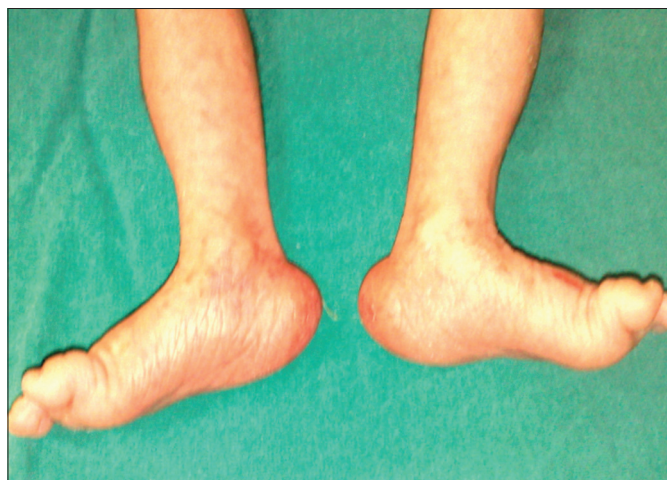Picture 1: General appearance of the infant diagnosed as Edward's syndrome



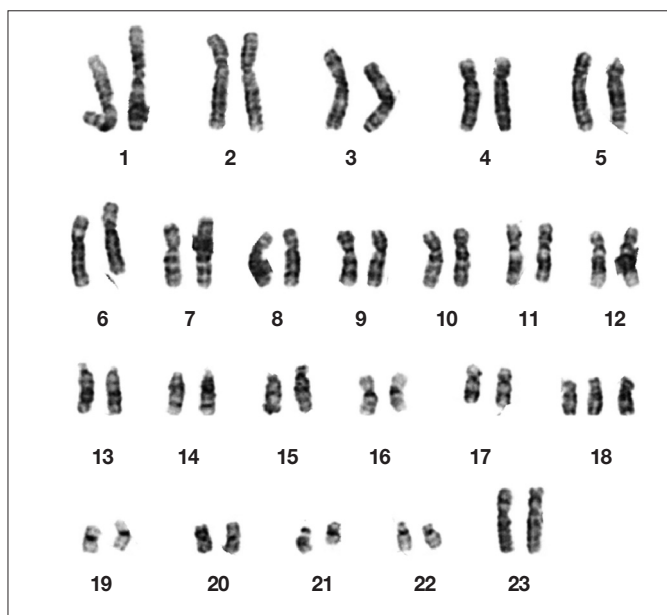
Picture 2: Meningocele in the occipital region



Picture 3: Flexion anomaly of the fingers



Picture 4: External prominence of the heels



Picture 5: Cariotype of our patient demonstrating 47,XX+18 anomaly

Discussion

Edward's syndrome was defined by Edward and his colleagues for the first time in 1960 (6). This syndrome is accompanied by severe disorders in many organs. While the expected survival rate at the end of the first month is 38,6%, this rate decreases to 8.4% at the end of the first year of life. Mean life time has been reported to be 14,5 days (7). In the surviving infants, severe retardation of growth and development occur. The longest survival time reported until the present time is 50 years (8). 80% of the cases were reported to be female as in our case (9).

Edward's syndrome occurs because of non-disjunction of the 18.th chromosome during meiosis of the reproductive cells of the mother and the father. It is thought that advanced maternal age, environmental factors and low socioeconomic level play a role (10). Advanced maternal age was not present in our case, but socioeconomic level of the family was low.

Polyhydramnios, disproportionally small placenta, single umbilical artery, intrauterine growth retardation and decreased fetal movements during the prenatal period indicate suspicious Edward's syndrome. Since the mother of our case did not receive medical care during pregnancy, the presence of such findings could not be demonstrated.

Edward's syndrome is accompanied by multiple structural disorders and esophageal atresia is one of the rare disorders accompanying this syndrome. Trisomy 18 is found in 1% of patients with esophageal atresia (11). A case of Edward's syndrome with partial absence of corpus callosum associated with esophageal atresia was reported (12). Esophageal atresia and thinning of corpus callosum associated with tracheoesophagal fistula was found in our patient.

In 97% of cases with trisomy 18, structural disorders are found at least in three organs. In Edward's syndrome, VSD has been reported with a rate of 67%, underdevelopment of reproductive organs has been reported with a rate of 50%, horseshoe kidney has been reported with a rate of 32%, omphalocele has been reported with a rate of 14%, diaphragm hernia has been reported with a rate of 11% and esophageal atresia has been reported with a rate of 11% (13). Only two cases accompanied by meningocele have been reported (14, 15). However, Edward's syndrome associated with two rare findings including esophageal atresia and meningocele has not been

reported. In our case, esophageal atresia, meningocele and thinning of corpus callosum which are rare findings in trisomy 18 were found in association. By presenting this interesting and rare association we aimed to draw attention to the subject.

Conflict of interest: None declared

References

1. Smith DM. Trisomy 18 Syndrome. In: Jones KL ed. Smith's Recognizable Patterns of Human Malformations. 4th ed. Philadelphia: Saunders, 1988: 16-9.
2. Descartes M, Carroll AJ. Cytogenetics. In: Behrman RE, Kliegman RM, Jenson HB, Stanton BF, (eds). Nelson Textbook of Pediatrics 18th ed. Philadelphia: Saunders, 2007: 510-1.
3. Tekin N, Akşit A, Gürpınar M. Trizomi 18 sendromlu bir olguda unilateral radius aplazisi. Perinatoloji dergisi 2001; 9: 262-4.
4. Baty BJ, Blackburn BL, Carey JC. Natural history of trisomy 18 and trisomy 13: I. Growth, physical assessment, medical histories, survival and recurrence risk. Am J Med Genet 1994; 49: 175-88.
5. Pant SJ, Robbins JM, Bird TM, et al. Congenital malformations among liveborn infants with trisomy 18 and 13. Am J Med Genet A 2006; 140:1749-56.
6. Edwards Jh, Harnden Dg, Cameron Ah, Crosse Vm, Wolff Oh. A new trisomic syndrome. Lancet 1960; 1: 787-90.
7. Weber WW. Survival and sex ratio in trisomy 17-18. Am J Hum Genet 1976; 19: 369-77.
8. Bhanumathi B, Neelam AG, Mishro ZA. Trisomy 18 in a 50 year old female. Indian J Hum Genet 2006; 12: 146-7.
9. Parker MJ, Budd JL, Draper ES, Young ID. Trisomy 18 in a defined populations: epidemiological, genetic and prenatal observations. Prenat Diagn 2003; 23: 856-60.
10. Naguib KK, Al-Awadi SA, Bastaki L, et al. Clustering of trisomy 18 in Kuwait: genetic predisposition or enviroental? Ann Saudi Med 1999; 19: 197-200.
11. Gonzales-Zamora JF, Villegas-Alvares F. Esophagial atresia and chromosomal abnormalities in a Mexican children population: descriptive analysis. Cir Pediatr 2005; 18: 196-9.
12. Suranyi A, Bito T, Vojda G, et al. Unusual clinical history of a male infant with Edward's syndrome. Pathol Oncol Res 2009; 15: 147-52.
13. Steffensen TS, Opitz JM, Gilbert-Barness E. Congenital perineal hernia in a fetus with trisomy 18. Fetal Pediatr Pathol 2009; 28: 95-9.
14. Bick D, Markowitz RI, Horwich A. Trisomy 18 associated with ectopia cordis and occipital meningocele. Am J Med Genet 1988; 30: 805-10.
15. Scorta A, Franceschini P, Pilotti G. [On a case of trisomy 18 with spina bifida and meningocele]. Minerva Ginecol 1966; 18: 31-6.