



Histological Changes in *Oreochromis niloticus* (Linnaeus 1779) Exposed to Aqueous Extract of *Moringa oleifera* Seeds Powder

E.O. Ayotunde^{1*}, O.A. Fagbenro², O.T. Adebayo²

¹ Cross River University of Technology, Department of Fisheries, PMB 102, Obubra. Cross River State, Nigeria.

² Federal University of Technology, Department of Fisheries and Wildlife, PMB 704 Akure, Ondo State, Nigeria.

* Corresponding Author: Tel.: +080.697 98920; Fax: +080.697 98920;
E-mail: eoayotunde@yahoo.co.uk

Received 10 July 2009
Accepted 30 September 2010

Abstract

This research determined the pathological effects of *Moringa oleifera* seed powder, a natural alternative to alum, used as a water purifier in fish culture enclosure in Nigeria. The histological changes in gill, liver, skin and kidney of fingerling and adult Nile tilapia *Oreochromis niloticus* exposed to aqueous extract of *Moringa oleifera* seed at different sub-lethal concentration under static bioassay procedure are described. There were pathologic lesions observed which included different levels of cells degeneration in the gill, lamellar hyperemia; hypertrophy of gill arch occurred, while hyperplasia, disarrangement of hepatic cell, necrosis, and vacuolation occurred in fish liver and kidney. Damages of different organs became severe with increasing concentration of aqueous extract of *M. oleifera* seeds and time of exposure.

Keywords: Histology, *Moringa oleifera*, Nile tilapia, water quality.

Toz Halindeki *Moringa oleifera* Tohumunun Sulu Ekstresine Maruz Bırakılan *Oreochromis niloticus*'te (Linnaeus 1779) Histolojik Değişiklikler

Özet

Bu çalışmada; Nijerya'da balık kültüründe su arıtıcısı olarak kullanılan doğal şapa bir alternatif olarak, toz halindeki *Moringa oleifera* tohumu kullanımının patolojik etkilerini tespit etmiştir. Statik deneme prosedüründe, farklı subletal konsantrasyonda *Moringa oleifera* tohumunun sulu ekstresine maruz kalan Nil tilapyası, *Oreochromis niloticus* yavru ve erginlerinin solungaç, deri ve böbreğindeki histolojik değişiklikler tespit edilmiştir. Solungaçta farklı seviyelerde hücre dejenerasyonu, lamellerde hiperemi, solungaç yayında hipertrofi, diğer taraftan hiperplazi, hepatik hücre düzensizliği, nekroz; balık karaciğerinde ve böbreğinde meydana gelen vakuolleşme gibi patolojik lezyonlar gözlenmiştir. *M. Oleifera* tohumunun sulu ekstresinin konsantrasyonunun ve maruz bırakılma süresinin artmasıyla farklı organlardaki hasarlar ağırlaşmıştır.

Anahtar Kelimeler: Histoloji, *Moringa oleifera*, Nil tilapıyası, su kalitesi.

Introduction

Nile tilapia, *Oreochromis niloticus* is surface-feeding omnivore fish belong to the family Cichlidae. They are the most popular fish for culture in Nigeria and worldwide. They grow fast, mature quickly, and breed easily without inducement. Apart from their special interest for fish biologist and taxonomists, tilapia contribute significantly to African inland water fisheries and are very good species for aquaculture (Huisman and Richter, 1987; Haylor, 1993; Fagbenro *et al.*, 1993).

Moringa oleifera Lam. (Moringaceae) (Drustick, horse radish) is a multipurpose tree that thrives in both tropical and sub-tropical (Foidl *et al.*, 2001). *M. oleifera* seed is a good water purifier; it

leaves water clear with 90-99% of the bacteria removed. It contains polyelectrolytes, which constitute active ingredients in water treatment (Jahn, 1986). Eilert *et al.* (1981) isolated 4 α L-rhamnosyloxy-benzyl isothiocyanate the active ingredient and active antimicrobial agent in *Moringa* seeds, *Moringa* seed powder can also be used to harvest algae (common fish food) from wastewater (Acquaye *et al.*, 2000). *M. oleifera* seed powder has been successfully used as water purifier but little work has been done on their toxicity to an important cultivable fish species (Ayotunde *et al.*, 2005; 2006). This research examined the histopathological effect of *M. oleifera* to Nile tilapia and it will serve as baseline information for the application of the toxicant in the aquatic environment.

Materials and Methods

This experiment was conducted under standard static bioassay procedure (Reish and Oshida, 1987; AOAC, 1987). This involves carefully controlled environmental conditions as to define the response of the test organism to *Moringa* seed powder. Apparently healthy adult fish (15.8-17.9 cm total length; 89.6-105.6 g) were collected from Ministry of Agriculture And Natural Resources fish farm Akure, Ondo State, Nigeria, and acclimated for 1 week in the laboratory inside transparent rectangular glass tanks (75 x 45 x 45 cm) filled with 50 litres of well dechlorinated water. Fish were fed with 35% crude protein diet during the acclimation period. Fish feeding was stopped 48 hours before the commencement of the experiment to minimize the production of waste in the test container.

Large quantities of freshly mature seeds of *M. oleifera* were obtained from the premises of Federal Prison Yard Obubra, Cross River State, Nigeria. The seed powder was prepared according to the method described by Price (2000) where the seed was sun dried, and seed coats and wings were manually removed. The white kernel was ground to a fine powder, using the coffee mill attachment of a moulinex domestic food bender and the powder was kept in desiccators for using later in stock solutions. A stock solution of seed powder was prepared by adding 1.0 g of *M. oleifera* in 1 litre of distilled water according to Olaifa et al. (2003).

Preliminary 24-hour's range finding test was conducted for adult fish following static bioassay procedures described by Parrish (1985), to determine the toxic range of aqueous extracts of *Moringa oleifera* seeds to fish. Ten adult fish were group-weighted and distributed into a set of 18 rectangular glass tanks (75 x 45 x 45 cm) each filled with 50 litres of well dechlorinated water, and allowing one hour for acclimation to laboratory conditions. The water was filtered and aerated for saturation, prior to use. Six stock solutions each of aqueous extracts of *Moringa oleifera* seeds were prepared by 250, 300, 350, 400, or 450 mg/L with a control of 0 mg/L in distill water. Each of the stock solutions was introduced directly into the glass tanks in a single dose, representing six triplicates treatments per fish. The fish behaviour and mortality in each tank was monitored and recorded for 24 hours.

Based on the results of lethal toxicity test described above, 96 hours definitive (sub-lethal toxicity) tests following static bioassay procedures described by Parrish (1985) was carried out using the same technique as previously described. Six stock solutions each of aqueous extracts of *M. oleifera* was prepared by dissolving 300, 310, 320, 330, 340, and 350 mg/L. Each of the stock solution was introduced in a single dose directly into the glass tanks. Continuous aeration was provided to prevent hyper concentration and to maintain dissolved oxygen near

saturation throughout the test and the test fish were not fed throughout these 96 hour tests to reduce the production of waste material in test containers during the experiment.

At the end of the experiment, three fish per treatment, that is, three fish per concentration were sampled after 96 hours of exposure for histological analysis. The test fish was killed with a blow on the head, using a mallet and was dissected to remove the kidney, gill, liver, and skin. The organs were fixed in 10% formalin for three days after that the tissue was dehydrated in periodic acid Schiff's reagent (PAS) following the method of Hughes & Perry (1976) in graded levels of 50%, 70%, 90% and 100% alcohol for 3 days, to allow paraffin wax to penetrate the tissue during embedding. The organs were then embedded in malted wax. The tissue was sectioned into thin sections (5-7 μ m) by a rotatory microtome and were dehydrated and stained with Harris haematoxylin-eosin (H&E) stain (Bancroft & Cook 1994), using a microtome and each section was cleared by placing in warm water (38°C), where it was picked with clean slide and oven-dried at 58°C for 30 minutes to melt the wax. The slide containing sectioned materials/tissue was cleared using xylene and graded levels of 50%, 70%, 90%, 95% and 100% alcohol for two minutes each. The section was stained in haematoxylin eosin for ten minutes. The stained slide was observed under a light microscope at x100 magnification. Sections were examined and photographed using an Olympus BH2 microscope fitted with photographic attachment (Olympus C35 AD4), a camera (Olympus C40 AB-4) and an automatic light exposure unit (Olympus PM CS5P).


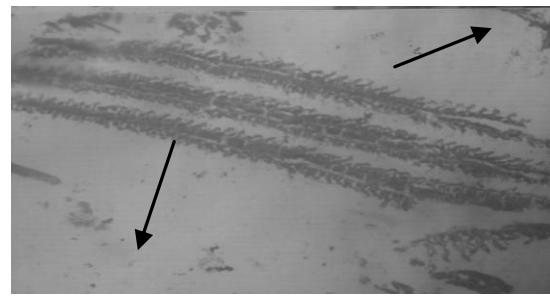
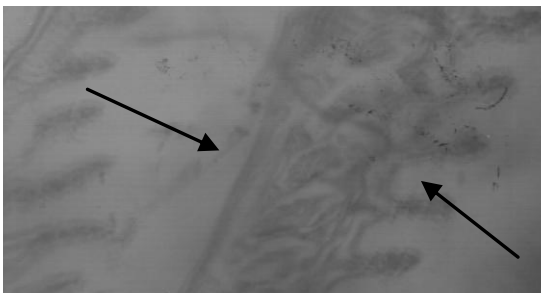
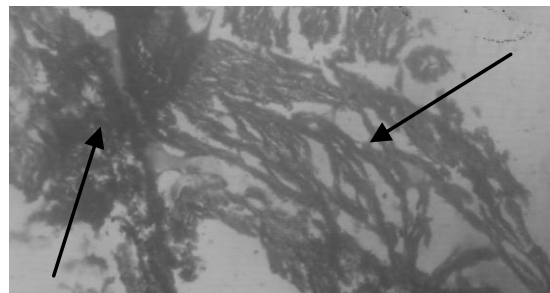
Results and Discussions

The results presented in Table 1 summarized the histological changes observed in adults Nile tilapia exposed to different concentrations of aqueous extract of *Moringa oleifera*.

The results presented in Table 1 and Plate A-D represents the histological changes observed in adult tilapia treated with 300, 310, 320, 330, 340, 350 and 0mg/l as control. Histopathological changes in the gill, skin, liver, and kidney were observed for all the treatments. Lesions were essentially similar for all treatments and exposure time, although the intensity of cell damage increased with increasing concentration and time of exposure. The normal histology of the gill structure of adult tilapia exposed to 0 mg/L of *Moringa oleifera* is showing in Figure 1. Following the exposure to aqueous extract of *Moringa oleifera*, changes in histological structure were noted particularly in the filament and lamellae. Figure 2. shows half of the gill arch have it filament and lamellae degenerated in fish treated with 300mg/l. Hypertrophy of the gill arch, degenerated gill filament and lamellae (Figure 3) observed at 310 mg/L of *M. oleifera*. Figure 4 shows the central parts of the gill

Table 1. Histological changes observed in adult Nile tilapia exposed to different concentrations of *Moringa oleifera*

Const. (mg/L)	Gills	Skin	Liver	Kidney
Control	Normal gill no pathological lesion observed.	Normal skin no pathological lesion observed	Normal liver no pathological lesion observed	Normal kidney no pathological lesion observed
300	Half of the gill arch have it filament and lamellae degenerated.	Normal skin no pathological lesion observed	Disarrangement of hepatic cell	Normal kidney no pathological lesion observed
310	Hypertrophy of the gill arch and degenerated gill filament and lamellae	Normal skin no pathological lesion observed	Vacuole formation	Normal kidney no pathological lesion observed
320	The central parts of the gill arch have both the lamellae and filament degenerated while those at both end not affected.	Necrosis and erosion of dermal cell of the skin	Necrosis and thickening of the hepatocyte cell	Hyperplasia cell and vacuole formation
330	High degenerated lesion observed at the gill arch, filament, and lamellae.	Total erosion of dermal layer.	Necrosis and thickening of the hepatocyte cell	Shrinkages of hepatocytes cell
340	Hypertrophy of gill arch and degenerated gill filament.	Erosion of dermal layer and vacuole formation.	At X40 the karyolysis of the hepatocyte.	Total degeneration of the cell
350	Complete degenerated of gill arch and filaments.	Complete degeneration of cell.	Necrosis and faded hepatic cell.	Total degeneration of the cell

**Figure 1.** Histological changes showing normal gill no pathological lesion observed.**Figure 2.** Half of the gill arch have it filament and lamellae degenerated.**Figure 3.** Hypertrophy of the gill arch and degenerated gill filament and lamellae.**Figure 4.** The central parts of the gill arch have both the lamellae and filament degenerated while those at both end not affected.

arch have both the lamellae and filament degenerated, while those at both end not affected in fish treated with 320 mg/L of *Moringa oleifera*. High degenerated lesion (Figure 5) observed at the gill arch, filaments, and lamellae in concentration of 330 mg/L. Hypertrophy of gill arch and degenerated gill filament (Figure 6) in concentration of 34 mg/L within 96 hours exposure period. Complete degenerated filaments and gill arch (Figure 7) was recorded in highest concentration of 350 mg/L within 96 hours

exposure period.

Figures 8-14 shows the pathological changes observed in skin of adult Nile tilapia. Figure 8-10 show normal skin and no pathological lesion was observed in concentrations of 0 mg/L, 300 mg/L, and 310 mg/L of *Moringa oleifera* treated fish. Necrosis and erosion of dermal cell of the skin (Figure 11) was observed at 320 mg/L of *Moringa*-treated fish. Figure 12 shows total erosion of dermal layer in concentration of 330 mg/L of *Moringa* treated fish.




Figure 5. High degenerated lesion observed at the gill arch, filament, and lamellae.

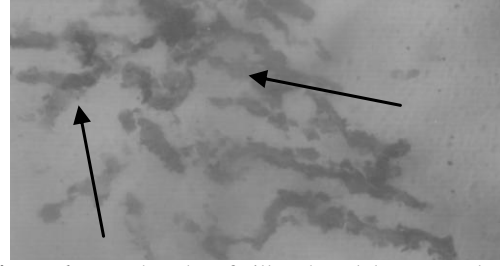


Figure 6. Hypertrophy of gill arch and degenerated gill filament.




Figure 7. Complete degenerated filaments.




Figure 8. Normal skin no pathological lesion observed.




Figure 9. Normal skin no pathological lesion observed.




Figure 10. Necrosis of dermal cell of the skin.

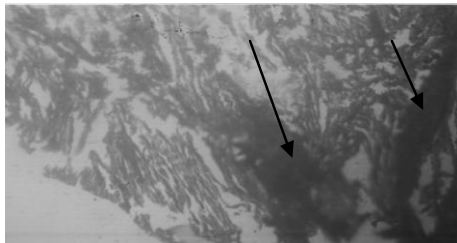


Figure 11. Necrosis and erosion of dermal cell of the skin.

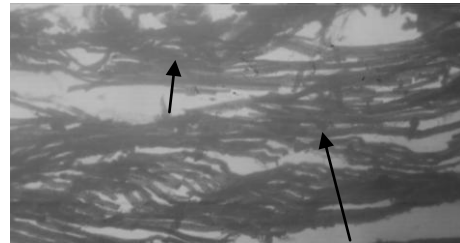


Figure 12. Total erosion of dermal layer.

The erosion of dermal layer and vacuole formation was recorded in concentration of 340 mg/L, while Figure 14 shows complete degeneration of cell in highest concentration of 350 mg/L of *Moringa oleifera* treated fish. Abd El-Gawad (1999) studies the histopathology on the liver and gill of *Tilapia nilotica* exposed for 14 days to different concentrations of lead acetate (0.25, 0.50, 1.00 and 2.00 ppm.) or zinc sulphate (8, 10, 12 and 14 ppm.). Lead-exposed fish were calm and tended to remain at the bottom of the aquaria, while zinc-exposed fish swam slowly losing their equilibrium. Grossly, fish exposed to the pollutants appeared pale with accumulation of ascitic fluid in addition to loss of some scales. The gills were pale and congested. The liver showed vacuolated hepatocytes with frequent necrosis, evidenced by pyknosis. The bile canaliculi were dilated. The

epithelial covering of the gill filaments was hyperplastic and edematous with vacuolated epithelial covering of the gill rakers. The lamellar blood spaces showed telangiectasis (Abd El-Gawad, 1999).

Figure 15 shows the normal liver cell no pathological lesion observed in the control fish. There was disarrangement of hepatic cell in Figure 16 exposed to concentration of 300 mg/L of *M. oleifera* treated fish. Vacuole formation (Figure 17) was recorded in concentration of 310 mg/L. Necrosis and thickening of the hepatocyte cell (Figure 18) was observed in concentration of 320 mg/L of *Moringa* treated fish. Figure 19 shows the necrosis and thickening of the hepatocyte cell in concentration of 330 mg/L of *Moringa oleifera* treated fish. At (X40) the karyolysis of the hepatocyte (Figure 20) was recorded at high concentration of *Moringa* treated




Figure 13. Erosion of dermal layer and vacuole formation.

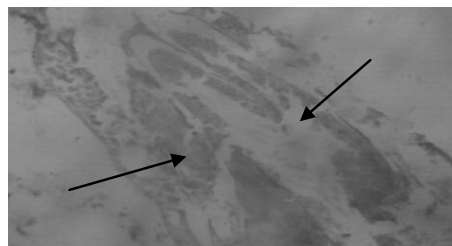


Figure 14. Complete degeneration of cell.

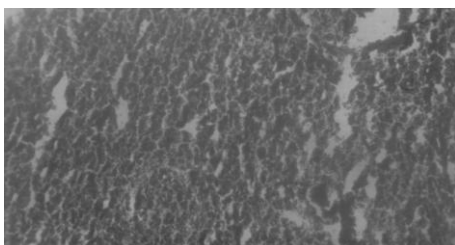


Figure 15. Normal liver no pathological lesion observed.

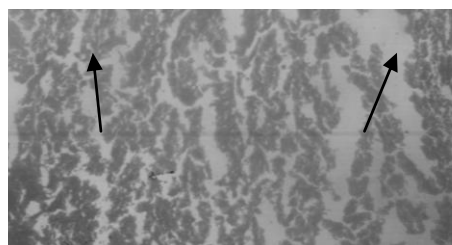


Figure 16. Disarrangement of hepatic cell.

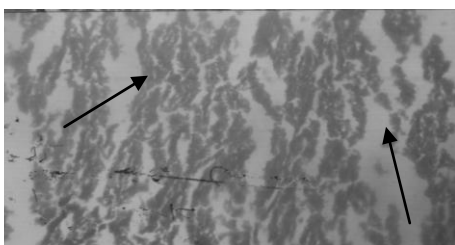


Figure 17. Vacuole formation and thickening of the hepatocyte cell.

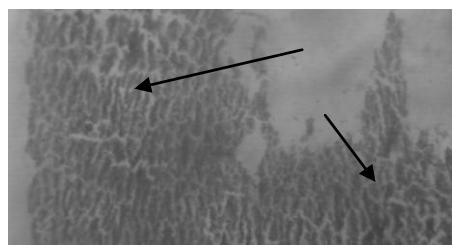


Figure 18. Necrosis and thickening of the hepatocyte cell.

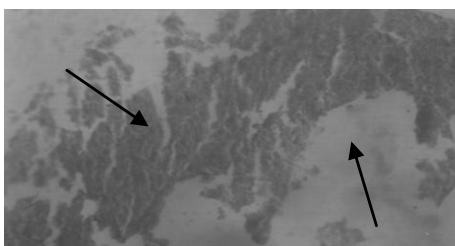


Figure 19. Necrosis and thickening of the hepatocyte cell.

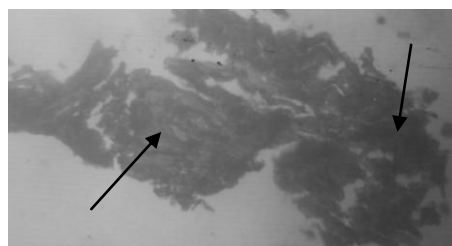


Figure 20. At (X40) the karyolysis of the hepatocyte.

fish. Figure 21 shows the necrosis and faded hepatic cell in the liver of adult tilapia exposed to the highest concentration of 350 mg/L of *Moringa oleifera*. This result is similar to the work of Wade *et al.* (2002) who worked on the toxicity of cassava (*Manihot esculenta*) effluent on the Nile tilapia *Oreochromis niloticus*, histopathological examination of gill, kidney, and liver indicated damage ranging from oedema and telangiectasis of the gill lamella and gill hyperplasia to vacuolation of the liver cells and necrosis.

Figure 22-24 show normal kidney, no pathological lesion observed in concentrations of 0, 300, and 310 mg/L, of *Moringa* treated fish. Hyperplastic of cell and vacuole formation (Figure 25) was observed in concentration of 320 mg/L of *Moringa* treated fish. Shrinkages of hepatocytes cell (Figure 26) were recorded in concentration of 330 mg/L. Figure 27 shows total degeneration of the cell in concentration of 340 mg/L of *Moringa oleifera* treated fish. Total degeneration of the cell (Figure 28)

was recorded in highest concentration of 350 mg/L of *Moringa oleifera* treated fish. Cruz *et al.* (1988), studies the effect of organostannous molluscide, Aquatin (AQTN) and Bresan (BTN), common in used to control snail in fish ponds, their report shows that 96 hours-Lc50 were 4.01, 3.97, 2.95 and 2.58 ppm concentration for 24, 48, 72, and 96hours for aquatin and 0.35, 0.18, 0.10, and 0.09 ppm concentration for Bretan, respectively.

The normal histology of the kidney structure of adult Nile tilapia exposed to 0, 300, 310 mg/L of *Moringa oleifera* is presented in Figure 23, 24. Figure 26 shows the shrinkages of cell at 320 mg/L of *Moringa oleifera* treated fish. The karyolysis of the hepatocyte (Figure 26) was observed in concentration of 330 mg/L, while complete degeneration of cell. (Figure 27 and 28) was observed in highest concentration of 340 and 350 mg/L of *Moringa oleifera* treated fish.

Gill of *Oreochromis mossambicus* exposed to

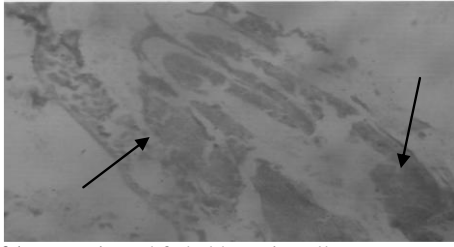


Figure 21 Necrosis and faded hepatic cell.

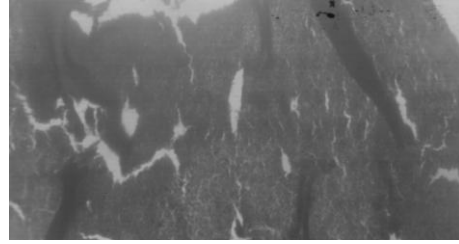


Figure 22. Normal kidney no pathological lesion observed.

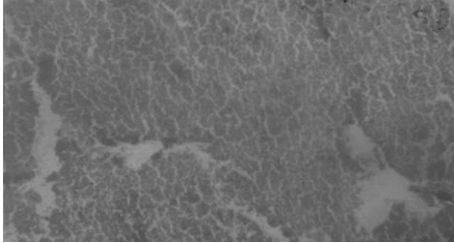


Figure 23. Normal kidney no pathological lesion observed.

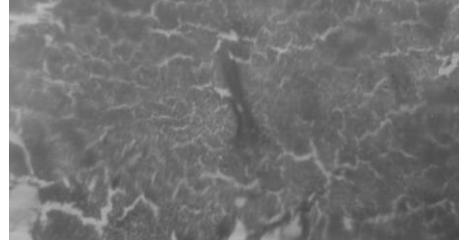


Figure 24. Normal kidney no pathological lesion observed.

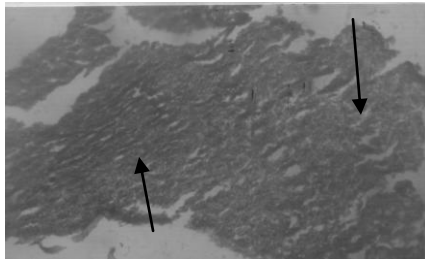


Figure 25. Hyperplasia cell and vacuole formation.

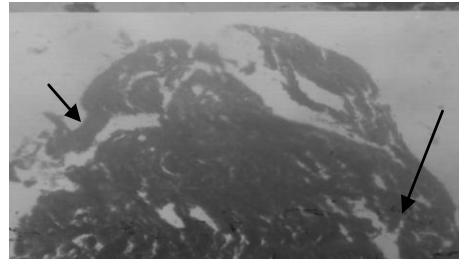


Figure 26. Shrinkages of hepatocytes cell.




Figure 27. Total degeneration of the cell.



Figure 28. Total degeneration of the cell.

Figure 1-28. Histological change observed in the gill (Figure 1-7), the skin (Figure 8-14), the liver (Figure 15-21) and the kidney (Figure 22-28) of adult Nile tilapia treated with different concentrations of *Moringa oleifera*.

aquatin exhibited varying degree of epithelia, hyperplasia among filaments, hyperplasia resulted infusion of many lamellae markedly reducing the respiratory surface area of some filaments (Cruz *et al.*, 1988). Heaviest mortalities occurred in fish showing severe gill epithelia layer from supportive tissue, necrosis of intestinal mucosa, necrosis of liver hepatocytes, and necrosis of renal tubules. Both aquatin and brestan exposed to tilapia had similar histological alterations. Atrophies and necrotic intestinal mucosa, accompanied by lymphocyte infiltration, have been found in fish exposed to pesticides such as DDT (Yokote, 1982).

Simpson *et al.* (2000) worked on the pathology of selected organs of Flounder (*Platichthys flesus*) impacted by endocrine disrupting chemicals. Histopathological result from the preliminary test on

410 flounder on liver, kidney, and gonad, show hepatic tubular vacuolation, foci of cellular alteration, and hepatocellular tumours. Renal and gonadal pathology shows enlarged and abnormal glomeruli.

References

- Abd-El-Gawad, A.M. 1999. Histopathological studies on the liver and gills of *Tilapia nilotica* (*Oreochromis niloticus*) Exposed to different concentrations of lead acetate and zinc sulphate. *J. Egypt. Ger. Soc. Zool.*, 30: 13-22.
- Acquaye, D., Smith, M., Letchamo, W. and Simon, J. 2000. A snopp: The miracle tree: Center for new use agriculture and natural plant product. Rutgers Uni., Cook College, 59 Dudley Road, Foran Hall, New Brunswick.
- AOAC 1987: Standard Method for Examination of

- Wastewater and Water, 17th edition, Washington D.C., 8910 pp.
- Ayotunde, E.O., Fagbenro, O.A., Adebayo, T.O. and Amoo, I.A. 2005. Toxicity of aqueous extracts of Drumstick, *Moringa oleifera*, to fingerling and adult Cat fish *Clarias gariepinus* (Burchell 1822). Bio. and Envi. Sci. J. for the Trop., 2(1): 39-42.
- Ayotunde, E.O., Fagbenro, O.A., Adebayo O.T. and Osho, B.I. 2006. Histological changes in the African catfish, *Clarias gariepinus*, exposed to aqueous extract of drumstick, *Moringa oleifera*, seeds. Bio. and Envi. Sci. J. for the Trop., 3(3): 13-24.
- Bancroft, J.D. and Cook, H.C. 1994 Manual of histological techniques and their diagnostic application. Churchill Livingstone, London: 289-305.
- Cruz, E.R., Dela Cruz, M.C. and Sunaz, N.A 1988, Haematological and Histopathological change in *Oreochromis mossambicus*, after expose to the Molluscicides Aquatin and Brestan. The 2nd International Symposium on Tilapia Aquaculture. Bangkok: 99-110.
- Eilert, U., Wolter, B. and Nahrstedt, A. 1981. The antibiotic principle of *Moringa oleifera* and *Moringa stenopetala*. Planta Medical, 42: 55-61
- Fagbenro, O.A., Adedire, C.O. Owoseni, E.A. and Ayotunde, E.O. 1993. Studies on the biology and aquacultural potential of feral catfish. *Heterobranchus bidorsalis* (Geoffroy Saint Hilaire 1809) (Clariidae). Tropical Zoology, 6: 67-79.
- Foidl, N., Makkar, H.P.S. and Becker, K. 2001. The potential of *Moringa oleifera* for agricultural and industrial uses, In: L.J. Fuglie (Ed.), The Miracle Tree: The Multiple Uses of Moringa. CTA, Wageningen, The Netherlands: 45-76
- Jahn, S.A.A. 1986. Monitored water coagulation with *Moringa oleifera* seeds in village household. J. Analytic Sci., 1: 40-41.
- Haylor, G.S. 1993. The case of the African catfish, *Clarias gariepinus* Burchell Clariidae. A comparison of the relative merit of tilapia fishes especially *Oreochromis niloticus* L and *C. gariepinus* Burchell 1822, for African Aquaculture. Aquaculture Fish Mgt., 20: 285-297.
- Huisman, E.O. and Richter, C.J. 1987. Reproduction, growth, health control and aquacultural potential of the African catfish *Clarias gariepinus* Burchell 1822. Aquaculture, 63: 1-14.
- Hughes, G.M. and Perry, S.F. 1976. Morphometric study of trout gills: A light microscopic method for the evaluation of pollutant action. J. Exp. Biol., 63: 447-460.
- Reish, D.L. and Oshida, O.S. 1987. Manual of Methods in Aquatic Environment Research. Part 10. Short Term Static Bioassay. FAO Fisheries Technical Paper No 427. Rome. 62 pp.
- Olaifa, F.E, Olaifa, A.K. and Lewis O.O. 2003. Toxic stress of lead on *Clarias gariepinus* (African catfish) Fingerlings. African Journal of Biochemical Research, 6: 101-104.
- Parrish, P.R. 1985. Acute toxicity test. In: G.M. Rand and S.R. Petrocelli (Eds.), Fundamentals of Aquatic Toxicity. Hemisphere Publishing Corporation, Washington D.C.: 31-57.
- Price, M.L. 2000. The Moringa Tree. ECHO Technical Note. Educational Concerns for Hunger Organization, N. Ft. Meyers, FL., USA, 19 pp. http://chenetwork.org/files_pdf/Moringa.pdf
- Wade, J.W., Omoregie, E. and Ezenwaka, I. 2002. Toxicity of cassava (*Manihot esculenta* Crants) effluent on the Nile tilapia *Oreochromis niloticus* (L) under laboratory condition. J. Aqua. Sci., 17(2): 89-94.
- Simpson, M.G., Parry, M., Kleinkauf, A., Swarbreck, D., Walker, P. and Leah, R.T. 2000. Pathology of the liver, kidney, and gonad of Flounder (*Platichthys flesus*) from UK estuary impacted by endocrine disrupting chemicals. Mar. Environ. Res., 50(1-5): 283-287.
- Yokote, M. 1982. Digestive system, In T. Hibiya (Ed.), An Atlas of Fish Histology – Normal and Pathological Feature. Kodanshan Ltd., Tokyo: 74-93.