

Cellular Architecture and Functional Aspects of the Olfactory Rosette of *Wallago attu* (Bleeker)

Saroj Kumar Ghosh¹, Padmanabha Chakrabarti^{1,*}

¹ Burdwan University, Department of Zoology, Burdwan, 713104, West Bengal, India.

* Corresponding Author: Tel.: +91.342 2565202; Fax: +91.342 2657938;
E-mail: dr.pchakrabarti@yahoo.in

Received 17 June 2008
Accepted 28 May 2009

Abstract

The olfactory epithelium of *Wallago attu* has been studied with conventional histological techniques. The elongated olfactory rosette consists of 62 to 64 primary lamellae in each left and right rosette. The olfactory lamellae are arranged in two rows on either side of the long raphe. Each olfactory lamella consists of two layers of epithelium separated by central core. The olfactory epithelium in one side consists of mixed sensory and non-sensory epithelium while the other side consists of non-sensory, non-ciliated flattened epithelial cells. The sensory epithelium in this fish contains receptor cells, ciliated supporting cells, basal cells, mast cells and labyrinth cells. The non-sensory epithelium is composed of ciliated supporting cells, labyrinth cells and mucous cells. Different cells of the olfactory epithelium have been correlated with the functional significance of the region concerned in the fish studied.

Keywords: Histoarchitecture and functions, different cells, olfactory rosette, *Wallago attu*.

Introduction

The study of structural organization of olfactory organ in fish is of supreme importance because it is essentially a chemoreceptor and plays a vital role in its feeding and other activities (Hara *et al.*, 1993). A number of researchers have studied the histological peculiarities of the olfactory epithelium in fish (Singh, 1967; Ojha and Kapoor, 1973; Zeiske *et al.*, 1987, Hara and Zielinski, 1989; Bandyopadhyay and Datta, 1996; Mandal *et al.*, 2005, Chakrabarti, 2005). Studies revealed that diversities exist regarding shape, arrangement of the olfactory lamellae and distribution of the sensory and non-sensory epithelium as well as the number of receptor cells in different teleosts. However, lacunae still exists in the structural and functional entities of different sensory and non-sensory cells relating to the olfactory epithelium of carnivorous fish. Therefore, an attempt has been made in the present communication to portray the distribution of the different cell types and their functional aspects in the olfactory epithelium of a freshwater shark, *Wallago attu* (Bleeker).

Materials and Methods

Live mature fishes of *W. attu* were collected from local freshwater fish farm. Fishes were anaesthetized directly in the test aquaria with MS 222. The olfactory rosette were perfused *in vivo* with Bouin's fluid for 30 minutes. The rosettes were then dissected out from the dorsal side under a stereoscopic binocular microscope and then infiltrated with Bouin's fluid for 16 hours. After fixation the tissues were dehydrated properly through graded alcohols,

cleared with xylene and embedded in paraffin. Sections were cut at 4-5 millimicrons thick. The deparaffinised sections were brought to water and stained with both Delafield's haematoxylin-eosin and Mallory's triple stain.

Results

The elongated olfactory rosette of *W. attu* consists of 62-64 lamellae in each left and right rosette. Each lamella is dorsally free but ventrally rest on raphe (Figure 1). The olfactory lamellae are composed of two layers of epithelium separated by central lamellar space, the central core (Figure 2). The lamellae are covered with mixed sensory and ciliated non-sensory epithelium. The non-sensory flattened epithelium mainly consists of stratified epithelial cells and mucous cells. The mixed sensory and non-sensory epithelium as well as non-sensory flattened epithelium faced to the opposite side of the adjacent epithelium of the olfactory lamellae. The central core is composed of loose connective tissues, collagen fibres, blood capillaries and nerve fibres. In the mixed epithelium, the non-sensory ciliated supporting cells divide the surface of sensory epithelium into small islets (Figure 2).

The sensory epithelium is thick and consists of large number of olfactory receptor cells, ciliated supporting cells, basal cells and labyrinth cells (Figure 3). Receptor cells are intermingling with the ciliated supporting cells. The dendrite of each receptor cell run to the surface of the lamellae as a narrow and cylindrical process and sometimes few receptor cells form a swelling which protrudes above the epithelial surface. In some areas the axonal end of

primary neurons synapses with the dendrite tips of the secondary neurons (Figures 3 and 4). The mast cells are rounded with relatively smaller amount of cytoplasm and centrally placed nuclei. The ciliated supporting cells give the basic structure of the olfactory epithelium (Figure 4). The basal cells are lying scattered in the sub-surface part of the epithelium. They are oval or rounded and contain distinct nuclei (Figure 4). The labyrinth cells are scattered in the superficial layer of the olfactory epithelium. They are ovoid or rounded in appearance and their nuclei are present towards the middle or basal ends (Figures 3 and 4). The non-sensory epithelium is of a stratified squamous type. It consists mainly of ciliated supporting cells, mucous cells, basal cells, mast cells, labyrinth cells, epidermal cells

and a few scattered receptor cells (Figure 5). The mucous cells (both secretory and non-secretory) are found distributed at the margin of the olfactory epithelium in between the ciliated supporting cells and epidermal cells. The basal cells are grouped in the deeper part of the epithelium (Figure 5). The non-ciliated epithelium is basically comprised of stratified epithelial cells and mucous cells. Some of the receptor cells are also present in between epithelial cells and mucous cells. In the deeper part of the olfactory epithelium, few plasma cells and non-granular leucocytes in addition to stratified and mucous cells are also found. The central core of the non-ciliated epithelium is filled with loose connective tissue, blood capillaries and nerve fibres (Figure 6).

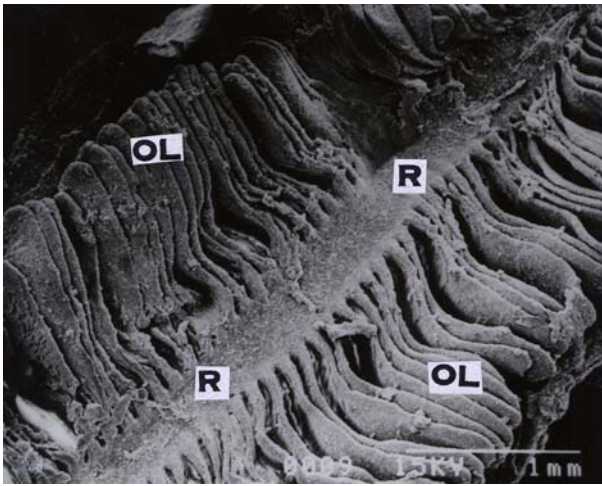


Figure 1. Elongated Olfactory rosette showing different shapes of Lamellae (OL) radiating from the median raphe (R). Scanning electron micrograph (SEM) $\times 50$.



Figure 2. Showing Olfactory epithelium (OEP) separated by central core (CC). Note sensory epithelium (SE) in one side of OL (arrow heads) and non-sensory epithelium (NSE) on other side of OL (arrows). Note also islets of SE (broken arrow). MTS $\times 150$.

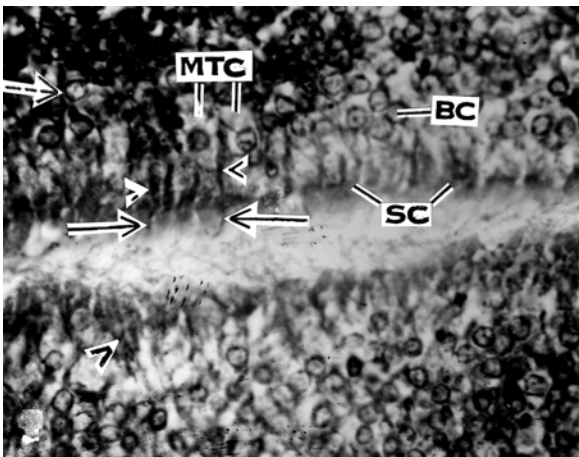


Figure 3. Sensory epithelium provided with receptor cells (RC) (arrow heads), ciliated supporting cells (SC), mast cells (MTC) and basal cells (BC). Note the cylindrical process of dendrite of RC with knobs (solid arrows). Note also the presence of secondary neurons (broken arrows). MTS $\times 400$.

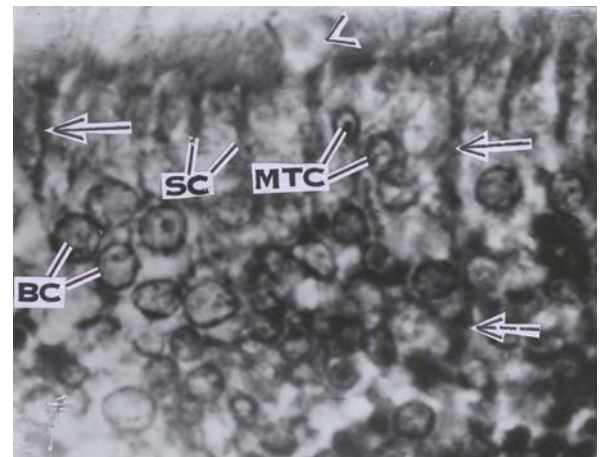


Figure 4. Sensory epithelium provided with RC (Solid arrows) with knobs, SC, BC, MTC, Labyrinth Cell (LC) (arrow head), secondary neuron (broken arrow). H & E $\times 1000$.

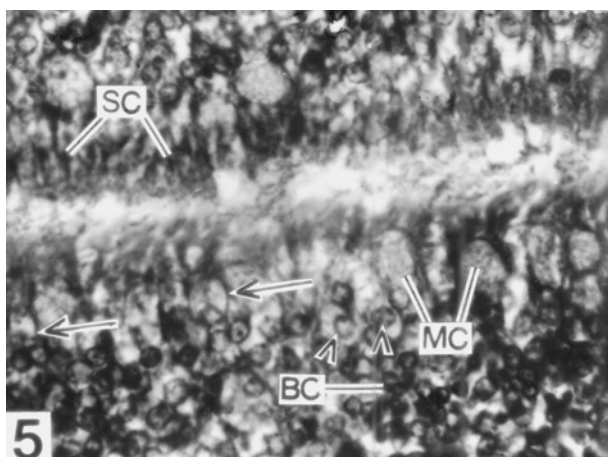


Figure 5. Non-sensory epithelium showing SC, mucous cells (MC), BC, MTC (arrow heads) and few scattered RC (arrows). H & E \times 400.

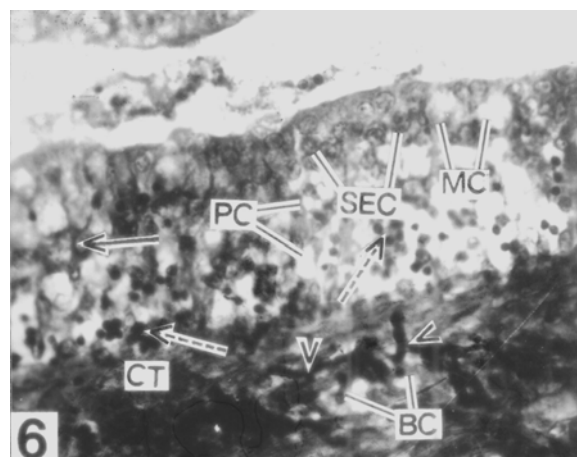


Figure 6. Non-ciliated, non-sensory epithelium with stratified epithelial cells (SEC), MC, few scattered RC (solid arrows), plasma cells (PC) and non-granular leucocytes (broken arrows). Note the presence of blood capillaries (BC), nerve fibres (arrow heads) and connective tissues (CT) in the central core. MTS \times 400.

Discussion

The multilamellar peripheral olfactory organ is a major chemosensory apparatus in fish and plays an important role in their life history (Hara, 1992). The present study reveals that the elongated olfactory rosette of *W. attu* consists of 62 to 64 primary lamellae in each left and right rosette arranged on either side of the long and narrow raphe. Thus the total olfactory area of this fish is considerably greater than the total retinal area. This entitles that it belong to Teichmanns (1954) group of nose fishes comprising solitary and nocturnal predator (Ojha and Kapoor, 1972). The distribution of the non-sensory and sensory epithelia on the surface of the lamellae shows a great variety in different fish species (Yamamoto, 1982). In the present study in *W. attu* the surface of the sensory epithelium restricted to some areas as islets and is separated by non-sensory ciliated supporting cells. This is a unique feature of the olfactory epithelium in this fish. The cilia of the supporting cells create a slow current of water across the olfactory lamellae and at the same time remove the remains of the stimulating substances and keep the receptor cells ready for new stimuli. Adequate ventilation is necessary to bring the odorants in the olfactory chamber for perceiving the chemical signals (Kapoor and Ojha, 1972; Doving *et al.*, 1977; Belanger *et al.*, 2003).

In the sensory epithelium of *W. attu*, the dendrites of the receptor cells terminate in a knob like structure. These receptor cells with knobs and without knobs are of special interest because they may form different olfactory transduction mechanism of pheromones, proteins or amino acid. Hansen *et al.* (2003) opined that the olfactory epithelium of channel catfish contains three intermingled types of olfactory

receptor neurons: ciliated, microvillus and crypt which are responsible for detection of bile salt and amino acids odorants. Zeiske *et al.* (2003) reported that ciliated and microvillar receptor cells are common but in different proportions in different species. The labyrinth cells on the surface of both the sensory and non-sensory epithelium serve as excretory cells for osmoregulation and ion regulation. In this way, they may cause the olfactory organs to function optimally in water of different salinities. Shirai and Utida (1970) have considered that the labyrinth cells may involved in electrolyte transport because they are structurally similar to chloride cells found in fish gills. The basal cells occupy a position below the surface epithelium and distributed throughout the epithelium. The position of the basal cells may have a role for precursors of regenerating of receptor or supporting cells respectively.

Using tritiated thymidine followed by autoradiography Thornhill (1970) showed that the basal cells, apart from differentiating into supporting cells, also give rise to olfactory receptor cells, which are continually replaced during life. Increased mitotic figures have been observed in the basal region in a reconstituting epithelium after degeneration (Evan *et al.*, 1982). The basal cells are assumed to be the progenitors of the receptor and supporting cells (Yamamoto, 1982; Zeiske *et al.*, 1992). In the non-sensory epithelium, the mucous cells are distributed between the stratified epithelial cells and ciliated supporting cells. The secreted mucin from the mucous cells probably helps for coagulating microscopic debris and thereby keeps the receptor ready for new stimuli. This is in conformity with the findings of Rahmani and Khan (1980) in *Anabas testudineus* and Bandyopadhyay and Datta (1998) in *Heteropneustes fossilis*. One of the more interesting features of the

present study is the presence of mast cells in the olfactory epithelium. The mast cells are thought to cause fluctuations in the production of mucus over the olfactory epithelium. As the terminal mucus film is believed to be an important factor in the olfactory process this may also influence the variations in the olfactory sensitivity (Moulton and Beidler, 1967).

On the other hand, the non-ciliated, non-sensory epithelium of olfactory lamellae is mainly provided with stratified epithelial cells and mucous cells. In this region, the secretion of mucin plays a major role for formation of mucus film over the neighboring epithelial cells to protect the olfactory epithelium from different hazardous substances.

Acknowledgements

The authors are grateful to Dr. A. Mazumdar, Head of the Department of Zoology for providing laboratory facilities.

References

- Bandyopadhyay, S.K. and Datta, N.C. 1996. Morphoanatomy and histology of the olfactory organ of an air-breathing catfish *Heteropneustes fossilis* (Bloch). *Journal of Animal Morphology and Physiology*, 43: 85-96.
- Bandyopadhyay, S.K. and Datta, N.C. 1998. Surface ultrastructure of the olfactory rosette of an air-breathing catfish, *Heteropneustes fossilis* (Bloch). *Journal of Biosciences*, 23: 617-622.
- Belanger, R.M., Smith, C.M., Corkum, L.D. and Zielinski, B.S. 2003. Morphology and histochemistry of the peripheral olfactory organ in the round goby, *Neogobius melanostomus* (Teleostei: Gobiidae). *Journal of Morphology*, 257: 62-71.
- Chakrabarti, P. 2005. Histological and histochemical studies on the olfactory rosette of *Mugil parsia* (Hamilton). *Folia Morphologica*, 64(1): 41-46.
- Doving, K.B., Dubois-Dauphin, M., Holley, A. and Jourdan, F. 1977. Functional anatomy of the olfactory organ of fish and the ciliary mechanism of water transport. *Acta Zoologica*, 58: 245-255.
- Evans, R.E., Zielinski, B. and Hara, T.J. 1982. Development and regeneration of the olfactory organ in rainbow trout. T.J. Hara (Ed.), *Chemoreception in fishes*, Elsevier, Amsterdam: 15-37.
- Hansen, A., Rolen, S.H., Anderson, K., Morita, Y., Caprio, J. and Finger, T.E. 2003. Correlation between olfactory receptor cell type and function in the channel catfish. *Journal of Neuroscience*, 23(28): 9328-9339.
- Hara, T.J. 1992. Mechanism of Olfaction. In: T.J. Hara (Ed.) *Fish chemoreception*, Chapman and Hall, London: 150-170.
- Hara, T.J. and Zielinski, B. 1989. Structural and functional development of the olfactory organ in teleosts. *Transactions of the American Microscopical Society*, 118: 183-194.
- Hara, T.J., Sveinsson, T., Evans, R.E. and Klaprat, D.A. 1993. Morphological and functional characteristics of the olfactory and gustatory organs of three *Salvelinus* species. *Canadian Journal of Zoology*, 71: 414-423.
- Kapoor, A.S. and Ojha, P.P. 1972. Studies on ventilation of the olfactory chambers of fishes with a critical reevaluation of the role of accessory nasal sacs. *Archives de Biologie*, 83: 167-178.
- Mandal, D.K., Roy, D. and Ghosh, L. 2005. Structural organization of the olfactory epithelium of a spotted snakehead fish, *Channa punctatus*. *Acta Ichthyologica et Piscatoria*, 35(1): 45-50.
- Moulton, D.G. and Beidler, L.M. 1967. Structure and function in the peripheral olfactory system. *Physiological Review*, 47: 1-52.
- Ojha, P.P. and Kapoor, A.S. 1972. Functional anatomy of nose in the teleost *Wallago attu* (Bl. & Schn.). *Fish Biology*, 83: 105-116.
- Ojha, P.P. and Kapoor, A.S. 1973. Structure and function of the olfactory apparatus in the freshwater carp, *Labeo rohita* (Ham. Buch.). *Journal of Morphology*, 140: 77-86.
- Rahmani, A.R. and Khan, S.M. 1980. Histology of the olfactory epithelium and the accessory nasal sacs of an anabantoid fish, *Anabas testudineus* (Bloch). *Archives de Biologie*, 91: 397-411.
- Shirai, N. and Utida, S. 1970. Development and degeneration of the chloride cell during seawater and freshwater adaptation of the Japanese eel *Anguilla japonica*. *Zeitschrift für Zellforsch*, 103: 247-264.
- Singh, S.P. 1967. Studies on the olfactory organs of certain freshwater teleosts. Part I. *Morphology and Anatomy*. *Indian Journal of Zoology*, 8: 42-70.
- Teichmann, H. 1954. Vergleichende Untersuchungen an der Nase der Fische. *Zeitschrift Morphologica Oekol Tiere*, 43: 171-212.
- Thornhill, R.A. 1970. Cell division in the olfactory epithelium of lamprey, *Lampetra fluviatilis*. *Zeitschrift für Zellforsch*, 109: 147-157.
- Yamamoto, M. 1982. Comparative morphology of the peripheral olfactory organ in teleosts. In: T.J. Hara (Ed.), *Chemoreception in fishes*, Elsevier, Amsterdam: 39-59.
- Zeiske, E., Kasumyan, A., Bartsch, P. and Hansen, A. 2003. Early development of the olfactory organ in sturgeons of the genus *Acipenser*: A comparative and electron microscopic study. *Anatomy and Embryology*, 206: 357-372.
- Zeiske, E., Theisen, B. and Breucker, H. 1992. Structure, development and evolutionary aspects of the peripheral olfactory system. In: T.J. Hara (Ed.), *Fish Chemoreception*, Chapman and Hall, London: 13-39.
- Zeiske, E., Theisen, B. and Gruber, S.H. 1987. Functional morphology of the olfactory organ of two carcharhinid shark species. *Canadian Journal of Zoology*, 65: 2406-2412.