



Sabuncuoglu Serefeddin Health Science (SSHS)

ISSN: 2667-6338, 2021/Vol.3:1

COLONIC METASTASIS FROM LUNG CANCER: A CURATIVELY TREATED CASE REPORT AND REVIEW OF THE LITERATURE

*¹Ismail TARIM, ²Vahit MUTLU, ³Fatma Zeynep OZEN, ⁴Mahmut BASOGLU

¹Ondokuz Mayıs University Medical Faculty, Department of General Surgery/Samsun/Turkey

²Amasya University Medical Faculty, Department of Pathology /Amasya/Turkey

Case Report

Received: 21/12/2021; Accepted: 24/02/2021

*Corresponding author: ismailalper.tarim@omu.edu.tr

Abstract

Lung cancer is the most frequent cause of cancer death in the world. Lung cancer tends to metastasize, but gastrointestinal metastasis is very rare. A 52-year old female patient; previously operated on for lung epidermoid carcinoma; admitted with anemia. A mass in the sigmoid colon was found by colonoscopy. We performed a laparoscopic resection of the sigmoid colon. The report of surgical specimen was epidermoid carcinoma. And then, the patient completed the chemotherapy. The patient is still alive 115 months after the diagnosis of metastatic colonic epidermoid carcinoma. To our knowledge, the case we reported is the first case to cure. It is necessary to be aware that primary epidermoid carcinoma of the lung may cause gastrointestinal tract metastasis. Gastrointestinal metastasis of lung cancer, is seen in the final stages of the disease, and the prognosis is poor, however, with close follow-up, early diagnosis and surgical intervention, the survival may be extended, in our patient, as.

Key Words: Distant metastases, Gastrointestinal metastasis, Lung cancer metastases.

Özet

Akciğer kanseri, dünyada kanserden ölümlerin en sık nedenidir. Akciğer kanseri metastaz yapma eğilimindedir, ancak gastrointestinal metastaz çok nadirdir. Daha önce akciğer epidermoid karsinomu için ameliyat edilmiş 52 yaşında kadın hasta anemi ile başvurdu. Kolonoskopi ile sigmoid kolonda bir kitle bulundu. Laparoskopik sigmoid kolon rezeksiyonunu uygulandı. Patoloji sonucu epidermoid karsinom olarak raporlandı. Ardından hasta kemoterapi aldı. Hasta, metastatik kolonik epidermoid karsinom tanısından 115 ay sonra hala hayattadır. Bildiğimiz kadarıyla, bildirdiğimiz vaka küratif tedavi edilen ilk vakadır. Akciğerin primer epidermoid karsinomunun gastrointestinal sistem metastazına neden olabileceğinin bilinmesi gerekir. Akciğer kanserinin gastrointestinal metastazı, hastalığın son evrelerinde görülür ve prognozu kötüdür, ancak yakın takip, erken tanı ve cerrahi müdahale ile hastamızda olduğu gibi yaşam süresi uzatılabilir.

Anahtar Kelimeler: Akciğer kanseri metastazı, Gastrointestinal metastaz, Uzak metastaz.

1. Introduction

Lung cancer is the most common cause of cancer deaths in the world (Siegel et al., 2011). When lung cancers are diagnosed, it has been reported that almost half of them have metastases (Yang et al., 2006). Lung cancer most frequently metastasizes to the brain, liver, adrenal glands and bone marrow (Hillers et al., 1994). Metastasis at lung cancer to the gastrointestinal system is exceedingly uncommon. The most frequent site of gastrointestinal system metastasis is small bowel. Gastric, esophageal, colonic and anus metastasis are reported in sporadic cases (Yang et al., 2006). We report a case of metastatic colonic epidermoid carcinoma from the primitive lung cancer which is treated curative.

2. Case Report

A 52-year old diabetic and hypertensive female patient with the symptom of back pain and hacking cough, admitted to the clinic of thoracic surgery. In the X-Rays performed to the patient, it was demonstrated a suspected nodular density in the superior lobe of the left lung (Figure 1). In thoracic computerized tomography (CT) scan performed to the patient, it was demonstrated soft tissue density that was not differentiated as tumor or consolidation. This

nodular density lays on the anterior- posterior segments of the superior lobe of the left lung and its size was measured 4x5 cm.

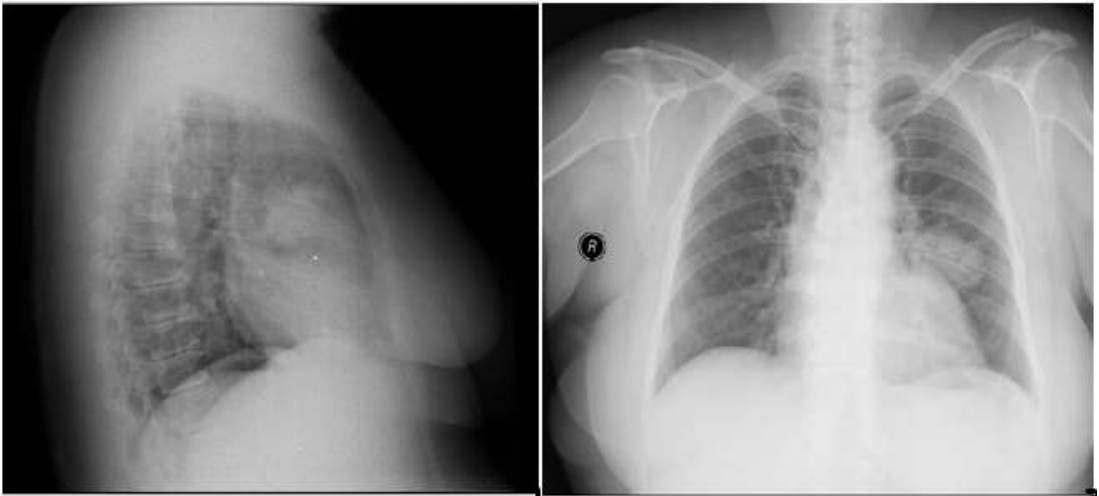


Figure 1. A suspected nodular density in the superior lobe of the left lung

Tru-cut biopsy was performed from the mass and reported as necrotic neoplasm. The patient underwent left upper lung lobectomy. The specimen was sent to pathology and it was reported as epidermoid carcinoma (Figure 2).

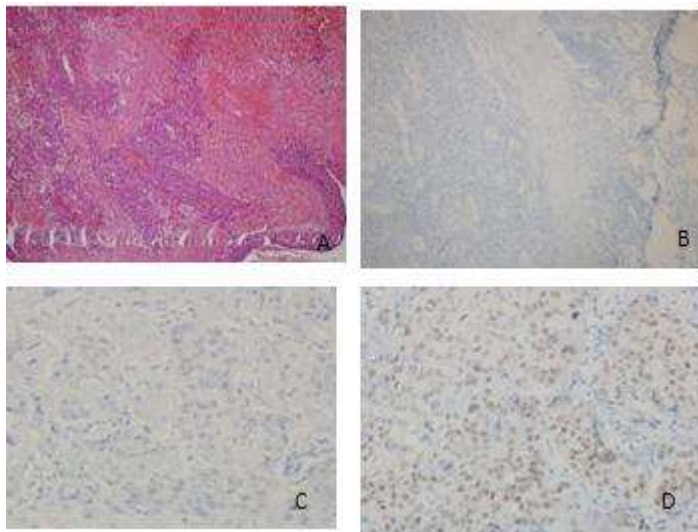


Figure 2. Epidermoid carcinoma

The patient was followed closely. Six months later, in the laboratory tests, we found that Hb: 8.3 g/dl, CEA: 1.23 U/ml, CA19-9: 9.7 ng/ml. During colonoscopy it was shown an ulcerovegetan mass that was located at 40th cm from anus (Sigmoid Colon) (Figure 3).

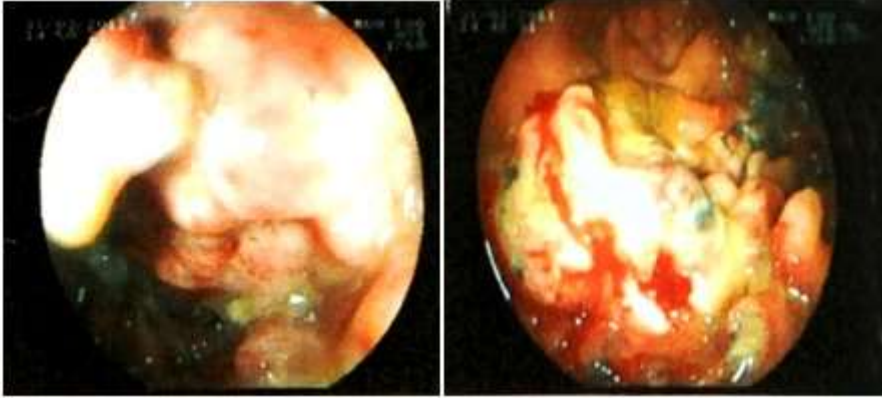


Figure 3. Ulcerovegetan mass that was located at 40th cm from anus (Sigmoid Colon)

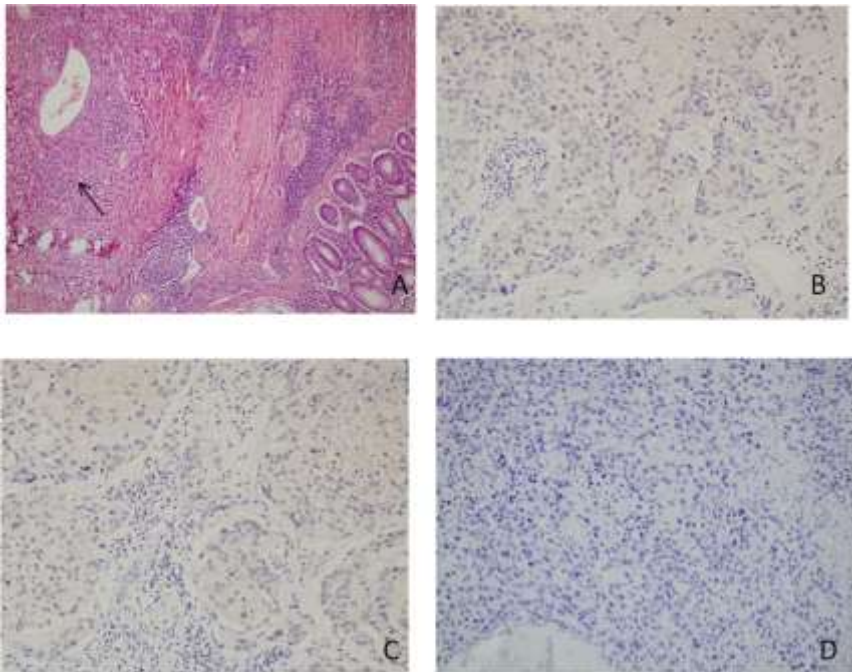


Figure 4. Negatively stained by immunohistochemically with CK20, CK7, CDX2

Biopsy specimens obtained from the mass reported as epidermoid carcinoma. Based on these findings, the patient was diagnosed with metastatic colonic epidermoid carcinoma from primary lung cancer.

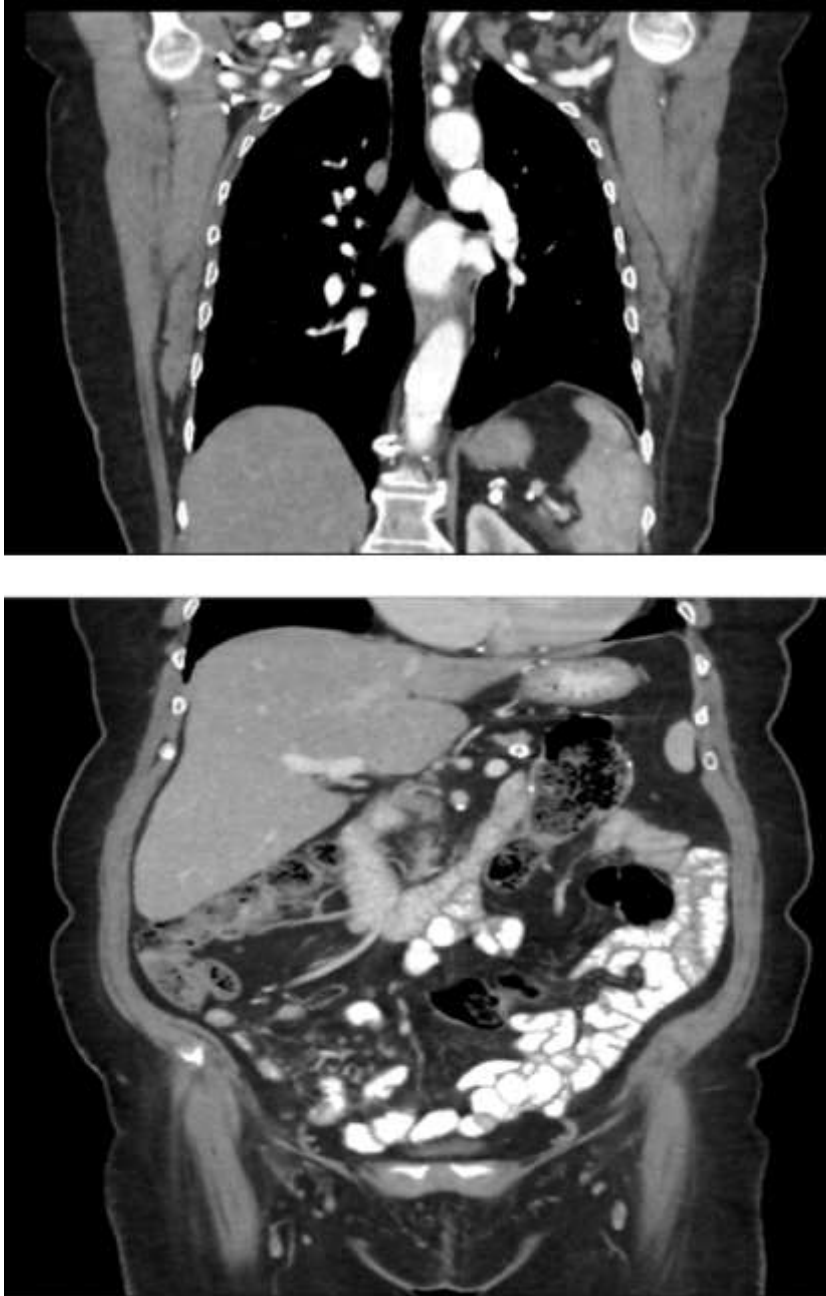

Figure 5. The most recent thorax and abdomen CT

Abdominal CT was performed to the patient and it was seen a 7 cm length mass at the joint of descending and sigmoid colon. PET CT was applied to the patient for staging; FDG accumulation was observed only in the sigmoid colon. We performed a laparoscopic resection of the sigmoid colon and end to end anastomosis at 17 May 2011. The report of surgical specimen was epidermoid carcinoma, which was negatively stained by immunohistochemically with CK20, CK7, CDX2 (Figure 4). The patient completed the chemotherapy. She is still alive and now 61 years old. 115 months (more than 9 years) have passed since it was operated due to the diagnosis of metastatic colonic epidermoid carcinoma. In the most recent thorax and abdomen CT, no cancer focus was found (Figure 5). The most recent CEA and CA19-9 results were 3.03 U/ml and 10.9 ng/ml, respectively.

3. Discussion

Metastasis to gastrointestinal system from cancer of lung is seen rarely. Even though the actual incidence of those metastases is not known, the prevalence at autopsy is 4.7% -14% (Antler et al., 1982; Rossi et al., 2007). Incidence of lung cancer metastasis to gastrointestinal system and colon was 1.8% and 0.5% respectively (Ryo et al., 1996). From 1978 to the present only 40 cases of colon metastases from the lung cancer published in the literature (Gonzalez-Tallon et al., 2013).

Colon metastases have been described with all kinds of lung carcinoma but the most common histological type of tumor which causes gastrointestinal metastasis varies from one study to another. In the literature, significant number of reported colonic metastasis cases are originated from epidermoid carcinoma of lung as like our case (Yang et al., 2006; Parker et al., 2019; Hirasaki et al., 2008; Smith et al., 1978; Sakai et al., 2012).

When lung cancer metastasizes to the gastrointestinal tract, it is usually asymptomatic (Ryo et al., 1996). Yang et al. reported the rate of symptomatic gastrointestinal metastasis as 1.77% for lung cancers (Yang et al., 2006). Gastrointestinal metastasized lung cancer may cause symptoms such as abdominal pain, nausea, vomiting, anemia, and weight loss (Antler et al., 1982; Lou et al., 2014). Rare symptoms are colonic obstruction, bloody stools and diarrhea (Yang et al., 2006; Ryo et al., 1996; Lou et al., 2014; Carroll et al., 2001).

CT scan and endoscopy may be insufficient to determine the type of gastrointestinal tumor or to determine its primary, if it is metastasis. We can only distinguish whether the tumor is a primary gastrointestinal tumor or a lung metastasis by histological examination and immunostaining (TTF-1, CDX2, CK7 and CK20) (Rossi et al., 2007). We were able to understand

that our case had metastasis by CT scan, endoscopy and histological examination and immunostaining of the biopsy, respectively.

It is known that the prognosis of lung cancer with bowel metastasis is not good (Yang et al., 2006; Habesoglu et al., 2005; McNeill et al., 1987; Rouhanimanesh et al., 2001). Yang et al. reported the mean survival as 130 days, indicating poor prognosis (Yang et al., 2006). Rossi et al. reported that four-teen patients of eigh-teen died of disease at a mean follow-up of 3 months. The other four patients were alive with disease, with a very short follow-up ranging from 2 weeks to 5 months (Rossi et al., 2007). Kim et al reported a case which remained alive more than 5 years after resection of metastatic intestine (Kim et al., 2009). Here in this case, we report the survival as 115 months and the patient is still alive. To our knowledge, this is the first report of such a case. Patients with gastrointestinal metastases from lung cancer are considered in the fourth stage of the disease (Lee et al., 2011). Early surgical intervention may contribute to surveillance, and even curative recovery can be achieved, as in our case. In our opinion, the most important factor in providing curative treatment for the patient is that we follow the patient closely. Our patient has shown that close follow-up, early diagnosis and adequate surgical treatment in patients with survival time can be very long.

4. Conclusion

We reported an uncommon case of colonic metastasis from lung cancer. When the patients with a primary lung cancer history come with anemia or abdominal symptoms, it is necessary to be aware that primary epidermoid carcinoma of the lung may cause colonic metastasis. Gastrointestinal metastasis of lung cancer is seen in the final stages of the disease, and the prognosis is poor, however, with close follow-up, early diagnosis and surgical intervention, the survey may be extended, in our patient, as.

Acknowledgement

None.

Conflicts of interest

The authors declare that there are no potential conflicts of interest relevant to this article.

References

- Antler, A.S., Ough, Y., Pitchumoni, C.S., Davidian, M., Thelmo, W. (1982). Gastrointestinal Metastases from Malignant Tumors of the Lung. *Cancer*, 49:170-72.
- Carroll, D., Rajesh, P.B. (2001). Colonic Metastases from Primary Squamous Cell Carcinoma of the Lung. *Eur J Cardiothorac Surg*, 19(5):719-720.
- Gonzalez-Tallon, A.I., Vasquez-Guerrero, J., Garcia-Mayor, M.A. (2013). Colonic Metastases from Lung Carcinoma: A Case Report and Review of the Literature. *Gastroenterology Research*, 6(1):29-33.
- Habesoglu, M.A., Oguzulgen, K.I., Ozturk, C., Akyurek, N., Memis, L. (2005). A Case of Bronchogenic Carcinoma Presenting with Acute Abdomen. *Tuberk Toraks*, 53: 280-83.
- Hillers, T.K., Sauve, M.D., Guyatt, G.H. (1994). Analysis of Published Studies on the Detection of Extrathoracic Metastases in Patients Presumed to Have Operable Non-small Cell Lung Cancer. *Thorax*, 49(1):14-9.
- Hirasaki, S., Suzuki, S., Umemura, S., Kamei, H., Okuda, M., Kudo, K. (2008). Asymptomatic Colonic Metastases from Primary Squamous Cell Carcinoma of the Lung with a Positive Fecal Occult Blood Test. *World J Gastroenterol*, 14(35):5481-83.
- Kim, M.S, Kook E.H., Ahn, S.H., Jeon, S.Y., Yoon, J.H., Han, M.S., Kim, C.H., Lee, J.C. (2009). Gastrointestinal Metastasis of Lung Cancer with Special Emphasis on a Long-term Survivor After Operation. *J Cancer Res Clin Oncol*, 135(2):297-301.
- Lee, P.C., Lo, C., Lin. M.T., Liang, J.T., Lin, B.R. (2011). Role of Surgical Intervention in Managing Gastrointestinal Metastases from Lung Cancer. *World J Gastroenterol*, 17(38):4314–20.
- Lou, H.Z., Wang, C.H., Pan, H.M., Pan, Q., Wang, J. (2014). Colonic Metastasis After Resection of Primary Squamous Cell Carcinoma of the Lung: A Case Report and Literature Review. *World J Gastroenterol*, 20:5930–34.
- McNeill, P.M., Wagman, L.D., Neifeld, J.P. (1987). Small Bowel Metastases from Primary Carcinoma of the Lung. *Cancer*, 59:1486-89.
- Parker, N.A., McBride, C., Forge, J., Lalich, D. (2019). Bowel Obstruction Caused by Colonic Metastasis of Lung Adenocarcinoma: A Case Report and Literature Review. *World J Surg Oncol*, 17(1):63.
- Rossi, G., Marchioni, A., Romagnani, E., Bertolini, F., Longo, L., Cavazza, A., Barbieri, F. (2007). Primary Lung Cancer Presenting with Gastrointestinal Tract Involvement:

Clinicopathologic and Immunohistochemical Features in a Series of 18 Consecutive Cases. *J Thorac Oncol*, 2:115-20.

Rouhanimanesh, Y., Vanderstighelen, Y., Vanderputte, S., Cools, P., Wassenaar, H., Vallaey, J. (2001). Intra-abdominal Metastases from Primary Carcinoma of the Lung. *Acta Chir Belg*, 101: 300-03.

Ryo, H., Sakai, H., Ikeda, T., Hibino, S., Goto, I., Yoneda, S., No-guchi, Y. (1996). Gastrointestinal Metastasis from Lung Cancer. *Nihon Kyobu Shikkan Gakkai Zasshi*, 34(9):968- 72.

Sakai, H., Egi, H., Hinoi, T., Tokunaga, M., Kawaguchi, Y., Shinomura, M., Adachi, T., Arihiro, K., Ohdan, H. (2012). Primary Lung Cancer Presenting with Metastasis to the Colon: A Case Report. *World J Surg Oncol*, 10:127.

Siegel, R., Ward, E., Brawley, O., Jemal, A. (2011). Cancer Statistics, 2011: The Impact of Eliminating Socioeconomic and Racial Disparities on Premature Cancer Deaths. *CA Cancer J Clin*, 61(4):212-36.

Smith, H.J., Vlasak, M.G. (1978). Metastasis to the Colon from Bronchogenic Carcinoma. *Gastrointest Radiol*, 2(4):393-96.

Yang, C.J., Hwang, J.J., Kang, W.Y., Chong, I.W., Wang, T.H., Sheu, C.C., Tsai, J.R., Huang, M.S. (2006). Gastro-intestinal Metastasis of Primary Lung Carcinoma: Clinical Presentations and Outcome. *Lung Cancer*, 54(3):319-23.