

Effect of rutin on experimentally induced small intestinal ischemia reperfusion injury in rats: A biochemical and histopathological evaluation

Ferda Keskin Çimen ¹, Orhan Çimen ², Durdu Altuner ³, Arif Burak Çekic ⁴, Nezahat Kurt ⁵, Halis Süleyman ⁶

¹ Department of Pathology, Faculty of Medicine, Erzincan Binali Yıldırım University, 24100, Erzincan, Turkey

² Department of General Surgery, Faculty of Medicine, Erzincan Binali Yıldırım University, 24100, Erzincan, Turkey

³ Department of Pharmacology, Faculty of Medicine, Erzincan Binali Yıldırım University, 24100, Erzincan, Turkey

⁴ Department of General Surgery, Faculty of Medicine, Karadeniz Technical University, 61000, Trabzon, Turkey

⁵ Department of Biochemistry, Faculty of Medicine, Ataturk University, 25100, Erzurum, Turkey

⁶ Department of Pharmacology, Faculty of Medicine, Erzincan Binali Yıldırım University, 24100, Erzincan, Turkey

ORCID ID of the author(s)

FKÇ: 0000-0002-1844-0827
OÇ: 0000-0003-4723-5838
DA: 0000-0002-5756-3459
ABÇ: 0000-0002-1460-6949
NK: 0000-0002-1685-5332
HS: 0000-0002-9239-4099

Corresponding Author

Halis Süleyman

Department of Pharmacology, Faculty of Medicine, Erzincan Binali Yıldırım University, 24030, Erzincan, Turkey
E-mail: halis.suleyman@gmail.com

Ethics Committee Approval

Atatürk University, Animal Experiments Local Ethics Committee, 31/01/2019, 1.

Conflict of Interest

No conflict of interest was declared by the authors.

Financial Disclosure

The authors declared that this study has received no financial support.

Published

2021 January 29

Copyright © 2021 The Author(s)

Published by JOSAM

This is an open access article distributed under the terms of the Creative Commons Attribution-NonCommercial-NoDerivatives License 4.0 (CC BY-NC-ND 4.0) where it is permissible to download, share, remix, transform, and build upon the work provided it is properly cited. The work cannot be used commercially without permission from the journal.



Abstract

Background/Aim: The large amount of oxygen presented to the ischemic tissue in reperfusion causes the formation of excess free oxygen radicals and results in oxidative damage. Rutin is a flavonoid with potent antioxidant and anti-inflammatory effects. The aim of this study is to examine the effect of rutin on I/R-induced small intestinal (ileum) oxidative damage in rats.

Methods: The animals were divided into three groups as follows: Intestinal ischemia-reperfusion (IIR), 50 mg/kg rutin+intestinal ischemia reperfusion (RIIR) and sham operation (Sham). Rutin was administered at a dose of 50 mg/kg by oral catheterization one hour prior to thiopental sodium anesthesia. Distilled water was administered with the same method to IIR and Sham groups as a solvent. To induce intestinal ischemia in RIIR and IIR groups, the superior mesenteric artery was suspended from the point where it left the aorta, and ischemia was induced for 45 minutes with the help of an atraumatic microvascular clamp followed by 60 minutes of reperfusion. Biochemical and histopathological examinations were performed on the dissected ileal tissues.

Results: The amount of MDA and MPO activity increased, while tGSH levels and CAT activity decreased significantly in the intestinal tissue of the IIR group compared to sham group ($P<0.001$). Rutin treatment decreased the increase in MDA and MPO activity and increased the decrease of tGSH levels and CAT activity significantly compared to the IIR group ($P<0.001$). Histopathological changes such as PNL infiltration, edema, hemorrhage, and destruction were observed in the ileal tissue of the rats in the IIR group. However, there were no pathological findings in the RIIR group treated with rutin except for mildly dilated congested blood vessels.

Conclusion: Rutin may be useful against intestinal I/R oxidative damage in clinical practice.

Keywords: Rutin, Small intestine, Ischemia, Reperfusion, Rat

Introduction

Small intestinal ischemia is a serious and frequent clinical condition caused by the occlusion of the superior mesenteric artery for several reasons (arterial thrombosis, embolism, Henoch-Schonlein purpura, invagination, drowned inguinal hernia, tumor, fibrotic tape) [1]. In clinical practice, reperfusion of the ischemic tissue is provided to protect the tissue from necrosis caused by ischemia, prevent high mortality and morbidity, and regain organ functions. However, it has been found that reperfusion exposes ischemic organs to the risk of late cellular necrosis and therefore limits the recovery of function and increases tissue damage [2]. The reason is that oxygen, which is abundantly presented to ischemic tissue during reperfusion, converts hypoxanthine to xanthine along with xanthine oxidase accumulated during ischemia, and causes the formation of excess radical oxygen species (ROS) [3]. ROSs, namely superoxide anion ($O_2^{\cdot-}$), hydroxyl radicals ($\cdot OH$), hydrogen peroxide (H_2O_2), hypochloric acid, and nitric oxide, can easily react with the cell components, alter their chemical structure, and cause damage [4]. ROSs damage membrane lipids, nucleic acids, enzymes and receptors. As is known, membrane lipids are the most sensitive structures to ROSs. The most important effect on lipids is the stimulation of lipid peroxidation (LPO) [3]. In intestinal ischemia reperfusion (I/R) injury, a decrease in antioxidant defense systems is also observed in parallel with the increase in malondialdehyde (MDA) [5]. Increased cytokine release is also involved in the pathogenesis of intestinal I/R injury [6].

Rutin (3,3',4,5,7 - pentahydroxyflavone - 3 - rhamnoglucoside) is a vitamin P1 flavonoid [7]. It is known that rutin has antioxidant, anti-inflammatory properties and inhibits polymorphonuclear granulocyte infiltration [8]. Recent studies have reported that rutin also inhibits the increase in proinflammatory cytokines and LPO end-product MDA, and the decrease in endogenous glutathione [9]. There are no studies in the literature investigating the protective effect of rutin on small intestinal I/R injury. The aim of this study was to analyze the effect of rutin on I/R-induced small intestine (ileum) oxidative injury in an experimental rat model using biochemical and histopathological methods.

Materials and methods

Animals

Eighteen albino Wistar male rats weighing 290-300 grams were used in the experiment. All rats were obtained from Ataturk University Medical Experimental Application and Research Center. The animals were housed and fed in groups at 22°C under appropriate conditions before the experiment. Animal experiments were performed in accordance with the National Guidelines for the Use and Care of Laboratory Animals and approved by Atatürk University Local Animal Ethics Committee for Animal Experiments, dated: 31/01/2019, meeting number: 1, judgment no:3.

Chemicals

Thiopental sodium used in the experiment was obtained from I.E ULAGAY (Turkey), and rutin was obtained from Solgar (United States).

Experimental Groups

Animals were divided into three groups: Intestinal ischemia-reperfusion (IIR), 50 mg/kg rutin + intestinal ischemia-reperfusion (RIIR) and sham operation (Sham).

Experimental Procedure

Anesthesia administration

Surgical procedures were performed under sterile conditions. Rats were anesthetized with 25 mg/kg intraperitoneal (i.p.) thiopental sodium injections and xylazine inhalation at appropriate intervals. After injection of thiopental sodium, the rats were allowed to stand for the appropriate period of surgery. The period in which animals remained stationary in the supine position was considered the appropriate period of anesthesia for surgery [10].

Surgical and pharmacological procedures

50 mg/kg of rutin was administered orally with a catheter to the RIIR group (n=6) one hour before thiopental sodium anesthesia. Distilled water was administered with the same method to the RIIR and Sham groups as a solvent. During anesthesia, all rats were placed in the supine position, a 3.5-4 cm long incision was made on the anterior part of the abdomen, and laparotomy was performed. Sham group did not undergo any surgical procedures and the incision was closed with surgical suture. To induce small intestinal ischemia in the RIIR and IIR groups, the superior mesenteric artery (SMA) was suspended at the point where it left the aorta and ligated for 45 minutes with the help of an atraumatic microvascular clamp. Then, the midline laparotomy incision was sutured (3/0 silk). Following the ischemia period, the silk suture was removed and the laparotomy incision was re-opened. The bulldog clamp placed in the SMA of the rats was opened and removed. Reperfusion was induced for one hour in this group, and the laparotomy incision was closed with continuous suture using 3/0 silk. At the end of this period, the animals were sacrificed with high dose thiopental anesthesia (50 mg/kg) and the ileal tissues were removed. Biochemical and histopathological examinations were performed in the dissected ileal tissues. The results were comparatively evaluated between the groups.

Biochemical procedures

Sample preparation

Potassium phosphate buffer with pH=6 containing 0.5% HDTMAB (0.5% hexadecyl trimethyl ammonium bromide) was completed to 2 mL in 1.15% potassium chloride solution for MDA determination, and in phosphate buffer with pH=7.5 for other measurements and homogenized in icy environment. The homogenate was then centrifuged at +4 °C for 15 minutes at 10000 rpm. The supernatant portion was used as the analysis sample.

MDA analysis

The method of Ohkawa H et al. was used for MDA measurement [11]. This method is based on the spectrophotometric measurement (at a wavelength of 532 nm) of the absorbance of the pink colored complex formed by thiobarbituric acid (TBA) and MDA at a high temperature (95°C). The homogenates were centrifuged at 5000g for 20 minutes and these supernatants were used to determine the amount of MDA. 250 µl of homogenate, 100 µl of 8% sodium dodecyl sulfate (SDS), 750 µl of 20% acetic acid, 750 µl of

0.08% TBA and 150 μ l of distilled water were pipetted into the test tubes and vortexed. The mixture was incubated at 100 °C for 60 minutes, then 2.5 ml of n-butanol was added to the mixture and spectrophotometrically measured. The amount of red color formed was read at 532 nm using 3 ml cuvettes and the amount of MDA of the samples was determined while considering the dilution coefficients by using the standard graph prepared from the previously readied MDA stock solution.

Determination of myeloperoxidase (MPO) activity

MPO activity was measured according to the modified method of Bradley et al. [12]. The homogenized samples were frozen and centrifuged at 1500 g for 10 min at 4°C. MPO activity in the supernatants was determined by adding 100 μ l of the supernatant to 1.9 mL of 10 mmol/L phosphate buffer (pH 6.0) and 1 mL of 1.5 mmol/L o-dianisidine hydrochloride containing 0.0005% (wt/vol) hydrogen peroxide. The changes in absorbance at 450 nm of each sample were recorded on a UV-vis spectrophotometer [12].

Total glutathione (tGSH) analysis

The amount of GSH in the total homogenate was measured according to the method of Sedlak and Lindsay with some modifications [13]. The sample was weighed and homogenized in 2 mL of 50 mmol/L Tris-HCl buffer containing 20 mmol/L EDTA and 0.2 mmol/L sucrose at pH 7.5. The homogenate was immediately precipitated with 0.1 mL of 25% trichloroacetic acid, and the precipitate was removed after centrifugation at 4200 rpm for 40 min at 4 °C. The supernatant was used to determine GSH level. A total of 1500 μ l of buffer (200 mmol/L Tris-HCl buffer containing 0.2 mmol/L EDTA at pH 7.5), 500 μ l supernatant, 100 μ l 5,5-Dithiobis (2-nitrobenzoic acid) (DTNB) (10 mmol/L) and 7900 μ l methanol were added into a tube and vortexed and incubated for 30 min in 37°C. DTNB was used as a chromogen and it formed a yellow-colored complex with sulfhydryl groups. The absorbance was measured at 412 nm using a spectrophotometer (Beckman DU 500, USA). The standard curve was obtained by using reduced glutathione.

Catalase (CAT) analysis

Activity is based on the measurement of decrease in absorbance when H₂O₂ is converted to H₂O through CAT, at 240 nm. For CAT measurement, 0.5 g of tissue was removed, 4.5 mL of 50 mM K-phosphate buffer (pH 7.8) was added on it and the mixture was homogenized. The homogenate was centrifuged at 18000 g for 60 min at 4°C and the supernatants were used as a resource of enzyme for measurement of the catalase activity. H₂O₂ solution of 1.5mL was put into quartz spectrophotometer cuvette and after adding 1.5 mL of sample solution, the stopwatch was run immediately as the final solution was 20 mM. After turning the cuvette upside-down, absorbance was read on the spectrophotometer at 240 nm with 15 seconds intervals for 3 minutes and recorded [14].

Histopathological examination

Intestinal tissues removed from the rats were fixed in 10% formalin solution for 24 hours. Sections of 4-micron thickness were obtained from the paraffin blocks following routine tissue monitoring and stained with hematoxylin & eosin. All sections were evaluated under light microscopy (Olympus

BX 52, Tokyo, Japan) by a pathologist who was not aware of the treatment protocols.

Statistical analysis

All data were subjected to the Kruskal-Wallis test using SPSS version 18.0 software (IBM Corporation, Armonk, NY, USA). Differences between groups were obtained using Wilcoxon Rank sum tests with Bonferroni corrections. $P < 0.05$ was considered significant. The results were expressed as mean and the standard error of the mean (SEM).

Results

Biochemical Findings

As shown in Figure 1, the amount of MDA in the intestinal tissue exposed to I/R significantly increased compared to the sham group ($P < 0.001$). In the rutin group, the amount of MDA decreased compared to the I/R group ($P < 0.001$).

I/R procedure applied to intestinal tissue significantly increased MPO activity in the tissue compared to the sham group ($P < 0.001$) (Figure 1). However, in the rutin group, MPO activity decreased compared to the I/R applied group and the difference between these two groups was statistically significant ($P < 0.001$).

Also, I/R procedure led to a decrease in tGSH in intestinal tissue. The amount of tGSH in the I/R-treated intestinal tissue decreased significantly compared to the sham and rutin groups ($P < 0.001$) (Figure 2).

Similarly, I/R procedure resulted in a decrease in CAT activity in the intestinal tissue compared to sham group. However, rutin significantly prevented the decrease in CAT activity in the intestinal tissue of the animals undergoing I/R procedure ($P < 0.001$) (Figure 2). The difference in CAT activity between the group treated with rutin and the sham group was insignificant ($P = 0.117$).

Figure 1: MDA levels and MPO activity in the ileum tissue of study groups (* $p < 0.001$ according to IIR group)

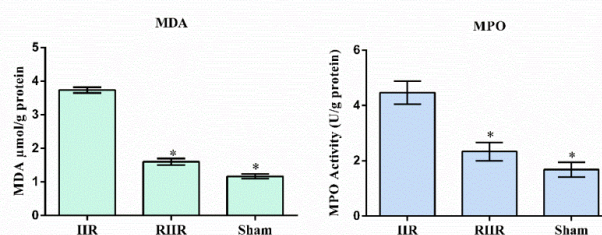
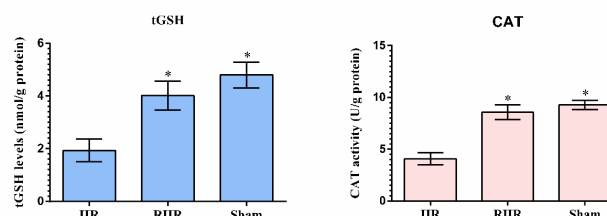


Figure 2: tGSH levels and CAT activity in the ileum tissue of study groups (* $p < 0.001$ according to IIR group)



Histopathological findings

As seen in Figure 3, no histopathological findings were observed in the ileal tissue of the animals in the sham group. However, evident PNL infiltration, edema, hemorrhage, and destruction were observed in the ileal tissue of the rats undergoing I/R procedure (Figure 4). There was no pathological finding in the ileal tissue of the RIIR group, except for mildly dilated congested blood vessels (Figure 5).

Figure 3: Ileal tissue section of Sham group animals (HEX100)

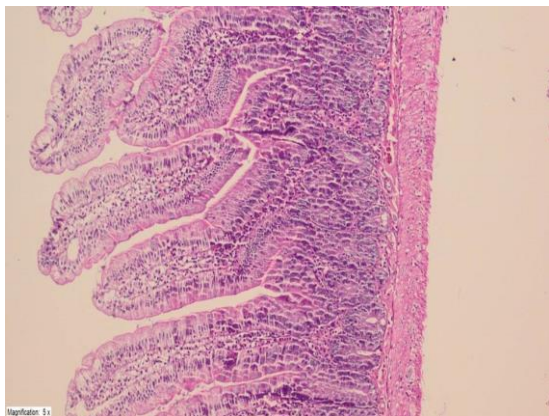


Figure 4: A section showing the polymorphonuclear (plain arrow) leukocyte infiltration, edema, hemorrhage and destruction (double-sided arrow) of the ileum tissue of the IIR group (HEX-400)

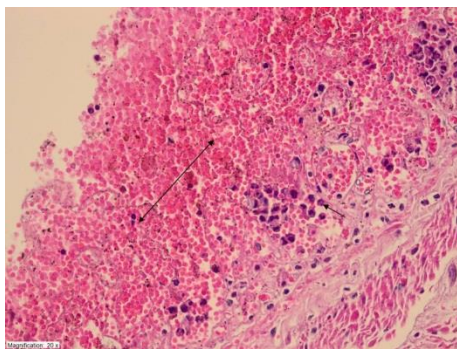
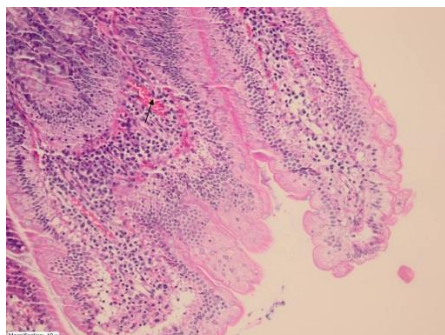


Figure 5: A section showing the dilated congested blood vessels in the intestinal tissue mucosa of RIIR group (HEX-200)



Discussion

In this study, the effect of rutin on I/R induced experimental small intestinal oxidative damage in rats was investigated biochemically and histopathologically. Reperfusion is an important procedure for recovering organ and tissue functions lost during ischemia. However, molecular oxygen presented to the ischemic tissue by sudden and excessive amounts of blood during reperfusion may lead to increased ROS production and oxidative stress [2,3]. ROSs initiate oxidative damage by inducing LPO in cell membranes [15]. During reperfusion, the ROSs that initiate the LPO reaction also cause a decrease in cellular antioxidant defense systems [16]. MDA caused by ROS-associated LPO reaction is responsible for tissue damage [17]. Therefore, ischemia duration is reduced and the damage occurring during reperfusion period is minimized with early diagnosis and appropriate treatment methods [18]. Living organisms develop a large number of protection mechanisms (antioxidants) in their cells against the harmful effects of ROSs. These mechanisms exert their effects both by inhibiting the production of radicals and preventing the detrimental effects of the radicals formed [19]. However, if the naturally occurring

antioxidants are insufficient in neutralizing ROSs, the oxidant/antioxidant balance is disrupted in favor of the oxidants and oxidative damage is observed. Therefore, antioxidants are highly important in the prevention and treatment of various tissue damages related to oxidative stress [20].

In our study, we investigated the effect of rutin against I/R oxidative damage and found that rutin significantly prevented the increase in MDA and MPO levels in rat intestinal tissue and the decrease in tGSH and CAT levels. This shows that rutin inhibits the disruption of oxidant/antioxidant balance in favor of the oxidants in the intestinal tissue, which occurs during the I/R procedure. Nayki et al. reported that rutin significantly inhibited I/R-related MDA increase in ovarian tissue [21].

Rutin was also reported to protect the stomach from I/R oxidative damage by preventing the increase in MPO activity in gastric tissue [22]. MPO enzyme is specific for polymorphonuclear leukocytes (PNL) in the tissue. PNLs accelerate the production of ROSs in the ischemic tissues via the myeloperoxidase (MPO) enzyme systems they contain, and cause $O_2^{\cdot-}$ formation. The resulting superoxide reacts with MPO to produce more reactive oxygen radicals such as H_2O_2 , OH , hypochloric acid, and N-chloramine, all of which cause an increase in tissue damage [16].

Our results show that the oxidant/antioxidant balance in the I/R treated small intestinal tissue is disrupted in favor of the oxidants. This indicates that endogenous antioxidants are inadequate in reducing I/R-related oxidative stress in the intestinal tissue. However, the fact that tGSH level in the rutin group was very close to that of the healthy group indicates that rutin prevents the oxidant/antioxidant balance in intestinal tissue from changing in favor of the oxidants. GSH is a tripeptide consisting of L-glutamate, L-cysteine, and glycine and it is found in many cells. Catalyzed by the enzyme glutathione peroxidase (GPx) which contains selenium in its active zone, GSH reacts with H_2O_2 and organic peroxides and shows antioxidant activity by removing H_2O_2 from the cells. GSH chemically detoxifies H_2O_2 and organic oxides and protects cells from ROS damage [19]. Although there are no studies investigating the effect of rutin on the amount of tGSH in I/R administered intestinal tissue, it has been shown to prevent the decrease of tGSH due to I/R in ovarian tissue [21]. Another parameter used to evaluate antioxidant activity is the CAT enzyme. This enzyme catalyzes hydrogen peroxide to molecular oxygen and water [23], and is mostly localized in peroxisomes. It is found in high amounts in blood, bone marrow, mucosa structures, liver, and kidneys [24]. Arslan A et al. also used CAT as an antioxidant parameter to evaluate oxidative damage in the small intestine [25].

In this study, our biochemical results were consistent with histopathological findings. I/R procedure was shown to cause a significant increase in PNL infiltration in the intestinal tissue. As is known, the accumulation of PNL in tissues is an indication of inflammatory reaction in the tissue. Tuboly E et al. reported that PNL infiltration is an important component in the development of intestinal tissue damage. In addition, they stated that the inhibition of PNL infiltration was important in the treatment of intestinal I/R injury [26]. As can be seen from our experimental results, PNL infiltration was more severe in intestinal tissue with high MPO activity. This is because MPO

has been shown to be an activated PNL product. The results of Zheng X et al. also support our histopathological findings [27]. Furthermore, significant edema was detected in the intestinal tissue treated with I/R. In their study, Teke Z et al. reported that edema associated with I/R oxidative injury decreased with antioxidant therapy [28]. In the present study, it was shown that I/R procedure caused histopathological findings in the intestinal tissue such as hemorrhage and destruction. In the experimental study of Soydan G et al, it was emphasized that structural disorders developed in the intestinal tissue after I/R [29]. In the literature, histopathological findings such as destruction, hemorrhage, PNL infiltration, and edema have been associated with oxidative stress [30]. It is known that rutin has antioxidant and anti-inflammatory effects. However, there are no biochemical and histopathological studies investigating the protective effect of rutin on intestinal I/R injury. On the other hand, there are histopathological studies showing that rutin prevents I/R damage in different organs and tissues through its antioxidant and anti-inflammatory effects [21,22].

Evaluating the effects of rutin on ischemia and reperfusion periods separately reveals more information about the treatment strategies and examining the biochemical and histopathological effects of rutin at different doses informs about the dose-dependent improvement. The dose dependent effect of rutin needs to be shown for clinical usage. All the above-mentioned limitations of this study exist due to the lack of resources, but future studies are planned accordingly.

Conclusion

I/R procedure caused an increase in enzymatic and non-enzymatic oxidant parameters and a decrease in antioxidant parameters in intestinal tissue. This shows that I/R creates oxidative stress in the intestinal tissue. Biochemical and histopathological investigations revealed that rutin inhibits I/R related oxidative damage in intestinal tissue. This property of rutin suggests that it may be useful in clinical settings against I/R oxidative damage in intestinal tissues.

References

- Dixon MF. The small intestine. In: Whitehead R (Eds). *Gastrointestinal and Oesophageal Pathology*. Livingstone: Churchill, 1995, 665-77.
- Vejchapiat P, Williams SR, Spitz L, Pierro A. Intestinal metabolism after ischemia reperfusion. *J Pediatr Surg*. 2000;35:759-64. doi:10.1053/jpsu.2000.6062.
- Suleyman H, Gul V, Hirik E. Ischemia-Reperfusion Damage. *Erzincan Tıp Dergisi*. 2018;1:54.
- Belda-Antoli M, Padrón-Sanz C, Cejalvo-Lapeña D, Prieto-Moure B, Lloris-Cejalvo JM, Lloris-Carsi JM. Antioxidant potential of Himanthalia elongata for protection against ischemia reperfusion injury in the small bowel. *Surgery*. 2017;162:577-85. doi:10.1016/j.surg.2017.04.017.
- Toyokuni S. Reactive oxygen species induced molecular damage and its application in pathology. *Pathology international*. 1999;49:91-102. doi:10.1046/j.1440-1827.1999.00829.x.
- Saleh H, El-Shorbagy HM. Mechanism underlying methyl eugenol attenuation of intestinal ischemia/reperfusion injury. *Appl Physiol Nutr Metab*. 2017;42:1097-105. doi: 10.1139/apnm-2017-0043.
- Harborne JB. Nature, distribution and function of plant flavonoids. *Prog Clin Biol Res*. 1986;213:15-24.
- Ganeshpurkar A, Saluja AK. The pharmacological potential of rutin. *Saudi Pharm J*. 2017;25:149-64. doi: 10.1016/j.jsps.2016.04.025
- Topal I, Akbulut UE, Cimen O, Kolkiran A, Akturan S, Cimen FK, et al. Effect of Rutin on Cisplatin-induced Small Intestine (jejunum) Damage in Rats. *Int J Pharmacol*. 2018;14:1136-44.
- Demiryilmaz I, Turan MI, Kisaoglu A, Gulapoglu M, Yilmaz I, Suleyman H. Protective effect of nimesulide against hepatic ischemia/reperfusion injury in rats: effects on oxidant/antioxidants, DNA mutation and COX-1/COX-2 levels. *Pharmacol Rep*. 2014;66:647-52. doi: 10.1016/j.pharep.2014.02.015.
- Ohkawa H, Ohishi N, Yagi K. Assay for lipid peroxides in animal tissues by thiobarbituric acid reaction. *Anal Biochem*. 1979;95:351-8.
- Bradley PP, Priebe DA, Christensen RD, Rothstein G. Measurement of cutaneous inflammation: estimation of neutrophil content with an enzyme marker. *J Invest Dermatol*. 1982;78:206-9.
- Sedlak J, Lindsay RH. Estimation of total, protein bound, and nonprotein sulfhydryl groups in tissue with Ellman's reagent. *Anal Biochem*. 1968;25:192-205.
- Aebi H. Catalase in vitro *Methods Enzymol* 1984;105:121-6.
- Granger D. Ischemia reperfusion injury: role of oxygen derived free radicals. *Acta Physiol Scand Suppl*. 1986;548:47-63.
- Carden DL, Granger DN. Pathophysiology of ischaemia reperfusion injury. *J Pathol*. 2000;190:255-66. doi: 10.1002/(SICI)1096-9896(200002)190:3<255::AID-PATH526>3.0.CO;2-6.

- Sasaki M, Joh T. Inflammation and Ischemia Reperfusion Injury in Gastrointestinal Tract and Antioxidant, Protective Agents. *Journal of clinical biochemistry and nutrition*. 2007;40:1-12. doi: 10.3164/jcfn.40.1.
- Paradowski PT, Zeman K. [Pentoxifylline]. *Postepy Hig Med Dosw*. 1995;49:201-20.
- Murray RK, Granner DK, Mayes PA, Rodwell VW. *Harper's biochemistry: a LANGE medicinal book*. McGraw-Hill; 2000.
- Kisaoglu A, Borecki B, Yapca OE, Bilen H, Suleyman H. Tissue damage and oxidant/antioxidant balance. *Eurasian J Med*. 2013;45:47. doi: 10.5152/eajm.2013.08.
- Nayki C, Nayki U, Keskin Cimen F, Kulhan M, Yapca OE, Kurt N, et al. The effect of rutin on ovarian ischemia reperfusion injury in a rat model. *Gynecol Endocrinol*. 2018;34:809-14. doi: 10.1080/09513590.2018.1450378.
- Liu Y, Gou L, Fu X, Li S, Lan N, Yin X. Protective effect of rutin against acute gastric mucosal lesions induced by ischemia reperfusion. *Pharm Biol*. 2013;51:914-9. doi: 10.3109/13880209.2013.771375.
- Kirkman HN, Gaetani GF. Catalase: a tetrameric enzyme with four tightly bound molecules of NADPH. *P Natl Acad Sci USA*. 1984;81:4343-7. doi: 10.1073/pnas.81.14.4343
- Scibior D, Czczot H. Katalaza-budowa, właściwości, funkcje [Catalase: structure, properties, functions]. *Postepy Hig Med Dosw (Online)*. 2006;60:170-80.
- Arslan A, Ozcicek A, Suleyman B, Coban TA, Cimen FK, Nalkiran HS, et al. Effects of nimesulide on the small intestine mucositis induced by methotrexate in rats. *Exp Anim*. 2016;15:0122. doi: 10.1538/expanim.15-0122.
- Tuboly E, Futakuchi M, Varga G, Érces D, Tökés T, Mészáros A, et al. C5a inhibitor protects against ischemia/reperfusion injury in rat small intestine. *Microbiol Immunol*. 2016;60:35-46. doi: 10.1111/1348-0421.12338.
- Zheng X, Mao Y, Cai J, Li Y, Liu W, Sun P, et al. Hydrogen rich saline protects against intestinal ischemia/reperfusion injury in rats. *Free Radic Res*. 2009;43:478-84. doi: 10.1080/10715760902870603.
- Teke Z, Bostanci EB, Yenisey C, Sacar M, Simsek NG, Akoglu M. Caffeic acid phenethyl ester alleviates mesenteric ischemia/reperfusion injury. *J Invest Surg*. 2012;25:354-65. doi: 10.3109/08941939.2012.677968.
- Soydan G, Sokmensuer C, Kilinc K, Tuncer M. The effects of sildenafil on the functional and structural changes of ileum induced by intestinal ischemia reperfusion in rats. *Eur J Pharmacol*. 2009;610:87-92. doi: 10.1016/j.ejphar.2009.03.038.
- Gordeeva AE, Temnov AA, Charnagalov AA, Sharapov MG, Fesenko EE, Novoselov VI. Protective Effect of Peroxiredoxin 6 in Ischemia/Reperfusion Induced Damage of Small Intestine. *Dig Dis Sci*. 2015;60:3610-9

This paper has been checked for language accuracy by JOSAM editors.
The National Library of Medicine (NLM) citation style guide has been used in this paper.