


The Preventive Effect of Thymoquinone and Ceratonia Siliqua L. in Experimental Asthmatic Pregnant Rats: Histologically and Immunohistochemically Evaluation

Ameerah Fadhil Ahmed, Sule Coskun Cevher 
Gazi University, Department of Biology, Ankara, Turkey

ABSTRACT

There are no studies yet have been compared pregnant rat asthma models by assessing the airway both histologically and immunohistochemically under the effect of Thymoquinone (TQ) and Ceratonia siliqua (CS) (Carob). To compare asthmatic pregnant models with TQ and CS by studying changes of both the histologically and the immunohistochemically of lung tissue using light microscopy. 18 female wistar rats were randomly split to 3 groups: asthmatic pregnant group (I) sensitized by intraperitoneal ovalbumin injection (OVA) with alum on days 0 and 14 and submitted to OVA aerosolized 3 days in excess of the next 1 week then they coupled with male rats to get pregnancy; asthmatic pregnant with TQ and CS group (II) sensitized as above then they administered each of TQ and CS on the last 5 days of pregnancy; and asthmatic pregnant with dexamethasone group (III) that received dexamethasone by intraperitoneal injection on last 5 days of pregnancy. Lung tissue immunohistochemically and histologically were evaluated. Various histological changes in lung tissues of group I were revealed. However, treatment of TQ and CS was prevented these changes in group II. Immunohistochemically, vascular endothelial growth factor (VEGF) staining levels increase was observed in group I, while there was a significant decrease in group II than it is in group III. In this study, the use of TQ and CS has been shown to alleviate the histological changes and immunohistochemically caused by asthma. In conclusion, TQ and CS was thought to be a promising treatment agent for asthma in the future especially during pregnancy. The use of TQ and CS in people with normal asthma may be used as a new promising supplement to eliminate the negative effects of asthma.

Keywords:

Rats; Asthma; Remodeling; VEGF; Nebulized ovalbumin; Thymoquinone; *Ceratonia siliqua*.

INTRODUCTION

Asthma is one of the farthest extensive obstinate diseases in the world and it is approximate that out of 300 million of the world's population is suffering from asthma [1]. Asthma is a chronic inflammatory illness that define with airway hyperresponsiveness and reversible airflow restriction [2]. Sensitization to antigens is thought to be a obligatory for starting the inflammatory series in asthma attack, and constant exposure to allergen occasion inflammation of the airway mucosa and submucosa, coordinate by type 2 helper T (TH2) cells [3]. Asthma animal models have spotlight the significance of TH2-driven allergic reaction in the evolution of asthma [4]. In asthma textural changes known as airway remodeling may causing by permanent inflammation [5]. Smooth muscle hypertrophy, goblet cell

hyperplasia, subepithelial fibrosis and angiogenesis are included of respiratory remodeling [6]. At the same time, bronchial epithelium damage is observed as a result of hyperactivity of the bronchi. Epithelial damage is caused by eosinophil infiltration followed by degradation of eosinophils and release of toxic granular proteins [7, 8]. As a result of the development of edema simultaneously with the cellular and molecular changes observed in the respiratory tract, episodic dyspnoea (shortness of breath) occurs as a result of narrowing of the bronchi with mucosal edema typical of asthma. Strong anti-inflammatory drugs, such as inhaled corticosteroids and anti-leukotrienes, are the basis for the treatment of asthma symptoms in the long term [9]. In spite of these drugs are efficient, also they have side effects. Thus in collateral with

Article History:

Received: 2019/06/16

Accepted: 2019/07/30

Online: 2019/09/30

Correspondence to: Ameerah Fadhil

Ahmed Ahmed,

Gazi University, Biology, 06500, Ankara,

TURKEY

E-Mail: emire.ahmed80@gmail.com

current medicines, scientists are in work with classic or popular medicines. *Nigella sativa* L. is one of these medicines, has become apply as classic therapy of asthma and other inflammatory diseases. Both in vitro and in vivo models, Thymoquinone (TQ) active component of *N. sativa* has been searched for its anti-oxidant, anti-inflammatory and anticancer properties [10]. An inflammatory change combined with asthma is preventing by the strong inhibitor TQ [11]. It is forbids T helper 2 (Th2) cytokines, eosinophil infiltration and reduces allergic airway inflammation; this proof indicates its prospective anti-inflammatory role along the allergic reaction in the lung. In spite of these, few are known about the agent and mechanisms principal underlying these all effects [12]. The formation of 5-hydroxyeicosatetraenoic acid, as well as 5-lipoxygenase, inhibits by TQ [13].

Also for the time being, *Ceratonia siliqua* L. CS (carob) it have been interest and has played an important economic role for its used as food contribution as well as in the pharmaceutical and cosmetic industries [14]. Carob seeds are in particular substantial fount of compound polymers of flavonoids such as proanthocyanidin, ellagitannin and gallotannin. These phytochemicals have been used in medicine because of their pharmacological advantages over many diseases and have free radical scavenging actions [15]. It was discovered that the carob fruit contains 24 different phenolic compounds as well as the most commonly found is gallic acid [16]. Carob powder is a precious reference of vitamins E, D, C, Niacin, B6, and folic acid; vitamins A, B2, and B12 are provided in fewer levels. And it is oil constitute of 17 fatty acids, mainly oleic, linoleic, palmitic, and stearic acid respectively at 40.45%, 23.19%, 11.01%, and 3.08% [17]. A source of bioactive ingredient found in carob fruit is called D-Pinitol, that it can be carry out by a few methods like supercritical fluids and using ion exchange resins [18, 19]. The relationship between d-pinitol and diabetes is an important subject for worldwide and there are different investigations about this subject [20, 21].

Oxidative stress OS and nitrosative stress NS are the injurious efficacy of free radicals causing possible biological harms [22, 23, 24]. To forbidding damaging effects against OS, cells have many preventive mechanisms called antioxidant defense system [25]. A large number of medicinal and racy plants, as well as fruits and leaves of some berry herbs, biosynthesis phytochemicals have antioxidant effects and may be used as a native origin of free radical scavenging compounds was show off by a lot of studies [26].

Natural products have an increasing interest in foodstuffs because of the potential negatory efficacy of artificial nutrition additions on human healthiness as well as in last years the increase of customer sensation. As far as it can be

determined by our literature research until now no studies have been declared on the antioxidant capacity and antiasthmatic role of the CS combined with TQ supplement used in this study especially its effect on asthmatic pregnant.

The objective of this research was to identify the effectiveness of TQ and CS co-administration on lung tissue in the pregnant rats with asthma as histologically and immunohistochemically.

MATERIALS AND METHODS

Experimental Animals and Ethical Approval

Wistar albino 18 female rats with range of weight 200–250 g were provided from the GU Laboratory Animal Breeding and Experimental Research Center (GUDAM, Ankara, Turkey), and were hold in three groups, every group having six rats. The animals were hold at $20 \pm 2^\circ\text{C}$ with 12:12 h adverse, light/dark period and dedicated free entrance to usual laboratory food for rodent with water in stainless birdcages, and be given humane maintenance accordingly to the scale outlined in the Guide for the Care and Use of Laboratory Animals. This study was certified by Ethics Committee of the Science Faculty of Gazi University (Code No: G. U. ET-16. 035).

Experimental Design

The rats were at random disunited into three groups every having six rats. Group I (asthmatic pregnant): they were induced to asthma by OVA. Group II (asthmatic pregnant with TQ and CS treated): the asthmatic rats received 10mg/kg/day each of TQ and CS once a day during last 5 days of pregnancy. Group III (Asthmatic pregnant with Dexamethasone treated): the rats received 1mg/kg/day Dexamethasone [27] once a day during last 5 days of pregnancy.

TQ was dissolved in normal saline (PF %0, 9 isotonic) 10mg/kg [28] using water bath kept at 60°C and the solution was prepared fresh just before gavage administration. CS was dissolved in normal saline (PF %0, 9 isotonic) at room temperature.

Sensitization and Inhalational Exposure

Groups of OVA were sensitized to ovalbumin (grade V, ref. A5503-1G, Sigma Aldrich), in accordance with the procedures of Moura et al. [29] and Yang et al. [30]. They were effective sensitized by intraperitoneally injections (i.p.) of OVA (1mg/mL saline) with alum (1mg/mL normal saline) (Reagent grade, 239186-25G, Sigma Aldrich) that an adjuvant on days 0 and 14. Rats were challenged

for 30 min with inhalation of OVA by a nebulizer (Handyneb, SN. NGM 769576) coupled to a plastic box on the days 21, 22 and 23. After the last inhalation of OVA rats were coupled with male rats (1 male each of 3 females). After proving rat's pregnancy by the veterinarian (between 11-13 pregnant days), they were attacked of asthma by a second doses of OVA (5mg/mL) inhalation for 3 days. Then in last 5 days of pregnancy rats in group II were received mix of TQ (274666-5G, Sigma Aldrich) and SC (Carob powder from herbalist) solutions by intragastric gavage and rats in group III were received dexamethasone doses by i.p injection.

Histological Study

All rats were anaesthetized by an injection of ketamine (40 mg/kg) and xylazine (2 mg/kg) intramuscularly. After death of all animals lung samples were dissected immediately, well washed with saline and in 10% neutral-buffered formalin were fixed for 72 h at least. For half an hour all the samples were washed in tap water, in ascending grades of alcohol (absolute 70% - 90% - 95%) were dehydrated, cleared in xylene and then in paraffin wax were embedded . For light microscopic examination, serial sections of 6 µm thick were cut and stained with hematoxylin and eosin (H&E). In many days later the sections were viewed and photographed by Olympus BX51 microscope (Olympus Optical Co. Ltd, Tokyo, Japan) [31].

Immunohistochemically Method

An avidin-biotin-complex (ABC) for formalin-fixed paraffin-embedded tissues immunohistochemical staining method was used [32]. From each paraffin block, successive sections of 5 µm of tissue were cut, then on glass slides prepared and desiccated. In xylene, tissues were deparaffinized then in graded alcohol solutions rehydrated. For blocking the action of endogenous peroxidase, 3% hydrogen peroxide in pure methanol was used for 20 min at room temperature. In a microwave the tissues were vaporized for 10 min using 0.01 M sodium citrate solution at pH 6.8 for retrieve the antigen. For 10 min at room temperature, Non-specific protein linking was saturated

using 4% horse serum (Invitrogen, Burlington, Ontario) in phosphate buffered saline (PBS). By application the diluted primer VEGF to tissue segments, the slides incubated 1 hour in room temperature. In accordance with the manufacturer's directions (Vector Laboratories; Vecastain Elite ABC kit) reagent (ABC) was made and applied for 30 min in room temperature. Coloration improved by applying diaminobenzinetetrahydrochloride (DAB) reagent (Sigma Aldrich) for 10 min. For counterstained the tissues, hematoxylin were applied, then in graded alcohol dehydrated and affixed with cover glass. Semi quantitative method was used. 0: no staining, 1: low staining, 2: moderate staining, 3: severe staining.

Statistical Analysis

Submits of data was performed by means (SD) and ranges (minimum-maximum) between-group comparisons were made using Tukey. A statistically significant was counted by value of P <0.05 and these statistical analysis was made by using version 11 of the SPSS software package (SPSS Inc, USA).

RESULT AND DISCUSSION

Histological Results of Lung Tissues

When the general histological structure of the groups was evaluated, group I increased inflammatory cell and eosinophils infiltration around the bronchi and bronchiole walls, increased subepithelial smooth muscle thickness and epithelial cell lengths was noticed. In group II decreased inflammatory cell infiltration, subepithelial smooth muscle and epithelial cell lengths were normal. The administration of dexamethasone revealed a very mild regulation in all of the histological finding associated with asthma (Fig. 1: A, B and C) (Table1).

Di Cosmo et al [33] showed that OVA treatment of animals significantly participated in the bronchial constriction and damage of lung tissue. Wills-Karp et al [34] were noticed that OVA sensitization of animals led to significant in-

Table 1. H & E histological semiquantitative evaluation in lung tissue.

Groups	Inflammatory cell and eosinophils infiltration around the bronchi and bronchiole walls	Subepithelial smooth muscle thickness	Epithelial cell lengths
Asthmatic Pregnant (I)	+++*	+++*	+++*
Asthmatic Pregnant with TQ & CS(II)	+++	+++	+++
Asthmatic Pregnant with Dexamethasone(III)	++**	++**	++**

*: Significant increase, **: Significant decrease.
P < 0.05

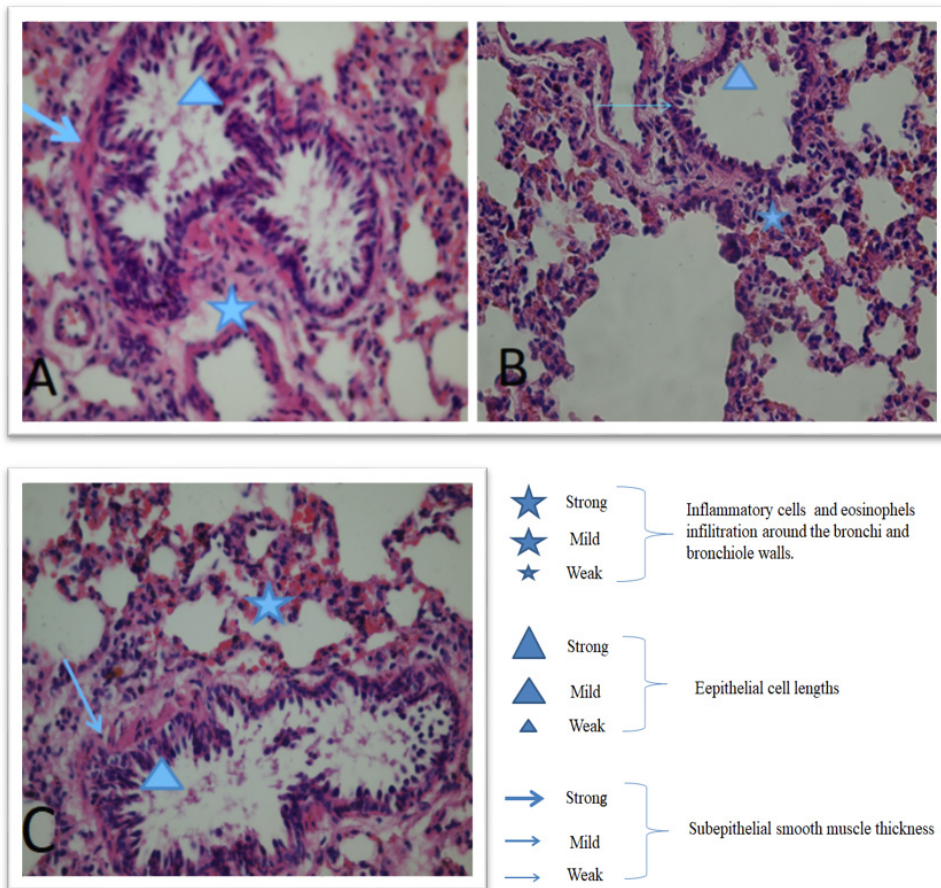


Figure 1. (A) Lung sections of asthmatic pregnant rat. Increased inflammatory cell and eosinophils infiltration around the bronchi and bronchiole walls (★), subepithelial smooth muscle thickness (→) and epithelial cell lengths (▲) X40, H&E. (B) Lung sections of asthmatic pregnant rat with TQ and CS. Inflammatory cell infiltration (★), subepithelial smooth muscle thickness (→) and epithelial cell lengths (▲) were normal. X40, H&E. (C) Lung sections of asthmatic pregnant rat with Dexamethasone. Very mild regulation in all of the histological finding associated with asthma (★, →, ▲) X40, H&E.

filtration of inflammatory cells into the lung as observed by bronchoalveolar lavage and histological examination. In the study of Serap CM et al [35] inflammatory cell infiltration and epithelial damage were observed in the lung tissues of asthmatic mice.

Similar findings were found in our study in accordance with the above studies. The above mentioned studies support our work. In present study OVA – induced asthma in group I was significantly increased the inflammatory cell and eosinophils infiltration around the bronchi and bronchiole walls, increased subepithelial smooth muscle thickness and epithelial cell lengths ($p < 0.05$). In group II the histological changes in group I were significantly decreased ($p < 0.05$). This study is quite remarkable in that it is the first study showing the effects of the combined use of TQ and CS on pregnant rats. However, only use of TQ has been shown similar results in the lungs of asthmatic mice [35, 36]; to date, there is no study showed the effective role of carob in the alleviation or treatment of asthma.

In III group the use of dexamethasone as a treatment of asthma was significant decreased the inflammatory cell and eosinophils infiltration around the bronchi and bronchiole walls, subepithelial smooth muscle thickness and epithelial cell lengths in the lung tissues of rats ($p < 0.05$) however, dexamethasone's effect was less than it is in group II. Dex from glucocorticoids is frequently used in models of allergic asthma as standard reference [37]. Glucocorticoids extremely block T cell pro-inflammatory cytokine manufacture and that's why decrease infiltration of inflammatory granulocytes as eosinophils [38, 39].

Our results show similar findings with the results of the above-mentioned investigators, and the co-administration of TQ and CS contributed to healing by reducing the signs of inflammation associated with asthma.

VEGF Immunohistochemistry

The immunohistochemically finding was significantly increased in subendothelial VEGF in group I when com-

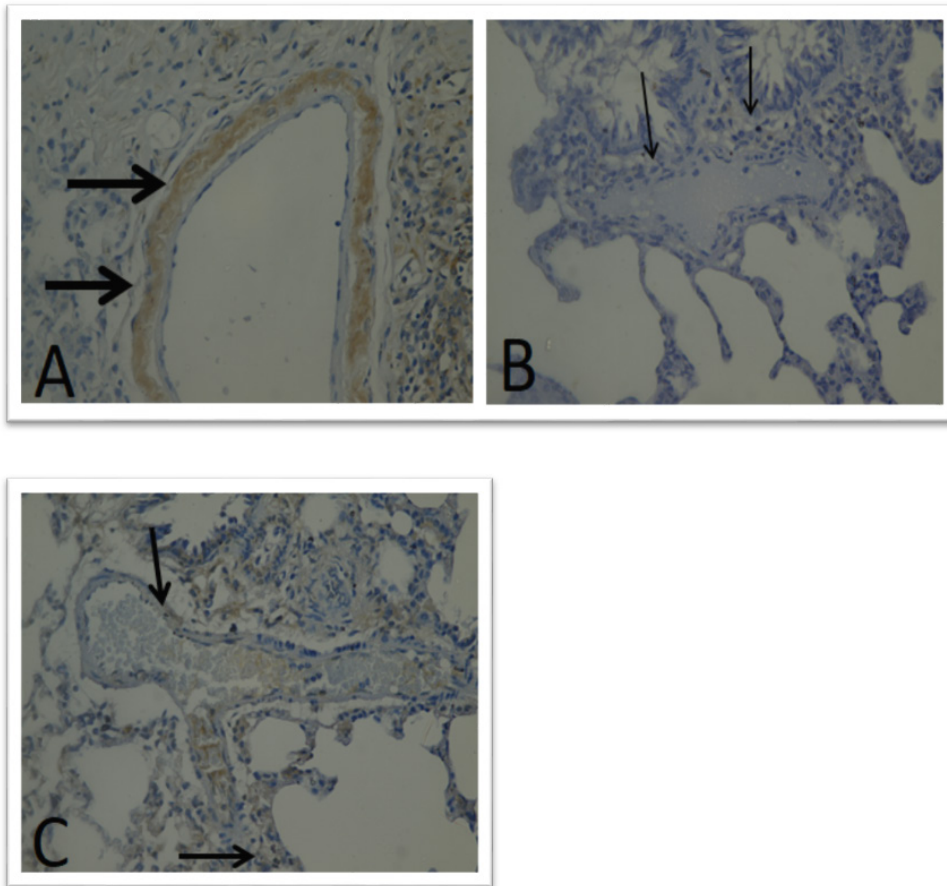


Figure 2. (A) Lung sections of asthmatic pregnant rat. VEGF positive stained, showing increased. Subendothelial VEGF levels (→) X40, VEGF Immunohistochemical staining. (B) Lung sections of asthmatic pregnant rat with TQ and CS. Subendothelial VEGF levels significantly decreased (→) X40, VEGF Immunohistochemical staining. (C) Lung sections of asthmatic pregnant rat with Dexamethasone. Subendothelial VEGF levels was decreased (→) X40, VEGF Immunohistochemical staining.

pared to both of group II and group III ($p < 0.05$). In group II subendothelial VEGF was significantly decreased when compared to I and dexamethasone group ($p < 0.05$). When compared to group II and Group III, decreased subendothelial VEGF level found in the co-administration of TQ and CS group (Fig. 2) (Table 2). This finding indicated that co-administration of TQ and CS decreased subendothelial VEGF level that plays a key role in angiogenesis.

Asthma develops as a result of chronic inflammation and remodeling in the respiratory tract [40]. Findings such as increased vascularity and increased number of blood vessels in submucosal patients have raised this question. The increase in the number of vessels is mainly due to factors

related to endothelial cell proliferation [41]. Angiogenesis occurs due to the differentiation and proliferation of endothelial cells and vascular permeability and VEGF plays a key role in the process of asthma [42].

Serap CM et al observed that submucosal immunopositive vessels in chronic asthma group increased significantly [35]. Enhancement in vascular format, number and exterior space and ultra-structure of VEGF and VEGF receptors is greatly certified in asthma airway [41, 43, 44, 45, 46]. In our study, the subendothelial VEGF level was significantly increased in asthma group ($p < 0.05$). The result of Serap CM et al [35] confirms our result of asthma group increasing angiogenesis.

Table 2. Immunohistochemistry of subendothelial VEGF in lung tissue.

Groups	Asthmatic pregnant (I)	Asthmatic pregnant with TQ&CS (II)	Asthmatic pregnant with Dexamethasone (III)
Subendothelial VEGF	+++*	+++	+++*

+: Significant increase, **: Significant decrease.
 $P < 0.05$

Serap CM et al demonstrated that the application of TQ alone in asthmatic mice decreased submucosal VEGF and epithelial VEGF [35]. This finding was similar to our result. Subendothelial VEGF was significantly decreased ($p < 0.05$) in group II. In our study, the co-administration of TQ and CS together in the lungs of asthmatic pregnant rats was alleviated or treated the damages caused by OVA.

Although TQ has been reported to reduced asthma symptoms and inflammatory markers, there is no literature on the effect of TQ and CS on concomitant use of asthma. Respiratory response in asthma is in the form of Ig E-mediated, mast cell degranulation and histamine and leukotriene mediators. These effects in TQ show anti-inflammatory effects by inhibiting the production of leukotriene B₄, thromboxane B₂ and by inhibiting 5-lipoxygenase and cyclooxygenase pathways in arachidonic acid metabolism[47]. It has also been shown to have inhibitory effects on histamine receptors[48]. The effect of carob alone in asthmatic lung tissues of animals or patients was not described yet. This is the first report evidence the positive effect of carob and TQ in lung tissues of asthmatic pregnant rats. Preceding works have represented that locust bean juice is opulent in potassium, sodium, calcium, magnesium, iron, copper and manganese, in addition to zinc. In addition, a strong antioxidant element such as gallic acid is the very rich phenolic complex found in carob fruit (3.27 mg /g) and also high tannic acid (10.2 mg/dl) was found [49]. Phenolic compounds and zinc's antioxidant and free radical scavenging activity have previously been informed [50, 51]. In our study it can be said that the decreased in VEGF levels in lung tissue is probably the cumulative effect of antioxidant and free radical scavenger effect of carob and the decreasing angiogenesis effect of TQ.

In III group subendothelial VEGF was significantly decreased ($p < 0.05$) however the effect of dexamethasone was less than it is in co-administration of TQ and CS group. Serap CM et al [35] indicated the use of dexamethasone significantly decreased VEGF immunohistochemically changes but there is no significant between TQ and dexamethasone treated groups when it was investigated in lung tissues of asthmatic mice

Currently, drugs used in the treatment of asthma have limited effects on structural changes. Anti-leukotrienes, theophylline and inhaled corticosteroids used in asthma may be effective in reducing the structural changes in the respiratory system when used for a long time [52]. Thus a new or alternative treatment are needed especially this new treatment has little or no side effect when it will use for long time.

CONCLUSION

In the current study, co-administration of TQ and CS decreased the inflammatory cell and eosinophils infiltration, around the bronchi and bronchiole walls, of lung tissues in asthmatic treated groups compared to dexamethasone group. The results of this study demonstrate that the combined use of TQ and CS may be an total/cumulative effect of TQ's reducing the angiogenesis and the antioxidant effect of carob together. This type of application will contribute to the treatment of asthma and the prevention of attacks especially during pregnancy. At the same time, the use of TQ and CS in people with normal asthma may be used as a new promising supplement to eliminate the negative effects of asthma. Current studies will open wide prospects for the positive role of TQ and CS in alleviating and treating the symptoms of asthma.

ACKNOWLEDGEMENT

We wish to thank projects of scientific investigation (BAP) of Gazi University for their permanent concern and precious counseling in this project. Through a research Grant No. 05/2016-22 from the BAP, this work was partially supported.

References

1. Hansel TT, Barnes PJ. Novel drugs for treating asthma. *Curr Allergy Asthma Rep* 2001;1:164-73.
2. Tagaya E, Tamaoki J. Mechanisms of airway remodeling in asthma. *Allergol Int.* 2007;56:331-40.
3. Herz U, Renz H, Wiedermann U. Animal models of type I allergy using recombinant allergens. *Methods.* 2004 ;32:271-80.
4. Zosky GR, Sly PD. Animal models of asthma. *Clin Exp Allergy.* 2007;37:973-88.
5. Ramos-Barbón D, Ludwig MS, Martin JG. Airway remodeling: lessons from animal models. *Clin Rev Allergy Immunol.* 2004;27:3-21.
6. Arm JP, Lee TH. The pathobiology of bronchial asthma. *Adv Immunol* 1992; 51:323-82.
7. Gleich GJ, Adolphson CR. The eosinophilic leukocyte: structure and function. *Adv Immunol* 1986; 39:177-253.
8. Sumi Y, Hamid Q. Airway remodeling in asthma. *Allergol Int* 2007;56:341-8.
9. Atta-ur-Rahman, Malik S, Ahmed S, Choudhary MI, Habib-ur-Rehman. Nigellimine-N-oxide A new isoquinoline alkaloid from the seeds of *Nigella sativa*. *Heterocycles* 1985; 23:953-5.
10. Woo CC, Kumar AP, Sethi G, Tan KH. Thymoquinone: Potential Cure for Inflammatory Disorders and Cancer. *Biochem Pharmacol* 2012; 83: 443-51.
11. Ammar el SM, Gameil NM, Shawky NM, Nader MA. Comparative evaluation of anti-inflammatory properties of thymoquinone and curcumin using an asthmatic murine model. *Int Immunopharmacol*

- 2011; 11: 2232-6.
12. El Gazzar M, El Mezayen R, Marecki JC, Nicolls MR, Canastar A, Dreskin SC. Anti-inflammatory effect of thymoquinone in a mouse model of allergic lung inflammation. *Int Immunopharmacol* 2006; 6: 1135-42.
 13. Al-Gahmadi MS. The anti-inflammatory, analgesic and antipyretic activity of *Nigella sativa*. *J Ethnopharmacol* 2001;76:45-8.
 14. Sidina MM., El Hansali M, Wahid N, Ouattmane A, Boulli A, Haddioui A. Fruit and seed diversity of domesticated carob (*Ceratonia siliqua* L.) in Morocco. *Scientia Horticulturae*. 2009; 123: 110-116.
 15. Luthria D. Significance of sample preparation in developing analytical methodologies for accurate estimation of bioactive compounds in functional foods. *Journal of the Science of Food and Agriculture* 2006; 86: 2266-2272.
 16. Anonim. Ulusal Gıda Kompozisyon Veri Tabanı. 2017; www.turkomp.gov.tr/food/376 (Access Date: 11.07. 2017).
 17. Youssef, M. K. E., El-Manfaloty, M. M., & Ali, H. M. Assessment of proximate chemical composition, nutritional status, fatty acid composition and phenolic compounds of carob (*Ceratonia siliqua* L.). *Healthcare Foodservice Magazine*. 2013; 3, 304-308.
 18. Karhan, M., H. Gubbuk, İ. Turhan, H. R. Öziyici, H. Akgül, K. Uçgun. Türkiye’de yetişen keçiyoynuzu (*Ceratonia siliqua* L.) tiplerinin biyoaktif birmoleküllü D-pinitol içeriği üzerine çevre koşulları ve bileşim unsurlarının etkisi. 2010. TÜBİTAK Projesi Proje No: 107O650.
 19. Alper, Y. Keçiyoynuzu (*Ceratonia siliqua* L.) meyvesinden süperkritik karbondioksit (CO₂) ekstraksiyonu ile d-pinitol eldesi. Yüksek lisans tezi. E. Ü. Fen Bilimleri Enstitüsü Gıda Mühendisliği Anabilim Dalı Bornova- İzmir. 2016.
 20. Davis, A., M. Christiansen, J. F. Horowitz, K. M. Hellerstein, and E. R. Ostlund. Effect of pinitol treatment on insulin action in subjects with insulin resistance. *Diabetes Care*. 2000; 23: 1000-1005.
 21. Kim, J.I., Kim, J.C., Kang, M.J., Lee, M.S., Kim, J.J., Cha, I.J. Effects of Pinitol isolated from soybeans on glycemic control and cardiovascular risk factors in Korean patients with type 2 diabetes mellitus: a randomized controlled study. *European Journal of Clinical Nutri*. 2005; 59: 456-458.
 22. Kovacic P, Jacintho JD. Mechanisms of carcinogenesis: Focus on oxidative stress and electron transfer. *Current Medicinal Chemistry* 2001; 8: 773-796.
 23. Valko M, Leibfritz D, Moncol J, Cronin MTD, Mazur M, Telser J. Free Radicals and Antioxidants in Normal Physiological Functions and Human Disease. *The International Journal of Biochemistry & Cell Biology*. 2007; 39: 44-84.
 24. Gulcin I, Beydemir S. Phenolic compounds as antioxidants: carbonic anhydrase isoenzymes inhibitors. *Mini Rev Med Chem* 2013; 13 (3): 408-430.
 25. De Zwart LL, Meerman JHN, Commandeur JNM, Vermeulen NPE. Biomarkers of free radical damage applications in experimental animals and in humans. *Free Radical Biology & Medicine*. 1999; 26: 202-226.
 26. Yu LL, Zhou KK, Parry J. Antioxidant properties of cold pressed black caraway, carrot, cranberry, and hemp seed oils. *Food Chemistry*. 2005; 91: 723-729.
 27. Xie, Q.M., X. Wu, H.M. Wu, Y.M. Deng, S.J. Zhang, J.P. Zhu, X.W. Dong. Oral administration of allergen extracts from *Dermatophagoides farinae* desensitizes specific allergen-induced inflammation and airway hyperresponsiveness in rats. *Int Immunopharmacol*. 2008; 8(12): 1639-1645.
 28. Choi, Y.H., Yan, G.H., Chai, O.H., Lim, J.M., Sung, S.Y., Zhang, X., Kim, J.H., Choi, S.H., Lee, M.S., Han, E.H., Kim, H.T., Song, C.H. Inhibition of anaphylaxis-like reaction and mast cell activation by water extract from the fruiting body of *Phellinus linteus*. *Biol Pharm Bull.*; 2006; 29 (7):1360-1365
 29. Moura CTM, Bezerra FC, Moraes IM, Magalhães PJC, Capaz FR. Increase responsiveness to 5-hydroxytryptamine after antigenic challenge is inhibited by nifedipine and niflumic acid in rat trachea in vitro. *Clin Exp Pharmacol Physiol*. 2005; 32:1119-1123.
 30. Yang EJ, Lee J-S, Song BB, Yun C-Y, Kim D-H, Kim IS. Anti-inflammatory effects of ethanolic extract from *Lagerstroemia indica* on airway inflammation in mice. *J Ethnopharmacol*. 2011; 136:422-427.
 31. Hould R. 1984. Technical on histopathology and cytopathology. Maloine. 19-21:225-227.
 32. Haines DM, Chelack BJ. Technical considerations for developing enzyme immunohistochemical staining procedures on formalin-fixed paraffin-embedded tissues for diagnostic pathology. *J Vet Diagn Invest* 1991;3:101-112.
 33. DiCosmo BF, Geba gp, Picarella D, Elias JA, Ranking JA, Stripp BR, Whetsett JA, Favell RA. Airway epithelial cell expression of interleukin-6 in transgenic mice. Uncooupling of airway inflammation and bronchial hyperreactivity. *J Clin Invest*. 1994; 94:2028-2035. [PubMed: 7962549]
 34. Wills-Karp M, Gavett SH, Schofield B, Finkelman F. Role of interleukin-4 in the development of allergic airway inflammation and airway hyperresponsiveness. *Av Exp Med Biol*. 1995; 409:343-347.
 35. Serap C.M., Serdar K., Tolgahan A., Hüsni A B., Gonca K., Gökçen Ö Ş., Tuncay Ş., Osman Y. The effectiveness of thymoquinone in experimental model of asthma and role of vascular endothelial growth factor. *Smyrna Med.J*. 2013; 3: 34- 39. [https:// ISSN: 2146-670X](https://doi.org/10.21467/ISSN:2146-670X).
 36. S. Kalemci , S. Cilaker Micili , T. Acar , T. Senol , N. Dirican, G. Omeroglu , A. Bagriyanik , G. Kamaci , O. Yilmaz. Effectiveness of thymoquinone in the treatment of experimental asthma. *Clin Ter* 2013; 164 (3):e?????. doi: 10.7417/CT.2013.1559.
 37. Das, A.M., R.J. Flower, P.G. Hellewell, M.M. Teixeira, M. Perretti, 1997. A novel murine model of allergic inflammation to study the effect of dexamethasone on eosinophil recruitment. *Br J Pharmacol.*, 121: 97-104. de Matos, O.G., S.S. Amaral, P.E. Pereira da Silva, D.A. Perez, D.M. Alvarenga, A.V. Ferreira, J.
 38. Abeer A.A. Salama., Hala F. Zaki., Siham M. El-Shenawy., EL-Denshary E.S.M., Ismaiel ElKassaby Ismaiel and Nermeen M. Shaffie. Effects of Fish oil and Dexamethasone in Experimentally-Induced Bronchial Asthma. *Australian J. of Basic and Applied Sciences*, 2012 6(13): 497-506. ISSN 1991-8178.
 39. Corrigan, C. 2012. Mechanisms of asthma. *Medicine.*, 40 (5): 223-227.
 40. Bergeron C, Boulet LP. Structural changes in airway diseases: characteristics, mechanisms, consequences, and pharmacologic modulation. *Chest* 2006;129:106887.
 41. Li X, Wilson JW. Increased vascularity of the bronchial mucosa in mild asthma. *Am J Respir Crit Care Med* 1997;156:229-33.
 42. Arm JP, Lee TH. The pathobiology of bronchial asthma. *Adv Immunol* 1992;51:323-82.
 43. Chun G L., Holger L., Peter B., Robert J H., Svetlana C., Vineet B., Min J K., Lauren C., Yoon K K., Donald M M., and Jack A E. Vascular endothelial growth factor (VEGF) induces remodeling and enhances TH2-mediated sensitization and inflammation in the lung. *Nat Med* . 2004 October ; 10(10): 1095-1103. doi:10.1038/nm1105.
 44. Vrugt B, et al. Bronchial angiogenesis in severe glucocorticoid-dependent asthma. *Eur. Respir. J*. 2000; 15:1014-1021. [PubMed:

- 10885418]
45. Salvato G. Quantitative and morphological analysis of the vascular bed in bronchial biopsy specimens from asthmatic and non-asthmatic subjects. *Thorax*. 2001; 56:902-906. [PubMed: 11713351]
 46. Lee YC, Lee HK. Vascular endothelial growth factor in patients with acute asthma. *J. Allergy Clin. Immunol.* 2001; 107:1106-1108. [PubMed: 11398093]
 47. Houghton PJ, Zerka R, DL-Heras B, Hoult JR. Fixed oil of *Nigella sativa* and derived thymoquinone inhibit eicosanoid generation in leukocytes and membrane lipid peroxidation. *Planta Medica* 1995;61:33-6.
 48. Boskabady MH, Sheiravi N. Inhibitory effect of *Nigella sativa* on histamine receptors of isolated guinea pig tracheal chains. *Pharm Biol* 2002;40:596602.
 49. Ayaz F.A., Torun H., Ayaz S., Correia P.J., Alaiz M., Sanz C., Gruz J., Strand M. Determination of chemical composition of Anatolian carob pod (*Ceratonia siliqua* L.), Sugars, amino and organic acids, minerals and phenolic compounds. *J. Food Quality*. 2007; 30: 1040-1055. <https://doi.org/10.1111/j.1745-4557.2007.00176.x>
 50. Tokeshi I., Yoshimoto T., Muto N., Nakamura S., Ashizawa K., Nakada T., Tatemoto H. Antihyaluronidase action of ellagic acid effectively prevents polyspermy as a result of suppression of the acrosome reaction induced by sperm-zona interaction during in vitro fertilization of porcine oocytes. *J. Reprod. Develop.* 2007; 53: 755-764. <https://doi.org/10.1262/jrd.18173>.
 51. Osaretin A.T., Gabriel A.A. Effect of zinc deficiency on memory, oxidative stress and blood chemistry in rats. *Adv. Med. Dent. Sci.* 2008; 2: 74-82.
 52. R.W Owen, R. Hubner, W. E Hull, G. Erben, B. Spiegelhalder, H. Bartsch, B. Haber: Isolation and structure elucidation of the major individual polyphenols in carob fiber. *Food and Chemical Toxicology* 2003.41-12:1727-1738.