

In vitro fertilization pregnancy and posterior fossa abscess: case report and twin pregnancy experience

Tüp bebek gebeliği ve posterior fossa apsisi: olgu sunumu ve ikiz gebelik deneyimi

İb Tuğba Gürbüz¹, İb Oya Gökmen²

¹Medistate Hospital Gynecology and Obstetric Clinic, İstanbul, Turkey

²Medistate Hospital Gynecology and Reproductive Medicine, İstanbul, Turkey

Cite this article as / Bu makaleye atf için: Gürbüz T, Gökmen O. In vitro fertilization pregnancy and posterior fossa abscess: case report and twin pregnancy experience. J Med Palliat Care 2021; 2(3): 98-101.

ABSTRACT

The aim of the present study is to give our preoperative and postoperative care and clinical in in vitro fertilization (IVF) approach on a 23-week-old twin pregnant woman undergoing surgery for the diagnosis of brain abscess. Our case was evaluated both with findings of the neurological examination and radiological results before and after the surgery. The echocardiography (Echo) findings were normal, and hypertension was not detected in the 24-hour arterial blood pressure. The neurological examination revealed left-sided bilaterally vertical nystagmus, and no motor deficit was detected. The findings indicated a cyst wall filled with pus so-called "cold abscess". Babies were born with a weight of 1700 gr, Apgar score of 6/8, 2100 gr, and Apgar score of 8-9. Cranial and cardiac US findings were normal. Their fetal echo examinations were good, and also babies were discharged in good condition. The complaints of pregnant women about headache and dizziness at the time of admission do not only suggest intracranial pathologies, indicating preeclampsia or vertigo. A multidisciplinary approach involving neurosurgeon, obstetrician, and anesthesiologist is required to improve maternal and fetal outcomes.

Keywords: Posterior fossa, cerebellar abscess, twin pregnancy

ÖZ

Bu çalışmanın amacı, ikiz gebelik tanısı olan ve 23. gebelik haftasında beyin apsisi teşhisi konulup sonrasında acil ameliyata alınan olgumuzla preoperatif ve postoperatif bakım ve tüp bebek tedavisi yaklaşımımızı sunmaktır. Olgumuz cerrahi öncesi ve sonrası nörolojik muayene bulguları ve radyolojik sonuçlarıyla değerlendirilmiştir. Ekokardiyografi (EKO) bulguları normaldi ve 24 saatlik arteriyel kan basıncı takibinde hipertansiyon saptanmadı. Nörolojik muayenede sol taraflı iki taraflı vertikal nistagmus saptandı, motor defisiti yoktu. Bulgular "soğuk apse" adı verilen irin ile dolu bir kist duvarını göstermekteydi. Bebekler 1700 gr ağırlığında, Apgar skoru 6/8; 2100 gr, Apgar skoru 8-9 ile dünyaya geldi. Kranial ve kardiyak ultrasonografi bulguları normaldi. Fetal EKO incelemeleri iyiydi ve bebekler de iyi durumda taburcu edildi. Gebe kadınların başvuru anında baş ağrısı ve baş dönmesi şikayetleri sadece preeklampsi veya baş dönmesine işaret eden intrakraniyal patolojileri düşündürmez. Maternal ve fetal sonuçları iyileştirmek için beyin cerrahı, kadın doğum uzmanı ve anestezi uzmanını içeren multidisipliner bir yaklaşım gereklidir.

Anahtar Kelimeler: Arka çukur, serebellar apse, ikiz gebelik

INTRODUCTION

Brain abscess is a suppurative focus localized within brain tissue, starting with cerebritis and then encapsulation. They can be caused by the spread of infectious agents by the hematogenous route or adjacent focus (1). The immunosuppressive effect of the gestation period makes the expectant mother susceptible to infections. Consequently, due to the insidious occurrence of posterior fossa abscesses that are rarely seen during

pregnancy, pregnant women are usually misdiagnosed, and severe neurological deficits developed until appropriate diagnosis and establishment of treatment. In this article, the aim is to present a case of posterior fossa abscess detected by cranial Magnetic resonance imaging (MRI) in our 23-week pregnant woman who referred to the clinic with severe headache and dizziness.

Corresponding Author / Sorumlu Yazar: Tuğba Gürbüz, Medistate Hastanesi, Kadın Hastalıkları ve Doğum Kliniği, Rüzgarlıbahçe Mah. Cumhuriyet Cad. No:34, İstanbul, Türkiye

E-mail / E-posta: drtgurbuz@hotmail.com

Received / Geliş: 15.01.2021 **Accepted / Kabul:** 09.03.2021



This study was approved by the university/local human research ethics committee. All procedures performed in studies involving human participants were in accordance with the institutional and/or national research committee's ethical standards and with the 1964 Helsinki Declaration and its later amendments or comparable ethical standards. The study was carried out with the permission of the Research Ethics Committee of Beykoz University (Permission granted/CAAE number: 2020/06.11, Decision No: 2).

CASE

The case was a 32-year-old female patient with an 8-year history of primary infertility and diagnosed with polycystic ovary syndrome, obesity, and hirsutism. She underwent an in vitro fertilization (IVF) procedure, and as a result, she had a dichorionic-diamniotic twin pregnancy.

She decided to be followed in our clinic starting with the 18th week of pregnancy. She had no history of any other disease or surgery before the start of her pregnancy.

At her 23 weeks of gestation, she came to our obstetrics and gynecology outpatient clinic with a severe headache for 1-2 days, with a pain score of 8 out of 10. In the physical examination, her blood pressure was evaluated 140/90-130/90 mmHg. Considering the possibility of preeclampsia, some examinations were planned. She underwent laboratory examination, liver enzyme tests, and a hemogram and had protein in the urine, which showed normal results. Therefore, she was consulted with the Cardiology department for her high blood pressure. Echocardiography (Echo) findings were normal, and hypertension was not detected in the 24-hour blood pressure holter. On the next day, she came again with dizziness complaints accompanied by nausea and vomiting followed by the darkening of the eyes while standing up. The patient complained that she had much more problems on the left side and that she was alleviated by closing her eyes. So, a neurological consultation was done.

The neurological examination revealed left-sided bilaterally vertical nystagmus of the pregnant woman who was conscious, cooperative, and oriented, and no motor deficit was detected. Deep tendon reflex was a normoactive plantar reflex and bilateral flexor. Sensory examination was normal, and cerebellar tests revealed dysmetria on the left and minimal dysdiadokinesia. Cranial MRI was planned.

Three non-contrast cranial MRIs of 18*15 mm, 17*13 mm, and 10*8 mm in size similar to the left cerebellar hemisphere showed similar cystic degenerative areas

in central sections. T1 series peripheral hyperintense, central hypointense, T2 series, peripheral hypointense, central hyperintense structure, and diffusion MRI imaging revealed diffusion restriction and gradient-echo sequence without significant hemorrhagic component. There was widespread parenchymal edema. 4. Ventricular compression and hydrocephalus were present in the third and both lateral ventricles (**Figures 1 and 2**).

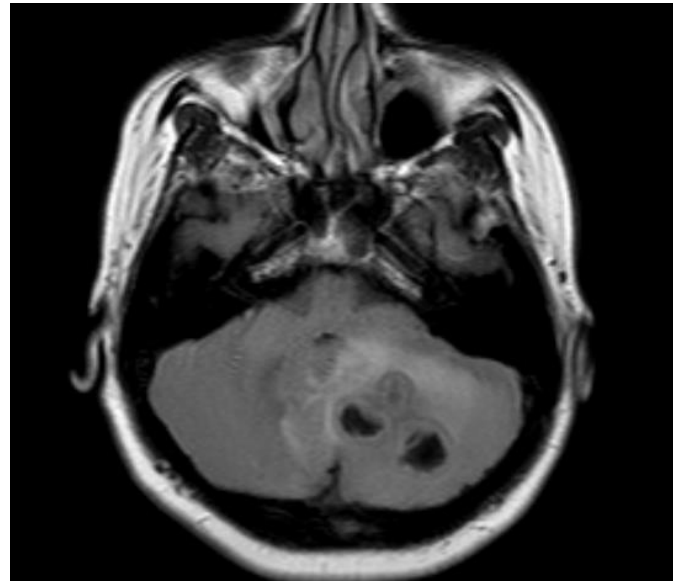


Figure 1. Pre-operative left cerebellar mass

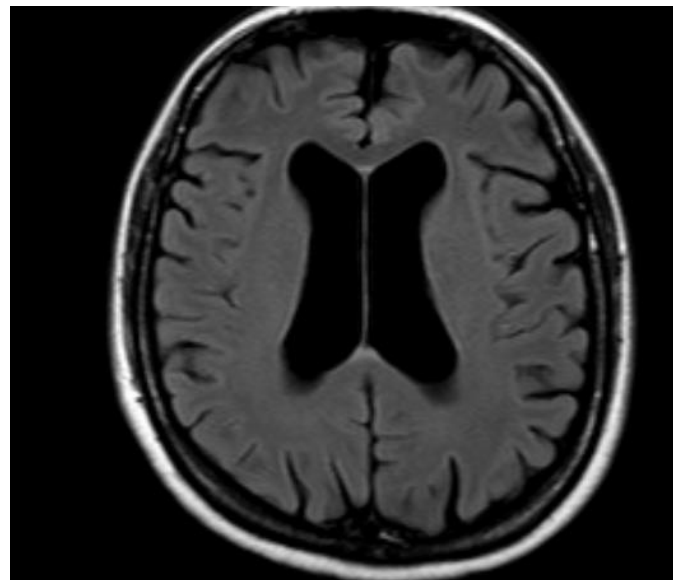


Figure 2. Preoperative lateral ventrikul hydrocephalus image

She was consulted with the neurosurgery department. The decision was first to relieve her symptoms of hydrocephalus with the external ventricular drainage system placed under local anesthesia, and then, the operation for the suspected mass will be performed by the neurosurgery team on the next day.

After taking the informed consent with the family and their relatives, they were informed that there could be an emergency cesarean section during a craniotomy operation. So, the obstetrics team was planned to be in the operation theatre.

The patient has been given 2*12 mg betamethasone for lung maturation for the possible premature birth of twin pregnancies before surgery, and also, progestin depot (Proluton Depot) 500 mg was given an intramuscular injection for uterin relaxation.

The external ventricular drainage system was placed under local anesthesia. After controlled cerebrospinal fluid drainage (CSF) (3*30 cc), the patient felt comforted.

On the following day, a craniotomy was performed for the suspected mass. The findings indicated a cyst wall filled with pus so-called "cold abscess". They cleared the pus, and a biopsy was taken from the surrounding tumor-like tissue, and a drain was placed for the leakage. Ceftriaxone and metronidazole antibiotherapy was given, and the operation was terminated. Pathological findings showed no tumor formation but an abscess. There was no growth of acid resistance bacteria in the abscess culture, which showed abundant leukocytes on gram staining, and also no growth was found in the anaerobic culture.

The patient remained in the intensive care unit for one day in the postoperative follow-up. Weekly progestin depot (Proluton Depot) 500 mg was intramuscular, and it was followed up. There was no neurological deficit in the postoperative period. In contrast-enhanced cranial MRI, the cerebellar abscess was regressed with antibiotherapy (**Figure 3-4**).

At the 34th gestational week, one of the twin babies had a low amniotic fluid index and intrauterine growth retardation, so she delivered through the cesarean section emergency. Babies were born with a weight of 1700 gr and Apgar score of 6/8, 2100 gr, and Apgar score 8-9. Mother was discharged in good condition without any cranial pathology and neurological deficit. Babies stayed in the newborn intensive care unit for 3 weeks. Cranial and cardiac ultrasonographic findings were normal. Their fetal echo examinations were good, and also babies were discharged in good condition.

DISCUSSION

Brain abscess as a life-threatening complication has a rare association with pregnancy. Despite the presence of predispositions such as foreign body, immunosuppression, or a preexisting infection, its symptoms include seizures, headache, focal neurologic deficits, and mental status changes (2). The most common symptom is headache, found in 75% of pregnant women, followed by neurological abnormalities (67%) and altered consciousness (58%)(2).

The abscess can be diagnosed with MRI or computed tomography (CT)(2). This article presented our preoperative and postoperative care and clinical approach of a 23-week-old twin pregnant woman who had undergone surgery to diagnose a brain abscess in our clinic. Our findings show that the pregnant woman's complaints about headache and dizziness at the time of admission do not suggest intracranial pathologies, indicating the possibility of preeclampsia or vertigo.

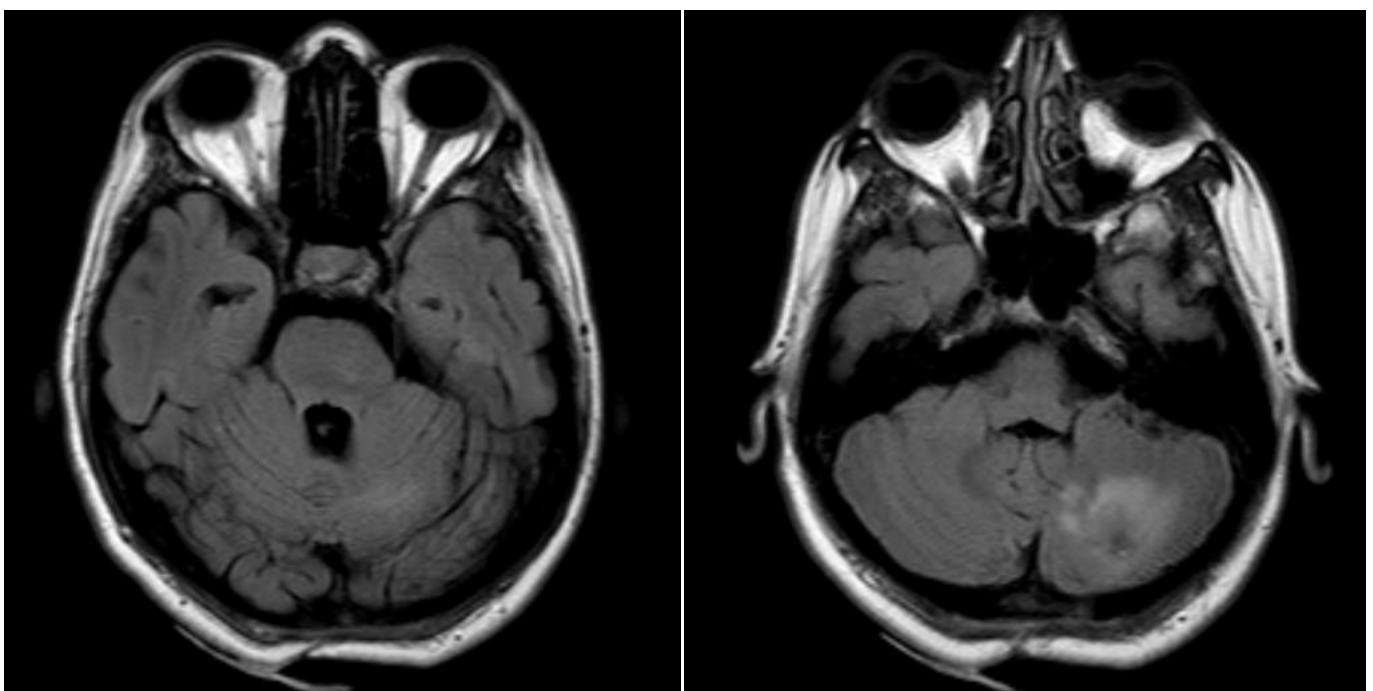


Figure 3-4. Postoperative cerebellar image. In contrast-enhanced cranial MR images, cerebellar abscess was regressed

Symptoms and signs of space-occupying lesions, especially in the posterior fossa, are seen primarily due to increased intracranial pressure and secondary to local pressure of the cerebellar nuclei and brain stem (3). Besides, CSF may cause congestion in the circulatory tract and cause hydrocephalus, and the patient may show signs and symptoms of hydrocephalus (4). Surgery and suitable antibiotic therapy should be done to treat brain abscesses successfully, and the primary source should be eradicated (5). However, antibiotherapy treatment of brain abscesses is controversial (6). The intervention of abscess through neurosurgical intervention is accepted as the most effective method (7,8). A multidisciplinary approach involving a neurosurgeon, an obstetrician, and an anesthesiologist is required to improve maternal and fetal outcomes.

CONCLUSION

It is concluded that there should be a multidisciplinary approach, including neurosurgeon, obstetrician, and anesthesiologist, to improve maternal and fetal outcomes. In addition, there should be early medical intervention to prevent brain abscess during pregnancy.

ETHICAL CONSIDERATIONS

Informed Consent: Written informed consent was obtained from the participant who participated in this study.

Referee Evaluation Process: Externally peer-reviewed.

Conflict of Interest Statement: The authors have no conflicts of interest to declare.

Financial Disclosure: The authors declared that this study had received no financial support.

Author Contributions: All of the authors declare that they have all participated in the design, execution, and analysis of the paper and approved the final version.

REFERENCES

1. Nesrin A, Çiğdem A.H, Duygu Ç, et al. Two cases of intracranial abscess caused by parvimonas micra. *Klimik Magazine* 2016; 29: 47-50.
2. Wax JR, Pinette MG, Blackstone J, Cartin A. Brain abscess complicating pregnancy. *Obstet Gynecol Surv* 2004; 59: 207-13.
3. Morelli D, Pirotte B, Lubansu A, et al. Persistent hydrocephalus after early surgical management of posterior fossa tumors: is routine preoperative endoscopic third ventriculostomy justified? *J Neurosurg* 2005; 103: 247-52.
4. Giordana MT, D'Agostino C, Pollo B, et al. Anaplasia is rare and does not influence prognosis in adult medulloblastoma *J Neuropathol Exp Neurol* 2005; 64: 869-74.
5. Arlotti M, Grossi P, Pea F, et al. Consensus document on controversial issues for the treatment of infections of the central nervous system: bacterial brain abscesses. *Int J Infect Dis* 2010; 14: 79-92.
6. Mathisen GE, Johnson JP. Brain abscess. *Clin Infect Dis* 1997; 25: 763-79.
7. Pit S, Jamal F, Cheah FK. Microbiology of cerebral abscess: a four-year study in Malaysia. *J Trop Med Hyg* 1993; 96: 191-6.
8. Ballpoint-Tigen E, Sargin F, Dogru A. Two cases of brain abscess that recurred after suboptimal surgery. *Klimik Derg* 2012; 25: 35-7.