

Our results of cardiac surgery performed with a right infra-axillary mini thoracotomy

Hüseyin Gemalmaz¹, Yıldırım Gültekin²

¹Prof. Dr. Cemal Taşçıoğlu City Hospital, Clinic of Cardiovascular Surgery, İstanbul, Turkey

²Kırıkkale University School of Medicine, Department of Cardiovascular Surgery, Kırıkkale, Turkey

Cite this article as: Gemalmaz H, Gültekin Y. Our results of cardiac surgery performed with a right infra-axillary mini thoracotomy. J Health Sci Med 2021; 4(2): 186-191.

ABSTRACT

Aim: The aim of the study is to share the technique and results of heart surgery performed with right infra-axillary mini thoracotomy.

Materyal and Method: Between March 2013 and July 2014, 16 heart operations were performed with right infra-axillary mini thoracotomy incision. Patient data were analyzed retrospectively. These are 6 mitral valve replacement (MVR), 3 aortic valve replacement (AVR), 2 AVR+MVR, 2 atrial septal defect (ASD) repair, 1 myxoma excision. One of them is AVR+tricuspid ring annuloplasty operation and MVR performed due to reoperation. Radiofrequency (RF) ablation was also applied to 1 patient who underwent MVR due to atrial fibrillation. In these operations, thoracotomy was performed through the right anterior infra-axillary line. A parabolic incision of 6-8 cm was made at the 3rd intercostal space (ICA) for aortic valve interventions and at the 4th ICA level for other valve interventions. No special surgical instruments were used in the operations except standard surgical instruments. All cannulation procedures were carried out through the existing thoracotomy incision.

Results: No mortality or morbidity was observed as a result of the operations. The mean extracorporeal circulation (ECC) time was 95±11 minutes, and the mean cross clamp (CC) time was 61±9 minutes. There was an average of 380±35 cc drainage. Extubation time was 7±2.3 hours on average. All patients were taken to the service after 1±0.5 day of intensive care treatment. They were discharged from the hospital in an average of 6±1.5 days. Incision site infection was not observed in any patient. No patients were revised due to bleeding. One patient who was ablated for atrial fibrillation (AF) developed postoperative AF again. He was discharged with medical treatment and speed control.

Conclusion: In this study, we think that heart surgeries with right infra-axillary mini thoracotomy incision may be a good alternative to standard sternotomy and other minimally invasive methods in heart surgery. With standard surgical instruments and cannulation through a single incision, not only the mitral valve but also the aortic valve, tricuspid valve and other cardiac pathologies can be easily intervened. However, very good results are obtained in patients cosmetically.

Keywords: Open heart surgery, right infra-axillary thoracotomy, heart valve replacement

INTRODUCTION

Today, median sternotomy is used as the gold standard incision for heart surgeries (1). For the first time, Lillehei et al. (2) performed a mitral valve replacement under cardiopulmonary bypass (CPB) with a right thoracotomy incision. In recent years, this incision is preferred especially in reoperations. Minimally invasive methods have long attracted the attention of cardiac surgeons due to reasons such as less need for blood transfusion, low morbidity, good cosmetic results, short intensive care and hospital stay (3).

Recently, the development of thoracoscopic and robotic technologies in the health sector has also been reflected

in minimally invasive cardiac surgery. However, their financial costs, long operation times and difficult learning process are still a major problem. Among the increasingly minimally invasive approaches, mini sternotomy, anterolateral thoracotomy, and posterolateral thoracotomy stand out. (4-6). Also, right infra-axillary mini thoracotomy is another method preferred in recent years due to its cosmetic results and surgical vision (7).

In this study, we aimed to share the results of heart surgeries performed using the right infra-axillary mini thoracotomy method, which is one of the minimally invasive methods.

MATERIAL AND METHOD

The results of 16 open heart surgeries performed using right infra-axillary mini thoracotomy method between March 2013 and July 2014 were retrospectively analyzed. Patients' data were obtained from hospital digital data and patient files. The study was conducted in accordance with the Helsinki Declaration of 1964 and later amendments or comparable ethical standards, and permission was obtained from the institution. All patients have a consent form for surgery. The study was approved by the EMSEY Hospital Ethics Committee (date: 10.8.2014, no: 2014/4).

By examining the data of the patients; diagnoses, demographic data, comorbidity, types of surgery, CC and ECC times, postoperative bleeding, amount of blood products used, reoperation due to bleeding, mechanical ventilation durations, intensive care and hospital stay, incision infection, hospital and postoperative 3-month mortality rates were evaluated.

The operations were 6 MVR, 3 AVR, 2 AVR and MVR, 2 ASD repair, 1 myxoma excision. Two patients who had previous valve replacement were operated due to paravalvular leakage. AVR and TA was applied to one of them, and MVR was applied to the other one.

This method was not applied to patients who had previously undergone thoracic surgery, received radiotherapy and whose body mass index was over 30 kg/m². Operations carried out by the same team.

Electrocardiography, invasive artery monitoring, central venous pressure monitoring and pulse oximetry monitoring were performed for all patients who were taken into the operating room. A foley urinary catheter and nasal temperature probe were routinely used before the operation. In addition, external defibrillation pads were also attached to each patient. For anesthesia, 30 minutes before the operation, 0.05 mg/kg morphine was administered intramuscularly for premedication. Intravenous 0.4 mg/kg etomidate was given for induction. Then, the neuromuscular blocker 0.8 mg/kg rocuronium was administered. Sevoflurane anesthetic was started at 2-4% MAC value. All patients were intubated endotracheally with a double lumen intubation tube. The patient was placed in a 60° anterior oblique position with the right thorax above, and a support pad was placed under the thorax to raise the thorax. The right arm was abducted approximately 120° and was suspended over the head by breaking 90° at the elbow. A 6-8 cm parabolic skin incision was made from the right anterior axillary line, targeting the 3rd intercostal space (ICS) for aortic valve interventions and the 4th ICS for other interventions. The incision started at the 2nd ICA level

and was extended to the 5th ICS level. The size of this incision may vary according to the height and weight of the patient. Except for the intercostal muscles, no muscles or ribs were cut. When the skin and subcutaneous tissues reached the target costal space, right lung ventilation was stopped and the thorax was entered. Conversion to median sternotomy was not required in any patient. The lung was excluded and the heart was reached. The pericardium was opened 2 cm above the phrenic nerve. The pericardium was hung from various points on the thorax wall with the help of multiple 1/0 silk sutures (**Figure 1**). In this way, the most appropriate exposure for the surgical procedure was achieved by ensuring that the heart came close to the right thorax. Cannulation sutures were placed. After heparinization, when the appropriate activated coagulation time (ACT) reached the value (ACT≥400 sec), the standard cannulation procedure was started. Arterial cannulation was performed from the aorta in all cases. A single two-stage venous cannula was placed through the right atrium auricle for aortic valve surgery (**Figure 2**). For others, bicaval venous cannulation was performed. Vena cava superior and vena cava inferior turned. Routinely, cardiac arrest was achieved with standard isothermal blood cardioplegia and CPB was initiated. For mitral valve interventions, the mitral valve was reached through the right atrium using the transeptal route. Mechanical prosthetic valves were used for valve replacements. Standard surgical instruments were used in all of these operations. There was no need to use an extra surgical instrument. Cannulation was done through the thoracotomy incision. The cross clamp was placed through the middle thoracotomy incision. Temporary pacemaker wire was placed in all patients. Temporary pacemaker wire was placed in the heart before the cross clamp was lifted and the heart was working. At the end of the operation, a thoracic drain was placed in the thorax from the 7th ICA. The ribs were approximated with three absorbable sutures. Tissue layers were sutured in accordance with anatomical folds. A skin suture line of approximately 6-8 cm was formed (**Figure 3**). After the operation, the patients were taken to intensive care by changing the double lumen intubation tube with a single lumen tube.

SPSS for Windows version 15.0 pocket program (SPSS Inc., Chicago, IL, USA) was used for the statistical analysis. Arithmetic mean and standard deviation as measures of central tendency in numerical data with normal distribution; Median, minimum and maximum values were used in numerical data that did not show normal distribution. Categorical variables are shown as percentages.

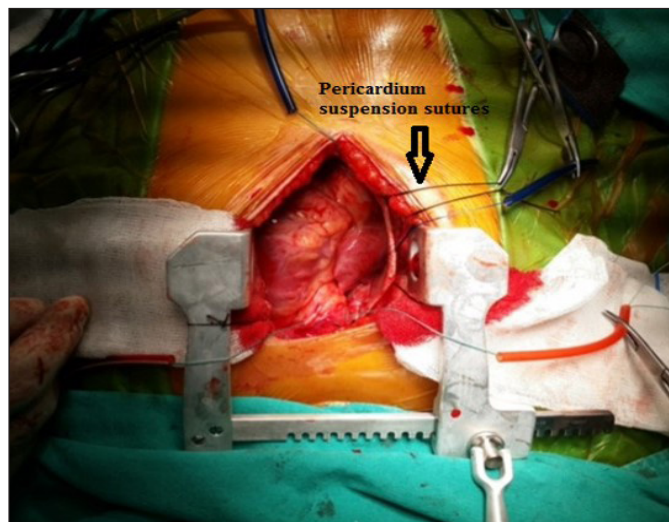


Figure 1. Right infra-axillary thoracotomy

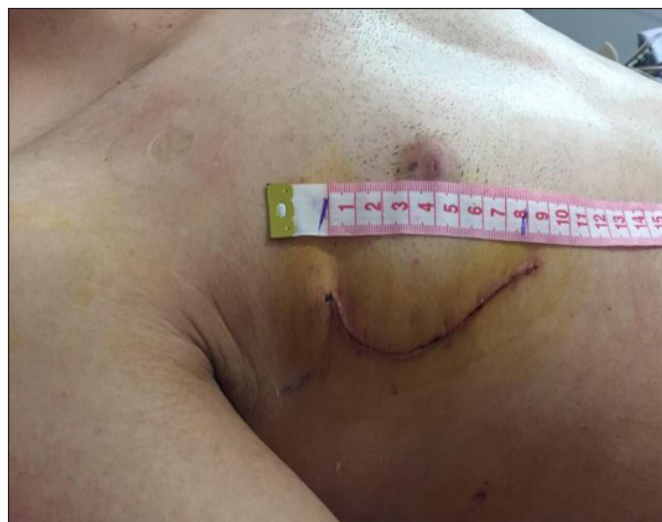

Figure 3. Thoracotomy skin incision

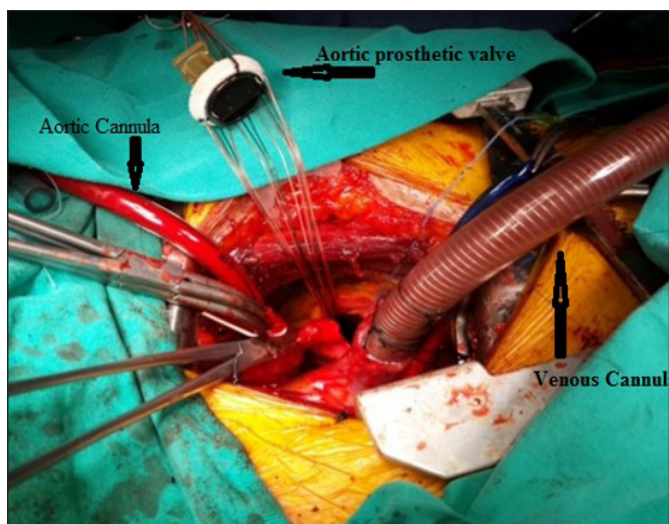


Figure 2. Cannulation and aortic valve replacement

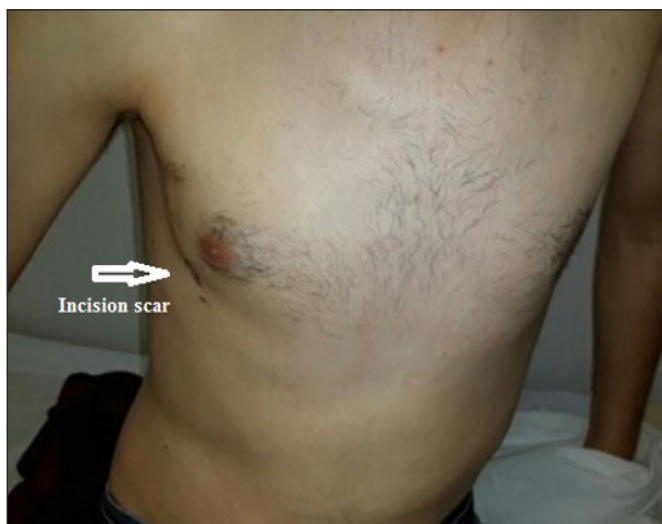

Figure 4. The cosmetic result of the postoperative incision

RESULTS

A total of 16 patients underwent cardiac surgery with a right infra-axillary mini thoracotomy. 9 of them were men and 7 of them were women. The average age was 47.5±11.2 years, the mean weight was 73.4±9.2 kg,

and the average body mass index was 25.3±3.2 kg/m². Diabetes mellitus, renal insufficiency and hypertension were not present in any of the patients. Demographic and comorbidity data are shown in **Table 1**.

Table 1. Preoperative and comorbidity data							
	MVR	AVR	AVR+MVR	AVR+TRA Reoperation	MVR Reoperation	ASD	MYXOMA
Age (mean)	54±11.4	45±8.5	61±12.1	65±14.3	75	22	31
Weight (mean)	63.16	87	77	75	80	67.5	71
Height (mean)	1.68	1.8	1.61	1.72	1,78	1.68	1.74
Male	3	1	1	1	1	1	1
Female	3	2	1	-	-	1	-
BMI (mean)	22.4	26.9	29.7	25.4	25.24	23.9	23.5
BSA (mean)	1.72	2.07	1.81	1.88	1,95	1.77	1.85
COPD	2	1	1	-	-	-	-
HT	-	-	-	-	-	-	-
DM	-	-	-	-	-	-	-
CRF	-	-	-	-	-	-	-

AVR: Aortic valve replacement, MVR: Mitral valve replacement, ASD: Atrial septal defect, TRA: Tricuspid annuloplasty, BMI: Body mass index, BSA: Body surface area, COPD: Chronic obstructive pulmonary disease, HT: Hypertension, DM: Diabetes mellitus, CRF: Chronic renal failure.

Mitral valve replacement, AVR, AVR and MVR, ASD repair, myxoma excision, reoperation AVR+TRA, reoperation MVR operations were performed on the patients. The data are shown in **Table 2**.

		n		
Valve diseases	MS	4		
	MF	2		
	AF	1		
	AS	2		
	AF+MF	1		
Reoperation	Paravalvular aortic valve leak+TF	1		
	Paravalvular mitral valve leak	1		
Other heart diseases	ASD	2		
	Miksoma	1		
Operations	Single valve surgery	MVR AVR	6 3	
	Double valve surgery	AVR+MVR	2	
	Others	ASD repair		2
		Myxoma excision		1
		Reoperation AVR+TRA		1
		Reoperation MVR		1

MS: Mitral stenosis, MF: Mitral failure, AS: Aortic stenosis, aortic gailure, TF: Tricuspid failure, AVR: Aortic valve replacement, MVR: Mitral valve replacement, ASD: Atrial septal defect.

The mean cannulation time was 50±9 minutes, the mean ECC time was 95±11 minutes, and the mean CC time was 61±9 minutes. The mean extubation time was 7±2.3 hours. Incision site infection did not develop in patients. The intensive care stay of the patients was 1±0.5 days and the hospital stay was 6±1.5 days. No mortality was observed in the 3-month follow-up of the patients. Operative and postoperative data are shown in **Table 3**.

	mean±std
Average cannulation time (min)	50±9
ECC time (min)	95±11
Cross clamp time (min)	61±90
Intensive care stay (day)	1±0.5
Hospital stay (day)	6±1.5
Average drainage (cc/day)	380±35
Blood transfusion (ES/unit)	1.57±1.13
Extubation time (hrs)	7±2.3
Postoperative incision infection	0
Postoperative atrial fibrillation	1
Low cardiac output syndrome	0
Exploration by bleeding	0
Stroke	0
Sepsis	0
Pulmonary complication	0
Postoperative pacemaker	0
Renal insufficiency	0
Hospital mortality	0

ECC: Extra corporeal circulation

DISCUSSION

The most important advantage of right infra-axillary mini thoracotomy is the minimum injury that occurs during surgery. In addition to the small incision made, reaching the thorax through the muscle tissue without cutting any muscle or bone tissue during thoracotomy causes the surgical injury to be minimal (8). Another advantage is that a very good cosmetic result is obtained with a short skin incision under the armpit. There is no visible incision like in the median sternotomy and anterolateral thoracotomy incision (**Figure 4**). Kaneda et al. (9) conducted a study with right infra-axillary thoracotomy on 20 patients. They stated that this technique could minimize skin incision and improve both cosmetic and functional results compared to the methods previously described. In addition, incisions in the foreskin tend to result in hypertrophic scarring, such as in the shoulder or groin areas. Anterior chest surgical incisions can be easily seen and attract attention. This may be a cause of social maladjustment in patients (10).

Heart surgeries with thoracotomy first started as simple ASD repair operations (11). Despite the advantages of minimally invasive cardiac surgery, its development in the world is slow. Only 5 to 10% of isolated valve operations in the USA and Europe have been performed using a minimally invasive approach (12). We have shown that procedures such as ASD, myxoma excision, reoperations, AVR, MVR or double valve interventions, as well as RF ablation for atrial fibrillation can be easily performed with this method.

Today, femoral artery-vein cannulation is frequently performed in open heart surgery performed with minimally invasive methods (13,14). In this method, cannulation is performed from a single incision without the need for femoral cannulation and the surgery can be carried out more practically. Thus, incision infection that may originate from the inguinal region and injuries to the artery (dissection in the femoral artery, thromboembolism in the artery or vein, aneurysm, bleeding, leg ischemia, incision infection) will be avoided (15). Although surgeons have prejudices about the approach to the aorta, an aortic exposure similar to the median sternotomy is obtained. The aorta can be safely intervened. Another advantage is that it does not require special surgical instruments during the procedure and there are no additional costs caused by these. It is an easy method to learn and practice compared to other minimally invasive methods such as thoracoscopic and robotic surgeries.

Although it seems like a disadvantage that the pre-cannulation preparation period takes longer than the standard sternotomy method during the learning period, this period is shortened with the practical application in the studies. Masuda et al. (16) performed 126 isolated

aortic valve surgeries using right infra-axillary mini thoracotomy. In this study, they stated that this learning process could occur with approximately 40 patients. We think this process will be completed in much less cases. In our study, the mean cannulation time was determined as 50 ± 9 minutes. Since an exposure similar to median sternotomy can be obtained, total ECD and CC times are not very different from each other (17). In the study, the mean duration of ECD was 95 ± 11 minutes, and the mean duration of CC was 61 ± 9 minutes.

Re-exploration due to bleeding and tamponade leads to morbidity such as increased blood transfusion, development of infection, prolonged ventilation, neurological problems and renal failure. Technological advances in cardiac surgery and the development of CPB techniques and equipment have reduced these rates. In recent studies, these rates have decreased to around 3% (18). In median sternotomy, bone incision and related increase in the amount of bleeding are found less in the postoperative infra-axillary method (19). While the mean amount of bleeding in cardiac surgery performed with sternotomy was 589 ± 136 cc/day in studies performed, they were found to be 351 ± 63 cc/day in cases performed with thoracotomy (20). In our study, the average postoperative drainage amount was found to be 380 ± 35 cc/day, and there were no patients undergoing revision due to bleeding and tamponade.

In cardiac surgery cases requiring CPB, coagulation factors and platelets are consumed depending on the size of the surgical area, overactivation of the hemostatic system, hemodilution, inflammation and the mechanical effects of the perfusion system. Therefore, it is inevitable that the need for transfusion will increase in the perioperative and postoperative period (21). Transfusions performed in cardiac surgery, where blood use is needed so much, also brings complications. The amount of bleeding brings along the negative effects of blood transfusion (22). Postoperative bleeding may be excessive as a result of the instability of the periosteum and bone in sternotomy. Infra-axillary thoracotomy is a less traumatic method that can be reached to the thorax and heart without cutting muscle and bone tissue. (23). Kalender et al. (24), in their study on 137 patients, showed that blood transfusion of 2 units or more in cardiac surgery negatively affected mortality and morbidity. In our study, it was found that an average of 1.57 ± 1.13 units of erythrocyte suspension was used. In heart surgeries performed with sternotomy, this rate is above 2 units on average (25).

Respiratory support with a prolonged ventilator may disrupt the stability of the sternum, as well as cause post-extubation pain and increased secretion, atelectasis and fever as a result of respiratory muscle fatigue. Long-term physiotherapy is required to prevent these complications

and to strengthen the respiratory muscles. As a result, the intensive care treatment process may be prolonged. Respiratory physiology changes and related complications due to thoracotomy, stay in the ventilator and intensive care periods are shorter (26). In this study, the mean duration of stay in the ventilator was 7 ± 2.3 hours, the duration of stay in the intensive care unit was 1 ± 0.5 days and the hospital stay was 6 ± 1.5 days. These results are consistent with the literature. One of the most feared complications in open heart surgery is sternum infection. Sternal detachment, superficial surgical site infection and deep surgical site infections were evaluated in patients who underwent standard sternotomy and were found to be 1%, 3.4%, and 2.5%, respectively (27). The risk of sternal dehiscence, sternal infection and mediastinitis is protected with right infra-axillary thoracotomy.

Studies have shown that the right infra-axillary thoracotomy incision is mostly made vertically (28,29). We performed the thoracotomy skin incision parabolically to reduce skin necrosis due to tension caused by the thorax retractor. This also gave us a larger exposure area. In addition, since it is an incision suitable for the anatomy of the breast tissue in women, it allows penetration into the thorax without touching the breast tissue. This provides an advantage in wound healing. While sternotomy surgery requires a lying position, sternal support brace and movement restriction in order to prevent sternal dehiscence during the healing process, infra-axillary thoracotomy does not require any movement restriction after 24 hours. This provides convenience in respiratory rehabilitation (coughing, secretion removal). As a result, it enables the patient to adapt more easily to daily life (30). In a meta-analysis performed MVR operation with right mini thoracotomy, the mortality rates were similar to those performed with MVR with median sternotomy (31). In the 3-month follow-up of the patients, echocardiography findings were normal and no mortality was observed.

Limitations: The first limitation of the study is that it is a single center. The second limitation is that it was done retrospectively. The third limitation is the small number of patients in the study group.

RESULT

We think that the right infra-axillary mini thoracotomy method can be used safely in many heart surgeries including multiple valve procedures. In addition to a good cosmetic result, we recommend the right infra-axillary mini thoracotomy method in suitable patients to reduce intensive care and hospital stays, protect from sternum infections, return to normal daily activities without the need for movement restriction, and a quality life physically and psychologically.

ETHICAL DECLARATIONS

Ethics Committee Approval: The study was carried out with the permission EMSEY Hospital of Research Ethics Committee (permission date: 10.08.2014, decision no: 4).

Informed Consent: Because the study was designed retrospectively, no written informed consent form was obtained from patients.

Referee Evaluation Process: Externally peer-reviewed.

Conflict of Interest Statement: The authors have no conflicts of interest to declare.

Financial Disclosure: The authors declared that this study has received no financial support.

Author Contributions: All of the authors declare that they have all participated in the design, execution, and analysis of the paper, and that they have approved the final version.

REFERENCES

- Schmitto JD, Mokashi SA, Cohn, LH. Minimally-invasive valve surgery. *J. Am. Coll. Cardiol* 2010; 56: 455–62.
- Navia JL, Cosgrove DM. Minimally Invasive Mitral Valve Operations. *Ann Thorac Surg* 1996; 62: 1542-4.
- Merk DR, Lehmann S, Holzhey DM, et al. Minimal invasive aortic valve replacement surgery is associated with improved survival: a propensity-matched comparison. *Eur J Cardiothorac Surg* 2015; 47: 11-7.
- Komai H, Naito Y, Fujiwara K, Noguchi Y. Cosmetic benefits of lower midline skin incision for pediatric open heartoperation. A review of 100 cases. *Jpn J Thorac Cardiovasc Surg* 2002; 50: 55– 8.
- Däbritz S, Sachweh J, Walter M, Messmer BJ. Closure of atrial septal defects via limited right anterolateral thoracotomy as a minimal invasive approach in female patients. *Eur J Cardiothorac Surg* 1999; 15: 18 –23.
- Yoshimura N, Yamaguchi M, Oshima Y, Oka S, Ootaki Y, Yoshida M. Repair of atrial septal defect through a right posterolateral thoracotomy: a cosmetic approach for female patients. *Ann Thorac Surg* 2001; 72: 2103–5.
- Wang D, Wang Q, Yang X, Wu Q, Li Q. Mitral valve replacement through a minimal right vertical infra-axillary thoracotomy versus standard median sternotomy. *Ann Thorac Surg* 2009; 87: 704-8.
- Lancaster LL, Mavroudis C, Rees AH, Slater AD, Ganzel BL, Gray LA Jr. Surgical approach to atrial septal defect in the female. Right thoracotomy versus sternotomy. *Am Surg* 1990; 56: 218-21.
- Kaneda T, Nishino T, Saga T, Nakamoto S, Ogawa T, Satsu T. Small right vertical infra-axillary incision for minimally invasive port-access cardiac surgery: a moving window method. *Interact Cardiovasc Thorac Surg* 2013; 16: 544-6.
- Lancaster LL, Mavroudis C, Rees AH. Surgical approach to atrial septal defect in female right thoracotomy versus sternotomy. *Am Surg* 1990; 56: 218-21.
- Kirklin JW, Barret-Boyes BG (editors). Atrial septal defect and partial anomalous pulmonary venous connection. In: *Cardiac Surgery*. First ed. New York: John Wiley & Sons; 1986: 463-97.
- Attia RQ, Hickey GL, Grant SW, et al. Minimally invasive versus conventional aortic valve replacement: a propensity-matched study from the UK National Data. *Innovations (Phila)* 2016; 11: 15–23.
- Schwartz DS, Ribakove GH, Grossi EA. Minimally invasive mitral valve replacement: Port-Access technique, feasibility, and myocardial functional preservation. *J Thorac Cardiovasc Surg* 1997; 113: 1022-31.
- Grinda JM, Folliguet TA, Dervanian P. Right anterolateral thoracotomy for repair of atrial septal defect. *Ann Thorac Surg* 1996; 62: 175-8.
- Bichell DP, Balaguer JM, Aranki SF. Axilloaxillary cardiopulmonary bypass: a practical alternative to femorofemoral bypass. *Ann Thorac Surg* 1997; 64: 702-5.
- Masuda T, Nakamura Y, Ito Y, et al. The learning curve of minimally invasive aortic valve replacement for aortic valve stenosis. *Gen Thorac Cardiovasc Surg* 2020; 68: 565-70.
- Özbayburtlu M, Gültekin Y, Gemalmaz H. The assessment of the cardioprotective effectiveness of levosimendan on patients with impaired left ventricle functions and less than 40% of ejection fraction who will receive coronary artery bypass graft operation. *J Health Sci Med* 2020; 3: 460-65.
- Holzhey DM, Seeburger J, Misfeld M, Borger MA, Mohr FW. Learning minimally invasive mitral valve surgery: a cumulative sum sequential probability analysis of 3895 operations from a single high-volume center. *Circulation* 2013; 128: 483–91.
- Despotis GJ, Avidan MS, Hougue CV. Mechanisms and attenuation of hemostatic activation during extracorporeal circulation. *Ann Thoracic Surg* 2001; 72: 1821-31.
- Tünerir B, Beşoğlu Y, Dernek S, Yavuz Y, Kural T, Aslan R. Mitral kapak replasmanında median sternotomiye alternatif bir yöntem: sağ minitorakotomi. *GKDC Derg* 1999; 7: 100-5.
- Steiner ME, Despotis GJ. Transfusion algorithms and how they apply to blood conservation: the high risk cardiac surgical patient. *Hematol Oncol Clin North Am* 2007; 21:177-84.
- Czer LS. Mediastinal bleeding after cardiac surgery: Etiologies, diagnostic considerations, and blood conservation methods. *J Cardiothorac Anesth* 1989; 3: 760-75.
- Braxton JH, Higgins RS, Schwann TA. Reoperative mitral valve surgery via right thoracotomy: decreased blood loss and improved hemodynamics *J Heart Valve Dis* 1996; 5: 169-73.
- Kalender M, Baysal AN, Dağlı M, Şahsivar MO, Gökmengil H. Koroner arter baypas cerrahisi sırasında yapılan kan transfüzyonun hastane mortalitesi üzerine etkisi. *Koşuyolu Heart J* 2019; 22: 1-6.
- Sood N, Coleman CI, Kluger J, White CM, Padala A, Baker WL. The Association Among Blood Transfusions, White Blood Cell Count, and the Frequency of Post-Cardiothoracic Surgery Atrial Fibrillation: A Nested Cohort Study From the Atrial Fibrillation Suppression Trials I, II, and III. *J Cardiothoracic Vascular Anesthesia* 2009; 12: 22-7.
- Murray KD, Pasque MK. Routine sternal closure using six overlapping Figure-of-8 wires. *Ann Thorac Surg* 1997; 64: 1852-4.
- Gültekin Y, Bolat A. Bir Üniversite hastanesi kliniğinde yapılan ilk 200 açık kalp ameliyatı sonuçları: Kırıkkale Üniversitesi, Tıp Fakültesi, Kalp-Damar Cerrahisi. *KÜ Tıp Fak Derg* 2020; 22: 348-56.
- Wang Q, Ye XJ, Ge M, Wang DJ. Early and long-term outcomes of cardiovascular surgery via minimal right vertical infra-axillary thoracotomy: a 15-year study of 1,126 patients. *Scientific Reports* 2018; 8: 4376-82.
- Xu C, Pan J, Zhou Q, et al. Right vertical infra-axillary thoracotomy for double valve replacement. *J Card Surg* 2015; 30: 427–30.
- Cohn LH. Minimally invasive aortic valve surgery: technical considerations and results with the parasternal approach. *J Card Surg* 1998; 13: 302-5.
- Sündermann SH, Sromicki J, Rodriguez Cetina Biefer H, et al. Mitral valve surgery: right lateral minithoracotomy or sternotomy? A systematic review and meta-analysis. *J Thorac Cardiovasc Surg* 2014; 148: 1989-95.