



# Removal of a Maxillary Third Molar Displaced in the Infratemporal Fossa using an Intraoral Approach

## İnfratemporal Locaya Deplase Olmuş Maksiller Üçüncü Molar Dişin İntraoral Yaklaşım İle Çıkartılması

Metin Berk Kasapoğlu<sup>1</sup>, Gözde Gökçe<sup>1</sup>, Ahmet Taylan Çebi<sup>2</sup>, Abdulkadir Burak Çankaya<sup>1</sup>

<sup>1</sup>Istanbul University, Faculty of Dentistry Oral and Maxillofacial Surgery, İstanbul, Turkey

<sup>2</sup>Karabük University, Faculty of Dentistry Oral and Maxillofacial Surgery, Karabük, Turkey

Copyright@Author(s) - Available online at [www.dergipark.org.tr/tr/pub/medr](http://www.dergipark.org.tr/tr/pub/medr)

Content of this journal is licensed under a Creative Commons Attribution-NonCommercial 4.0 International License.



### Abstract

Removal of an impacted maxillary third molar can be challenging for both dental clinicians and oral surgeons. Frequently encountered complications include infection, pain, swelling, root fractures, trismus, and haemorrhage. In addition, unexpected displacement of the maxillary third molar may be encountered during the extraction process. This case report presents a maxillary third molar displaced to the infratemporal fossa, as well as removal of the tooth following 1 month, along with the causative factors. The roles of orthopantomography and dental volumetric tomography scans in determining the localization of the tooth are discussed, together with different surgical options and risks for surgical removal of the tooth from the infratemporal fossa.

**Keywords:** Displacement, extraction, infratemporal fossa, third molar

### Öz

Gömülü maksiller üçüncü molar dişinin cerrahi olarak çıkarılması hem diş hekimleri hem de çene cerrahları için zor olabilmektedir. Sık karşılaşılan komplikasyonlar arasında enfeksiyon, ağrı, ödem, kök kırıkları, trismus ve kanama bulunur. Bu komplikasyonlara ek olarak, çekim sırasında maksiller üçüncü azı dişi anatomik boşluklara deplase olabilmektedir. Bu olgu sunumunda çekim esnasında infratemporal fossaya deplase olan bir maksiller üçüncü molar dişi ve 1 ay sonrasında intraoral yaklaşım ile bölgeden uzaklaştırılması nedensel faktörlerle birlikte bildirilmiştir. Dişin lokalizasyonunu belirlemede ortopantomografi ve dental volumetrik tomografinin rolü, farklı cerrahi seçenekler ve dişin infratemporal fossadan cerrahi olarak çıkarılması sırasında oluşabilecek riskler tartışılmaktadır.

**Anahtar Kelimeler :** Yer değiştirme, diş çekimi, infratemporal fossa, üçüncü molar

## INTRODUCTION

One of the most frequently performed operations in oral and maxillofacial surgery is removal of the upper third molar. However, the procedure is associated with complications, including maxillary tuberosity fracture, root fractures, prolapse of the buccal fat pad, and displacement of the tooth into the maxillary sinus, infratemporal fossa, lateral pharyngeal, or pterygomandibular spaces or other tissue cavities (1,2). Undesirable displacement of the

maxillary third molar to neighbouring tissue cavities is a rarely cited but frequently observed complication (1-3). This clinical report describes the location and delayed surgical removal of an impacted maxillary third molar that was accidentally displaced into the infratemporal fossa.

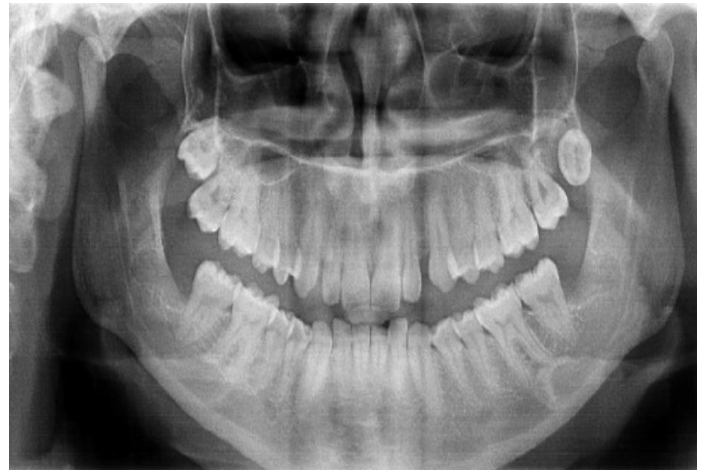## CASE REPORT

A 20-year-old woman was referred to the Istanbul University Faculty of Dentistry, Department of Oral and

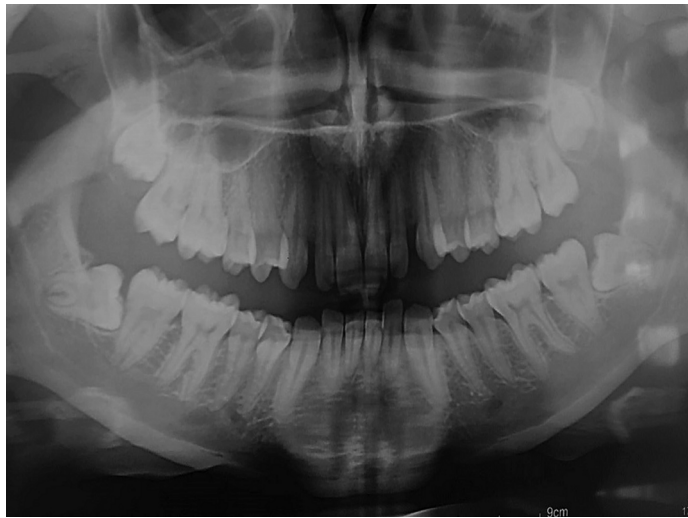**Geliş Tarihi / Received:** 22.01.2021 **Kabul Tarihi / Accepted:** 27.04.2021

**Sorumlu Yazar /Corresponding Author:** Metin Berk Kasapoğlu, İstanbul University, Faculty of Dentistry Oral and Maxillofacial Surgery, İstanbul, Turkey, E-mail: [mbkasapoglu@gmail.com](mailto:mbkasapoglu@gmail.com)

Maxillofacial Surgery, by a dental clinician who had unsuccessfully attempted to remove the left maxillary third molar under local anaesthesia on the preceding day (Figure 1). During intraoral examinations, the tooth could not be detected; thus, it was suspected to have been displaced upwardly through the infratemporal fossa (ITF) or buccal space. The patient had facial swelling on her left side, local pain during mandibular movements, and trismus. Mouth opening was limited to 1 cm. Visual activity and all other aspects of head and neck examinations were normal. Immediately, an orthopantomogram was taken, which showed that the left maxillary third molar had been displaced superiorly and posteriorly, possibly into the ITF (Figure 2).



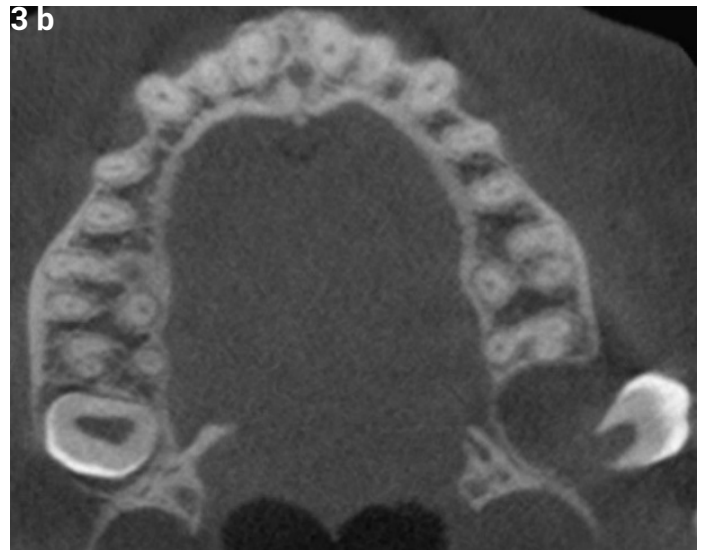
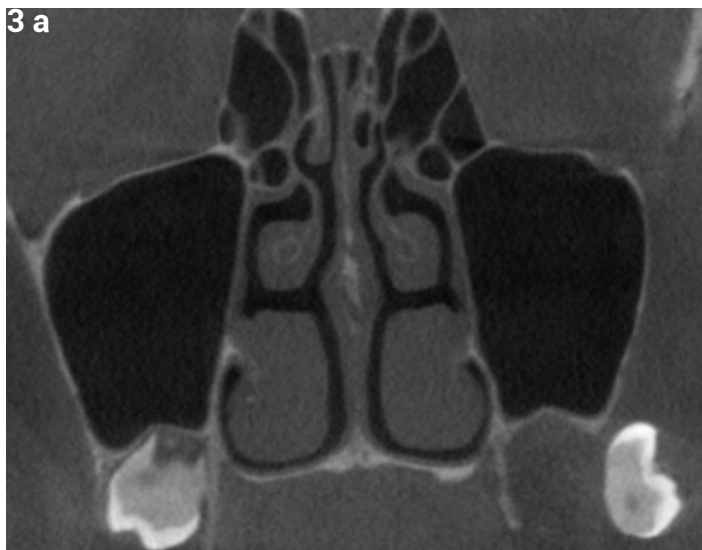
**Figure 2.** Orthopantomogram of the patient following the removal attempt of upper left 3rd molar



**Figure 1.** Orthopantomogram of the patient before extraction of upper left 3rd molar

The patient was administered 1 g amoxicillin and 1 g clavulanic acid (every 12 h), as well as a nonsteroidal anti-inflammatory drug (as needed) for 1 week to prevent infection. Seven days later, the patient showed improved mouth opening, however it remained insufficient for surgical intervention; pain remained on the left side of her face. She was instructed to return for consultation 3 weeks later. In addition, she was asked to return immediately if symptoms worsened.

Three weeks later, the patient showed no symptoms. To localize the exact location of the tooth, a dental volumetric tomography (DVT) scan was performed with 1 mm cross-sections. Axial and coronal cross-sections showed that the third molar had been displaced into the ITF (Figure 3 a and b).



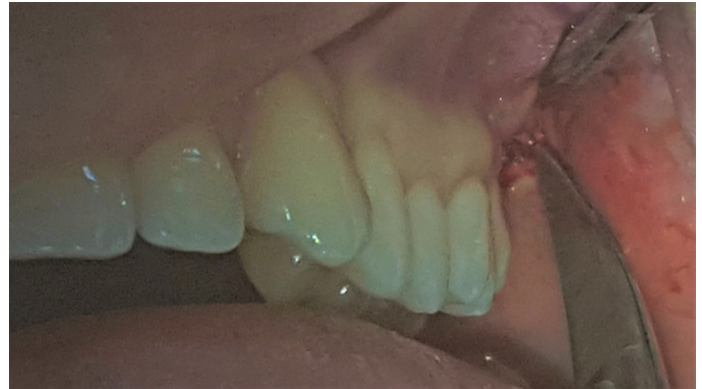**Figure 3 a.** Coronal DVT sections of the displaced tooth. **b.** Axial DVT sections of the displaced tooth

Under local anaesthesia, the needle of a 2 cc dental syringe was used to probe the tissue slightly through

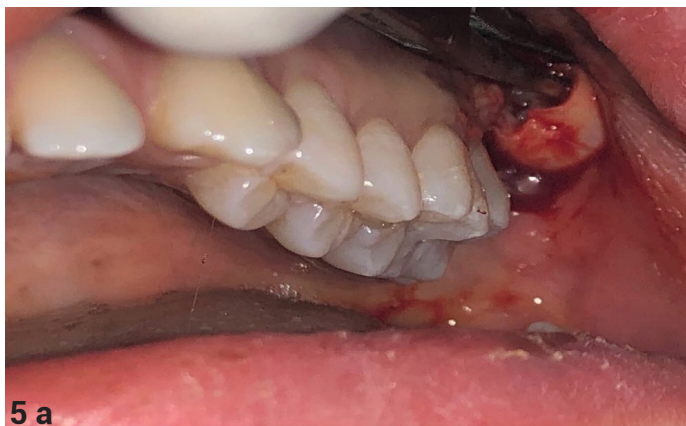the assumed tooth-bearing area to better determine its location and movement direction. When the needle

reached the approximate topographic position of the tooth and stabilization of the tooth in soft tissue had been confirmed, a small incision was made parallel to the fibres of the buccinator muscle. With the aid of a blunt surgical scissor, the muscle fibres were dissected and the enamel of the displaced third molar was observed (Figure 4). A haemostat was used to grip and pull the tooth from the anatomical cavity (Figure 5 a and b).

Deep layers of muscle fibres were irrigated with 0.5% saline solution. The incision was primarily closed with a 3-0 silk suture material and the patient received the same medical regimen that had been administered during the postoperative period. No postoperative complications occurred during follow-up period.

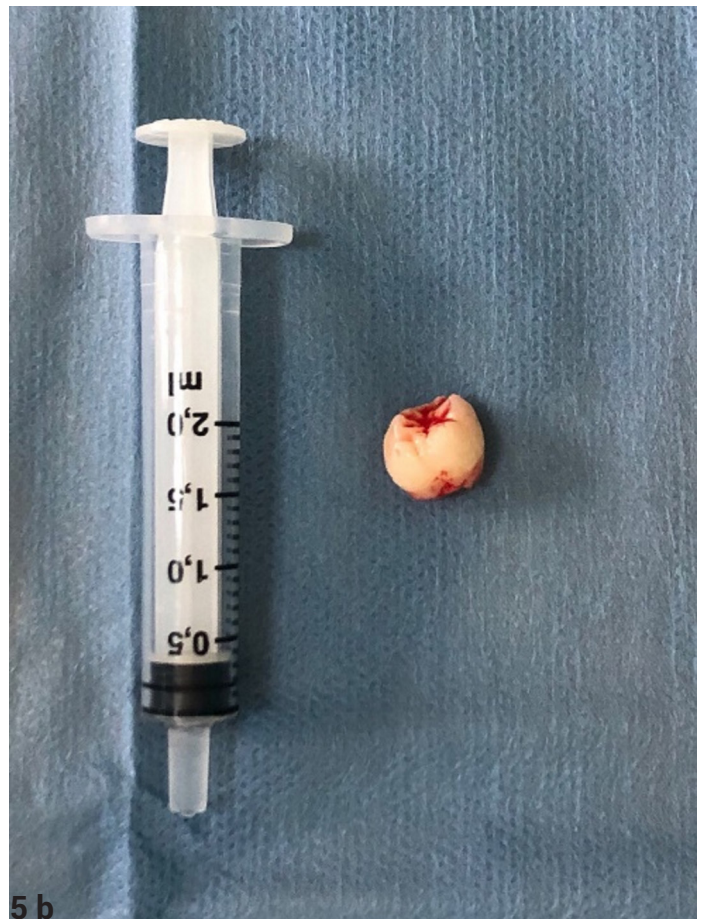

**Figure 4.** Dissection of the muscle fibers



5 a

**Figure 5 a.** Hameostat holding the displaced tooth **b.** Removal of upper 3rd molar from infratemporal fossa



5 b

## DISCUSSION

Lack of anatomical knowledge, poor radiographic examination, insufficient experience with regard to the basic principles of oral surgery techniques, and limited regional visibility may cause maxillary third molars to be displaced towards neighbouring anatomical cavities during their removal (1-5). The ITF is surrounded by the maxilla, styloid process, greater wing of the sphenoid bone, lateral pterygoid plate, and ramus. Moreover, it is occupied by pterygoid muscles, mandibular nerve branches, chorda tympani, maxillary artery, and pterygoid venous plexus (6). During the removal of a maxillary third

molar, elevator misuse or application of excessive force may cause displacement of the tooth to the ITF through the periosteum. Further removal attempts may displace the tooth into the skull base, which poses a risk of irreversible morbidity (7,8). Radiographic investigations are recommended soon after displacement to eliminate the risk of damaging other anatomic areas (e.g., the orbit) (9). In the present case, panoramic radiographs taken on the next day showed that the displaced tooth had not moved superiorly through the orbit or skull base.

A patient with a displaced tooth into the ITF might be asymptomatic or might have symptoms of infection,

such as trismus, facial swelling, and pain. Mandibular movements may be limited due to the presence of a fibrous capsule around the displaced tooth. In some cases, diplopia has been reported due to paresis of the superior rectus nerve (1,2,5,9). The patient in the present case had facial swelling and exhibited limited mouth opening upon arrival at our clinic; however, she did not have any other comorbidities, such as visual distortion or diplopia. Some researchers support attempts to initiate migration of the displaced tooth in anatomical cavities until the time of operation (1,6). This is particularly useful for patients with underdeveloped teeth that exhibit no root formation. However, some authors<sup>10</sup> have suggested that migration cannot be achieved due to the presence of fibrous tissue capsulation around the displaced tooth.

Selvi et al. advised a patient to chew gum on a regular basis, to stimulate migration of the tooth inferiorly through the oral cavity; they observed downwards movement of the displaced tooth (1). Another study revealed that radiographic images should be taken immediately before surgery, as the tooth can move into the ITF over time, as well as in accordance with jaw movements (6). The patient in the present case had a small amount of root formation and reported pain during mouth opening movements. Therefore, migration risk was considered low, and chewing gum was not advised because of pain during jaw movement.

Localization of the displaced tooth into the ITF is essential for an appropriate surgical approach; however, it is difficult because radiographic features of the tooth may overlap with other anatomical structures. For that reason, identification of the displaced tooth into the ITF requires radiographs to be taken on several planes (6,7). Based on the increasing technological capabilities and low radiation doses involved in image acquisition, DVT has become an important facet of diagnosis. Campbell et al. reported a new technique that enabled retrieval with an active navigation image guidance system (9). Light-emitting diode mask and computed tomography data are used to localize the displaced tooth. Our DVT scans in two different planes (axial and coronal) clearly identified the tooth within the ITF, positioned laterally to the lateral pterygoid plate.

Notably, some clinicians prefer to delay the operation for several weeks, such that the fibrous tissue capsule may immobilize the tooth. Without the formation of a fibrous capsule, the tooth may be further displaced into deeper anatomical locations during the operation. In the present case, we delayed the operation for 4 weeks to ensure the formation of fibrous capsule around the displaced tooth.

Many techniques have been suggested to reach a third molar that has been displaced into the ITF. These techniques include resection of the coronoid process, Gillies approach to access the displaced molar, trans-sinusoidal approach via Caldwell-Luc fenestration, hemicoronal incision, and use of an 18-gauge spinal

needle to exert pressure on the displaced tooth (4,6,11,12). In the present case, we used the needle of a 2 cc dental syringe to establish the location and movement of the tooth. When we confirmed that the tooth was not mobile within the soft tissue, we began the operation. A small incision through the buccal vestibule was performed intraorally, following blunt dissection. Then the tooth was reached through this pathway.

## CONCLUSION

Prevention of maxillary third molar displacement into anatomical cavities can be achieved using distal retractors after the flap has been raised. In the present case, removal of the tooth from the ITF was not particularly difficult through the intraoral incision, as the tooth was immobile due to the presence of the fibrous capsule. We recommend that patients be referred to an oral and maxillofacial surgeon if they experience maxillary third molar displacement into an anatomical cavity.

**Financial disclosures:** All authors report no financial interests or potential conflicts of interest.

**Conflict of Interest:** The authors declare that they have no competing interest.

**Informed Consent:** Informed consent was taken from the patient.

## REFERENCES

1. Selvi F, Cakarer S, Keskin C, et al. Delayed removal of a maxillary third molar accidentally displaced into the infratemporal fossa. *J Craniofac Surg*. 2011;22:1391–3.
2. Ozer N, Uçem F, Saruhanoğlu A, et al. Removal of a maxillary third molar displaced into pterygopalatine fossa via intraoral approach. *Case Rep Dent*. 2013;2013:392148.
3. Durmus E, Dolanmaz D, Kucukkolbsi H, Mutlu N. Accidental displacement of impacted maxillary and mandibular third molars. *Quintessence Int*. 2004;35:375–7.
4. Sverzut CE, Trivellato AE, Sverzut AT, de Matos FP, Kato RB. Removal of a maxillary third molar accidentally displaced into the infratemporal fossa via intraoral approach under local anesthesia: report of a case. *J Oral Maxillofac Surg*. 2009;67:1316–20.
5. Dimitrakopoulos I, Papadaki M. Displacement of a maxillary third molar into the infratemporal fossa: case report. *Quintessence Int*. 2007;38:607–10.
6. Snell SR, Schnittman E, Marnhout R, Snell SRF. *Clinical anatomy for medical students. The head and neck (5th Edn)*. Boston: Little, Brown, 1995.
7. Patel M, Down K. Accidental displacement of impacted maxillary third molars. *Br Dent J*. 1994;177:57–9.
8. Oberman M, Horowitz I, Ramon Y. Accidental displacement of impacted maxillary third molars. *Int J Oral Maxillofac Surg*. 1986;15:756–8.
9. Campbell A, Costello BJ. Retrieval of a displaced third molar using navigation and active image guidance. *J Oral Maxillofac Surg*. 2010;68:480–5.

10. Gulbrandsen SR, Jackson IT, Turlington EG. Recovery of a maxillary third molar from the infratemporal space via a hemicoronal approach. *J Oral Maxillofac Surg* 1987; 45:279–282.
11. Sencimen M, Gulses A, Secer S, et al. Delayed retrieval of a displaced maxillary third molar from infratemporal space via trans-sinusoidal approach: a case report and the review of the literature. *Oral Maxillofac Surg*. 2017;21:1–6.
12. Orr DL. A technique for recovery of a third molar from the infratemporal fossa: case report. *J Oral Maxillofac Surg*. 1999;57:1459–61.