

# Comparison of third generation long Gamma nail and femur intramedullary nail for the treatment of femoral subtrochanteric fractures

Şahin Çepni<sup>1</sup>, Enejd Veizi<sup>1</sup>, Ali Şahin<sup>1</sup>, Ahmet Fırat<sup>1</sup>, İzzet Özey Subaşı<sup>2</sup>, Yağmur Polat<sup>3</sup>

<sup>1</sup> Department of Orthopedics and Traumatology, Ankara City Hospital, Ankara, Turkey

<sup>2</sup> Department of Orthopedics and Traumatology, Erzincan University Hospital, Erzincan, Turkey

<sup>3</sup> Department of Biostatistics, Ankara Yıldırım Beyazıt University, Ankara, Turkey

## ORCID ID of the author(s)

ŞÇ: 0000-0001-6850-7439  
EV: 0000-0002-1289-4959  
AŞ: 0000-0002-2399-404X  
AF: 0000-0001-9182-7270  
İÖS: 0000-0002-8647-5853  
YP: 0000-0002-1953-2512

## Corresponding Author

Enejd Veizi  
Ankara City Hospital, Department of Orthopedics and Traumatology, Ankara, Turkey  
E-mail: dr.nad89@hotmail.com

## Ethics Committee Approval

Ankara City Hospital, Educational Board of Medical Specialization Committee – Date 26/03/2020 - Document no. 72300690 – 799  
All procedures in this study involving human participants were performed in accordance with the 1964 Helsinki Declaration and its later amendments.

## Conflict of Interest

No conflict of interest was declared by the authors.

## Financial Disclosure

The authors declared that this study has received no financial support.

## Published

2021 March 19

Copyright © 2021 The Author(s)

Published by JOSAM

This is an open access article distributed under the terms of the Creative Commons Attribution-NonCommercial-NoDerivatives License 4.0 (CC BY-NC-ND 4.0) where it is permissible to download, share, remix, transform, and buildup the work provided it is properly cited. The work cannot be used commercially without permission from the journal.



## Abstract

**Background/Aim:** Internal fixation is the current gold standard procedure in treatment of subtrochanteric femur fractures. One of the most common causes of morbidity after subtrochanteric femoral fracture treatment is mechanical complications, such as implant failure. The aim of this study is to share our experience and compare the radiological and functional results of two different fixation implants in patients with subtrochanteric fractures.

**Methods:** A cohort of 57 patients with a subtrochanteric fracture operated using a third generation Gamma nail (G3LN) or an antero-graduated intramedullary nail (AIMN) were prospectively followed up. Twenty-eight underwent fracture fixation with the Gamma nail while the other twenty-nine were operated using a conventional AIMN. All patients were followed up until union or, in case of a revision, healing and recovery. Their radiological findings were retrospectively analyzed, and the functional results were assessed using a Harris Hip Score.

**Results:** Data regarding demographic properties such as sex, trauma mechanism and smoking were similar for the subgroups ( $P < 0.05$  for each). Blood loss amount, surgery time, hospital stay and follow up time were also similar between the two groups ( $P > 0.05$  for each). Compared to the AIMN group, whose reduction was mostly acceptable (48.28%), the majority of G3LN patients (57.14%) had an anatomical reduction on early follow up. Most fractures, regardless of the implant used, needed an open reduction. Both implants showed similar union time and had similar final HHS scores. None of the complication rates reached statistical significance between the two groups ( $P > 0.05$  for each).

**Conclusion:** Both third-generation Gamma Nail implant and antero-graduated intramedullary nailing are viable means of fixation for subtrochanteric hip fractures. They lead to similar and few complications while providing a rigid and secure fixation. These findings lead us to believe that good reduction and adherence to the principles of internal fixation rather than implants used are the key to success in the treatment of subtrochanteric fractures.

**Keywords:** Subtrochanteric femur fracture, Gamma nail, Antero-graduated intramedullary nail

## Introduction

The subtrochanteric region has traditionally been defined as the femoral region 5 cm distal to the lesser trochanter and located between the lesser trochanter and the femoral isthmus [1]. Fractures of this region consist of approximately 5-20% of all proximal femoral fractures and show a bimodal age distribution [2]. High-speed trauma is usually the cause in young and healthy individuals while simple falls and minor trauma are responsible for these kind of fractures in the aging population [1].

Intraoperative reduction of these fractures has always been tricky given that the posteromedial compressing forces and the anterolateral tensile forces combined with a variety of strong muscle attachments tend to pull the fracture fragments apart and have been deemed by many scholars as risk factors for non-union, malunion, varus malreduction and implant failure [1]. Many extramedullary fixation tools like sliding hip screws [3], dynamic condylar screws [4] and locked compression plates [5] have been used to address subtrochanteric fractures. Compared to extramedullary fixation systems, intramedullary nails are less invasive, lead to less blood loss intraoperatively, have lower rates of infection and non-union and give the patient the possibility of a quicker recovery by allowing early postoperative weight bearing [1]. Intramedullary nails are also biomechanically preferable to extramedullary devices due to shorter lever arms for the counter torque of bending moments [6]. Despite these advantages, fracture reduction tends to be more difficult when using intramedullary devices [1].

The aim of this study is to compare the radiological and clinical results of two different intramedullary devices widely used in the fixation of subtrochanteric fractures.

## Materials and methods

Data regarding all consecutive patients visiting the Level 1 trauma center of Ankara Atatürk Education and Training Hospital between May 2014 and September 2018 with a subtrochanteric fracture were retrospectively gathered and analyzed for this study.

Exclusion criteria were pathological fractures, open fractures, being under 18 years of age, polytrauma, multiple fractures and having a preoperative American Society of Anesthesiologists (ASA) score higher than IV.

To be included in our study, patients had to be operated with either a third-generation Gamma Long Nail (G3LN) (Stryker Trauma GmbH, Schonkirchen, Germany) or an antegrade intramedullary nail implant (AIMN). While the Gamma Nail implant type was constant in one group, two different implants, acting on the same fixation principles were used for the antegrade intramedullary fixation (AFN, Synthes, Solothurn, Switzerland; Zimed Turkey)

The Gamma Nail system consists of a lag screw and a rod to overcome problems in sliding-screw fixations. Although it has shown superior efficacy in the fixation of intertrochanteric and subtrochanteric fractures, its clinical application has been associated with several complications, including breakage of the lag screw and fracture of the femora distal to the intramedullary device [7]. The AIMN is designed with a proximal lateral bend specifically to facilitate insertion through the greater trochanter.

This theoretically reduces the potential complications of varus malalignment. Two separate screws can be placed through the femoral neck and compared to the Gamma system they provide lower fracture site compression but greater rotational stability and greater load sharing [8]. Anti-rotation function of the long gamma nail is obtained by inserting a blocking bolt into the proximal canal of the nail [9]. We routinely used fully reamed AIMN implants while the G3LN implants only required reaming of the proximal intertrochanteric region to facilitate insertion.

All fractures were classified using the Seinsheimer classification which has been widely accepted as one of the most practical classification systems for this condition [10]. It consists of five types (I–V), based on the number of fractured bone pieces, location, and shape of the fracture line.

Data relative to the surgery duration time, blood loss, hospital stay, open or closed reduction and cerclage cable usage were also taken of note. Fracture union was defined as painless weightbearing associated with a radiological bridging callus formation on at least three cortices on two orthogonal projections [11] while nonunion was defined as lack of cortical bridging after 6 months on at least three cortices with persistent pain at the fracture site during weight bearing [12]. Malunion was defined as less than 50% contact between proximal and distal fragments.

### Surgical technique

The surgeries were performed by three experienced surgeons familiar with both implants. Patients were placed supine on a radiolucent surgical trauma table. Approximately 30 minutes before the skin incision, they were administered an intravenous prophylactic antibiotic dose of 2 grams of Cefazoline. Traction was applied depending on the fracture pattern and a closed reduction was attempted. If not possible, a minimal skin incision was performed at the fracture site and an anatomical, or sometimes acceptable, reduction was obtained with the usage of clamps and sometimes cerclage cables. Then another small incision was performed 5 cm cranial to the greater trochanter and the entry point was chosen by radiographic confirmation. The entry point in all patients was slightly medial to the tip of the greater trochanter to avoid a varus malreduction. A guiding wire was then placed into the intramedullary cavity. Then according to the surgeon's judgement, a Gamma 3 Long Nail (sizes between 260-480mm) or an AIMN was inserted and locked proximally and distally. Care was taken to insert the G3LN's lag screw and the AIMN's inferior screw close to the inferior border of the femoral neck on the anteroposterior (AP) view and centrally on the lateral view as described by Jiang et al [9]. Compression was applied depending on the fracture pattern. The tip-apex distance (TAD) of the G3LN's lag screw and the AIMN's inferior (and longer) screw had to be <25mm [13, 14] so that cut-out and Z-effect complications could be minimized. Neck-shaft angle was measured on the final AP view and was later used as a reference to assess for cut-out, Z effect and other varus related complications. After radiological confirmation, a drainage bag was placed and the wound was closed.

### Postoperative management

Assisted active and passive hip and knee range of motion was started the day after surgery and foot-touch weightbearing was allowed. Weightbearing amount was increased in the following weeks depending on patient compliance and reduction

quality. Throughout the follow up period strengthening exercises were shown and recommended to the patients. All patients were given a thromboembolism prophylaxis of enoxaparin for 6 weeks.

**Method of assessment**

Patients were followed up monthly and evaluated clinically on each visit for pain, stiffness, infection, and deep venous thrombosis (DVT) signs and weightbearing amount. Radiologically they were assessed for healing signs, reduction loss, implant breakage and additional fractures. Reduction quality was noted and analyzed on the radiographs taken on early follow up (1-2 months) using Baumgartner et al.'s classification of good, acceptable and poor [13]. TAD was measured according to Li et al [14]. Two independent radiologists unfamiliar with the patients evaluated all the radiological data for this study.

All patients were monthly followed until complete union was achieved. They were then scheduled for yearly check-up visits. Those who experienced complications were treated accordingly and followed up until remission with yearly visits thereafter. All complications were noted and compared between the two groups. All revisions were managed at our center by the primary operating surgeons and their teams.

Patients were evaluated for hip pain and lower limb shortening and were analyzed at every visit with a Harris Hip Score (HHS). The data compared here consists of the HHS of their last visit at the clinic.

All patients gave their informed consent for this study and the local ethical committee approved the study design (Ankara City Hospital, Educational Board of Medical Specialization Committee – Date 26/03/2020 - Document nr. 72300690 – 799).

**Statistical analysis**

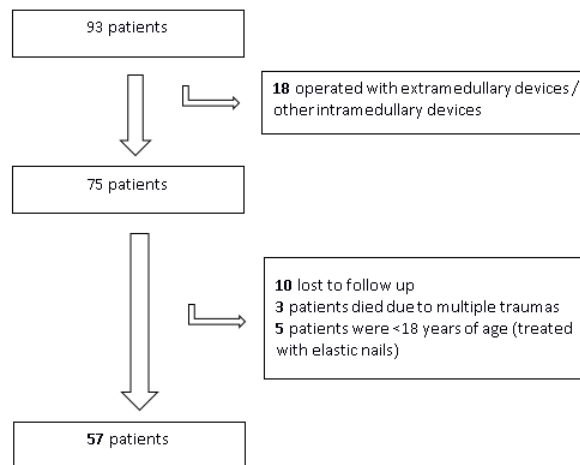
Statistical significance level was determined as  $P < 0.05$ . Statistical analyses were performed using Statistical Package for Social Sciences - IBM Statistics 25.0 (IBM Corp. Released 2017. IBM SPSS Statistics for Windows, Version 25.0. Armonk, NY: IBM Corp) and Microsoft Excel 2016. The relevance of the distribution of continuous variables such as age, blood loss, surgery time, hospital stay was evaluated using the Shapiro-Wilk test and graphical methods. Variables matching normal distribution were mean (standard deviation) and non-matching variables are summarized by median (min; max). Number and percentage [n (%)] statistics were used to summarize categorical variables such as gender, ASA, side, trauma. Mann Whitney U test was used for non-normal continuous variables and independent samples t test was used for normal continuous variables to compare inter-group differences. Chi-square test was used to compare categorical variables and Likelihood ratio, Fisher exact test, Continuity correction, Pearson Chi-square test results were reported as appropriate.

**Results**

Ninety-three patients with a subtrochanteric fracture were operated at our center, out of which eighteen were operated with an either extramedullary device or an intramedullary device not compatible with our study. Ten were lost to follow up and three patients had died shortly after surgery at the ICU due to the severity of the sustained multiple traumas. Five other patients were excluded for not meeting the inclusion criteria. Fifty-seven patients treated with intramedullary devices were included in this

study (Figure 1). Twenty-eight were operated with a G3LN while twenty-nine were operated with an AIMN.

Figure 1: Patient selection according to the inclusion and exclusion criteria for the current study.



Patients' mean age was 51.54 (19.74) years in G3LN, and 51.24 (19.13) years in the AIMN group, which were similar ( $P=0.955$ ). A slight majority of patients operated with G3LN were male (60.71%) while 55.17% of patients operated with an AIMN were female. Both implants were mostly used of the right side since most the fractures occurred on this side. No significant differences on demographic properties such as sex, trauma mechanism and smoking were observed ( $P > 0.05$ ). We found statistical significance in between subgroups regarding ASA and the Seinsheimer classification ( $P < 0.05$ ). All demographic data are shown on Table 1.

Table 1: Patients' demographic findings

Demographics	G3LN [n=28] Mean (SD) n (%)	AIMN [n=29] Mean (SD) n (%)	Test $\chi^2$	Statistics P-value
Age	51.54 (19.74)	51.24 (19.13)	t=0.057	0.955
Sex			-	0.175 <sup>†</sup>
Female	11 (39.29)	16 (55.17)		
Male	17 (60.71)	13 (44.83)		
Side				
Right	22 (78.57)	22 (75.86)		
Left	6 (21.43)	7 (24.14)		
Trauma				
FFH	6 (21.43)	9 (31.03)	0.273	0.601 <sup>#</sup>
HST	10 (35.71)	9 (31.03)	0.009	0.925 <sup>#</sup>
FI	2 (7.14)	2 (6.90)	-	0.681 <sup>†</sup>
FSL	10 (35.71)	9 (31.03)	0.009	0.925 <sup>#</sup>
ASA				
1	1 (3.57)	3 (10.34)	-	0.319 <sup>†</sup>
2	7 (25.00)	16 (55.17)	4.2018	0.040 <sup>#</sup>
3	20 (71.43)	10 (34.48)	6.388	0.011 <sup>#</sup>
Seinsheimer				
2	12 (42.86)	4 (13.79)	4.607	0.032 <sup>#</sup>
3	7 (25.00)	13 (44.83)	1.665	0.197 <sup>#</sup>
4	3 (10.71)	11 (37.93)	4.321	0.038 <sup>#</sup>
5	6 (21.43)	1 (3.45)	-	0.046 <sup>†</sup>
Smoking				
No	17 (60.71)	16 (55.17)	0.024	0.877 <sup>#</sup>
Yes	11 (39.29)	13 (44.83)		

†: Fisher, #: Continuity Correction Chi-Square test results. G3LN: Third generation Gamma long nail, AIMN: antegrade intramedullary nail, ASA: American Society of Anesthesiologists score, HST: High Speed Trauma, FFH: Fall from Height, FSL: Fall on Same Level, FI: Firearm Injury.

Blood loss amount, surgery time, hospital stay and follow up time were also similar between the two groups ( $P > 0.05$ ). The majority of G3LN patients (57.14%) had an anatomical reduction on early follow up and this reached statistical significance compared to the AIMN group whose reduction was mostly acceptable (48.28%). Most fractures, regardless of the implant used, needed an open reduction. Two cerclage cables were mostly used during fixation and very few fractures needed none (10 in total). All other surgery results are shown in Table 2.

Table 2: Surgery results of the patients

Surgery variables	G3LN [n=28]	AIMN [n=29]	Test t, Z	Statistics P-value
	Mean (SD) Median (min - max)	Mean (SD) Median (min - max)		
Blood Loss [cc]	396.79 (161.87)	413.10 (118.93)	0.435	0.665
Surgery Time [min]	85.00 (40 - 185)	85.00 (55 - 110)	0.008	0.944
Hospital Stay [day]	3.00 (2 - 6)	3.00 (2 - 10)	0.842	0.400
Follow-up Time [months]	33.50 (14 - 65)	41.00 (14 - 64)	0.743	0.458
	n (%)	n (%)	$\chi^2$	P-value
Reduction				
Anatomical	16 (57.14)	8 (27.59)	3.965	0.046 <sup>#</sup>
Acceptable	9 (32.14)	14 (48.28)	0.943	0.331 <sup>#</sup>
Poor	3 (10.71)	7 (24.14)	-	0.163 <sup>+</sup>
Open/Close			0.542	0.462 <sup>#</sup>
Close	7 (25.00)	4 (13.79)		
Open	21 (75.00)	25 (86.21)		
Cerclage				
0	6 (21.43)	4 (13.79)	-	0.342 <sup>+</sup>
1	9 (32.14)	2 (6.90)	4.322	0.038 <sup>#</sup>
2	10 (35.71)	18 (62.07)	2.975	0.085 <sup>#</sup>
3	3 (10.71)	5 (17.24)	-	0.373 <sup>+</sup>

+: Fisher, #: Continuity Correction Chi-Square test results.

Table 3 shows the complications and the revision data regarding both surgical implants. Both implants showed similar union time and had similar final HHSs. No shaft fractures, infections, malunions and pulmonary thromboembolisms (PTE) were detected, and no surgery-related deaths occurred. Four patients receiving a G3LN were revised in total while five were revised in the AIMN group. None of the complication rates reached statistical significance between the two groups. All data is shown in Table 3.

Table 3: Complications

Complications	G3LN [n=28]	AIMN [n=29]	Test Statistics P-value
	Median (min - max)	Median (min - max)	
Time to union [weeks]	20.00 (16 - 51)	25.00 (16 - 48)	0.240
NSA decrease [degree]	3.00 (0 - 10)	4.00 (0 - 12)	0.081
HHS Score	85.65 (51.5 - 96.2)	88.40 (66 - 96)	0.487
	n (%)	n (%)	p
Cut Out	1 (3.57)	3 (10.34)	0.319
Shaft Fracture	0 (0.00)	0 (0.00)	N/A
Non-union	2 (7.14)	1 (3.45)	0.487
Infection	0 (0.00)	0 (0.00)	N/A
Malunion	0 (0.00)	0 (0.00)	N/A
AVN	1 (3.57)	1 (3.45)	0.746
Hip Pain	3 (10.71)	3 (10.34)	0.648
HO	1 (3.57)	1 (3.45)	0.746
DVT	1 (3.57)	1 (3.45)	0.746
PTE	0 (0.00)	0 (0.00)	N/A
LLS>1.5 cm [SIAS-MM]	2 (7.14)	1 (3.45)	0.487
Reoperation	4 (14.29)	5 (17.24)	0.523
Death	0 (0.00)	0 (0.00)	N/A
Revised into			
THA	2 (50.00)	4 (80.00)	0.405
IMN	0 (0.00)	1 (20.00)	0.556
DCS	2 (50.00)	0 (0.00)	0.167

\* Fisher Exact Chi-Square test results. NSA: Neck shaft angle. HHS: Harris Hip Score. AVVN: Avascular necrosis. HO: Heterotopic ossification. DVT: Deep vein thrombosis. PTE: Pulmonary thromboembolism. LLS: Lower Limb Shortening. SIAS: Superior anterior iliac spine. MM: Medial malleolus. THA: Total hip arthroplasty. IMN: Intramedullary nail. DCS: Dynamic compression screw.

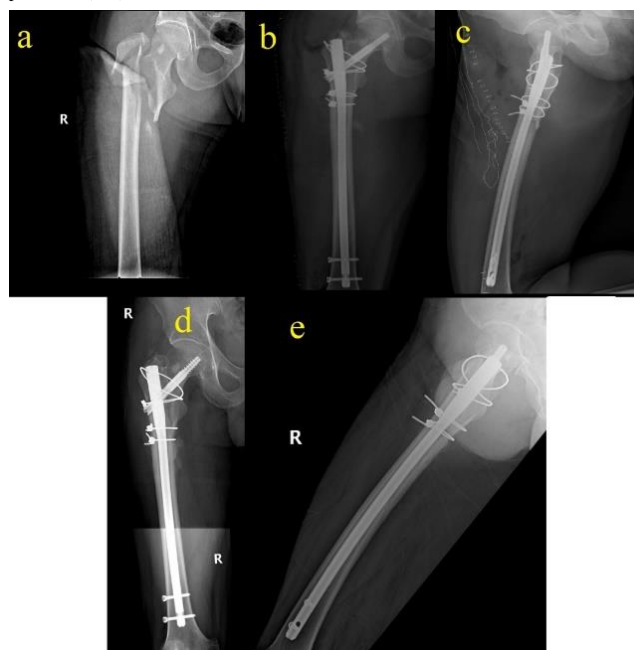
## Discussion

This study compared the results of two biomechanically strong intramedullary devices used in the treatment of subtrochanteric fractures and shared our experience with the studied devices. It showed that both the AIMN (Figure 2) and the Gamma 3 Long Nail (Figure 3) lead to acceptable healing rates with satisfactory clinical results.

Figure 2: A 35-year-old patient with a Seinsheimer type 2 subtrochanteric femur fracture on her arrival after a high-speed trauma (a). The fracture was reduced and an AIMN implant was chosen to stabilize the fracture and no cerclage cables were required. Her early follow up radiographs (3<sup>rd</sup> month postop) already show healing signs (b, c). The fracture site is completely healed at 9 months and the patient has returned to her daily activities (d, e).

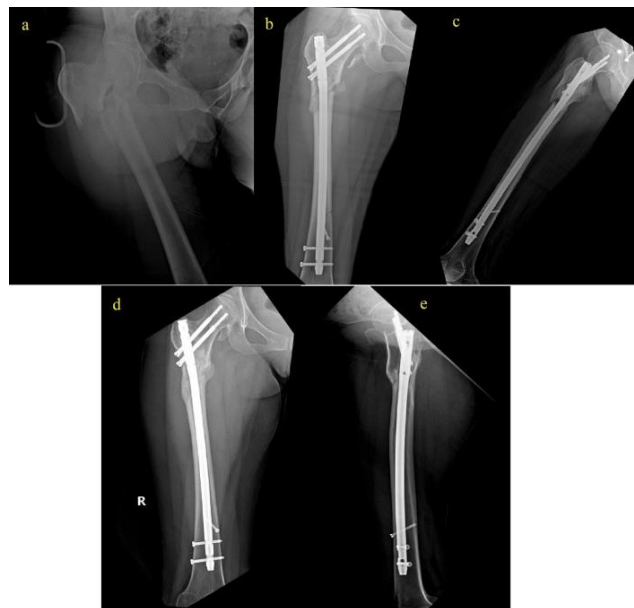

Figure 3: A 44-year-old male patient fell from a tree and presented to the emergency department with a Seinsheimer type 5 subtrochanteric femur fracture (a). His fracture was anatomically reduced using 3 cerclage cables and a Gamma Long nail was chosen as a fixation tool (b, c). At 7 months the patient is fully active and the fracture has healed without complications (d, e).



Subtrochanteric fractures fixation has always been a challenging procedure even for experienced surgeons. The massive forces acting on the fracture tend to pull the proximal fragments in flexion, abduction and external rotation making it difficult to align them anatomically without an open reduction [1]. Moreover, the discontinuity of the posteromedial wall of the proximal femur, a quite common feature of subtrochanteric fractures, leads to a varus malalignment if not addressed properly during surgery [15]. These studies suggest prior reduction with or without cerclage cables/wires before nail insertion. We followed the same procedure in this study.

Intramedullary implants have become the treatment of choice and almost a gold standard for these challenging fractures [1]. Extramedullary devices need extensive tissue/fracture site exposure, can lead to higher blood loss and higher tissue injury [16], have higher re-operation rates [17] and are biomechanically

inferior due to their longer lever arm [6]. Our center routinely uses intramedullary fixation in the treatment of these kind of fractures, which this study reflects. Despite this, a dynamic compression screw (DCS) system has been described as a successful means to address non-unions in subtrochanteric fractures by Lotzien et al [18]. Two patients from this study were firstly operated with a G3LN and developed a nonunion. Revision was performed using a DCS implant and both healed uneventfully, showing that despite their disadvantages, extramedullary devices can achieve satisfactory results when used properly.

Extensive studies have shown the G3LN implant to be an excellent choice in the treatment of subtrochanteric fractures [1]. Few studies have been performed on the usage of AIMN implants on subtrochanteric fractures maybe due to their limited ability to compress the fracture sites [1], their higher affinity for the Z and reverse Z effect [9] and concern that full reaming could lead to greater blood loss and longer operating time [19]. In our study we found the cut-out rate of the dual screw implant to be of 10.34% which is comparable to what previous studies have found [9]. They were all revised into a total hip replacement. No statistical significance was reached on either of the mentioned complications showing that with proper reduction AIMN implants can achieve acceptable results.

Cerclage cable/wire usage has often been attributed to delayed union or non-union due to concerns that it might disrupt blood supply to an already delicate region [20]. This theory had little histological basis [21] and has always been controversial. In his study of 52 subtrochanteric fractures, Kilinc et al. [16], like many others in the literature [1, 2], achieved good reduction and satisfying results with the usage of cerclage wire with no negative effect on fracture healing.

Cut-out and hip pain were our most frequent complications in our study. One elderly patient treated with a G3LN and three patients (1 elderly, 2 relatively young) operated with AIMN failed through a cut-out. Both elderly patients failed to comply with weightbearing recommendations. One of the AIMN patients experienced a loss in reduction during follow up leading to a subsequent Z-effect while the other patient had a fall on the same hip. The Z and the reverse Z effects are among the most frequent and most stressed complications for AIMN mentioned in the literature and varies from 7.1 to 13% [8]. Cut out for proximal hip nail on the other hand varies from 0 – 16% [22]. The results of our study were similar to those reported in the literature with a 3.55% cut out on the G3LN and 10.34% on the AIMN.

Two patients developed avascular necrosis (AVN) associated with hip pain and were treated before advancing to a cut out. One of the patients had a history of rheumatoid arthritis while the other developed Bell's palsy shortly after surgery. They both used corticosteroids, which we believe contributed to the development of the AVN. Each of them had been treated with a different implant and we believe the complication was not implant related but rather, the result of an increase in intracapsular pressure due to trauma. Decompression has shown some promising results in these patients [23]. They were both treated with a hip replacement.

Harris Hip Score (HHS) was used for the examination of functional results [24]. Patients treated with both implants showed

good results during follow up with many of them returning to preoperative activities. Only two patients operated with a G3LN implant developed a lower limb shortening of more than 1.5 cm. They were both treated with dynamic insoles and were recommended for physical rehabilitation. Heterotopic ossification (HO) is another complication mentioned in the literature [7]. While Hayashi et al [25] mention gender, surgical approach, ethnicity and fracture site as risk factors associated with HO, they found that severe HO was associated with longer time between time of acute hip fracture and surgery. In our study, two patients, one from each group, developed mild HO during follow up. They were both treated with nonsteroidal anti-inflammatory drugs and physical therapy.

### Limitations

Despite its overall positive results, our study has several limitations. This was a retrospective study, and analysis is prone to bias. We tried to tackle this bias by having the data gathered prospectively during the years. Second, observer errors may be present, especially in the radiological measurements. We tried to limit this by having two independent radiologists evaluate the findings. Third, a higher number of patients would have increased the strength of the statistical analysis. Out of the initial ninety-three patients, only fifty-seven were eligible for the study and the results should be interpreted accordingly. On the other hand, our study had a homogeneous patient population regarding age, gender and trauma mechanism and the results shown here could be generalized to the overall population.

### Conclusion

Both third-generation Gamma Nail implant and antegrade intramedullary nailing are viable means of fixation for subtrochanteric hip fractures. They lead to similar and few complications while providing a rigid and secure fixation. These findings lead us to believe that good reduction and adherence to the principles of internal fixation rather than implants used are the key to success in the treatment of subtrochanteric fractures.

### References

- Joglekar SB, Lindvall EM, Martirosian A. Contemporary management of subtrochanteric fractures. *Orthop Clin North Am.* 2015;46:21-35.
- Codesido P, Mejía A, Riego J, Ojeda-Thies C. Subtrochanteric fractures in elderly people treated with intramedullary fixation: quality of life and complications following open reduction and cerclage wiring versus closed reduction. *Arch Orthop Trauma Surg.* 2017;137:1077-85.
- Matre K, Havelin LI, Gjertsen J-E, Vinje T, Espehaug B, Fevang JM. Sliding hip screw versus IM nail in reverse oblique trochanteric and subtrochanteric fractures. A study of 2716 patients in the Norwegian Hip Fracture Register. *Injury.* 2013;44:735-42.
- Celebi L, Can M, Muratli H, Yagmurlu M, Yuksel H, Bicimoğlu A. Indirect reduction and biological internal fixation of comminuted subtrochanteric fractures of the femur. *Injury.* 2006;37:740-50.
- Saini P, Kumar R, Shekhawat V, Joshi N, Bansal M. Biological fixation of comminuted subtrochanteric fractures with proximal femur locking compression plate. *Injury.* 2013;44:226-31.
- Panteli M, Mauffrey C, Giannoudis PV. Subtrochanteric fractures: Issues and challenges. *Injury.* 2017;48:2023-6.
- Hesse B, Gächter A. Complications following the treatment of trochanteric fractures with the gamma nail. *Arch Orthop Trauma Surg.* 2004;124:692-8.
- Henschel J, Eberle S, Augat P. Load distribution between cephalic screws in a dual lag screw trochanteric nail. *J Orthop Surg Res.* 2016;11:41.
- Jiang L-S, Shen L, Dai L-Y. Intramedullary fixation of subtrochanteric fractures with long proximal femoral nail or long gamma nail: technical notes and preliminary results. *Ann Acad Med Singap.* 2007;36:821.
- Seinsheimer F. Subtrochanteric fractures of the femur. *J Bone Joint Surg Am.* 1978;60:300-6.
- Corrales LA, Morshed S, Bhandari M, Mclau III T. Variability in the assessment of fracture-healing in orthopaedic trauma studies. *J Bone Joint Surg Am.* 2008;90:1862.
- Yang JS, Otero J, McAndrew CM, Ricci WM, Gardner MJ. Can tibial nonunion be predicted at 3 months after intramedullary nailing? *J Orthop Trauma.* 2013;27:599.
- Baumgaertner MR, Curtin SL, Lindskog DM, Keggi JM. The value of the tip-apex distance in predicting failure of fixation of peritrochanteric fractures of the hip. *J Bone Joint Surg Am.* 1995;77:1058-64. Epub 1995/07/01. doi: 10.2106/00004623-199507000-00012. PubMed PMID: 7608228.
- Li S, Chang S-M, Jin Y-M, Zhang Y-Q, Niu W-X, Du S-C, et al. A mathematical simulation of the tip-apex distance and the calcar-referenced tip-apex distance for intertrochanteric fractures reduced with lag screws. *Injury.* 2016;47:1302-8.
- Velasco RU, Comfort TH. Analysis of treatment problems in subtrochanteric fractures of the femur. *J Trauma.* 1978;18:513-23.

16. Kilinc BE, Oc Y, Kara A, Erturer RE. The effect of the cerclage wire in the treatment of subtrochanteric femur fracture with the long proximal femoral nail: A review of 52 cases. *Int J Surg.* 2018;56:250-5.
17. Parker MJ, Handoll HH. Gamma and other cephalocondylic intramedullary nails versus extramedullary implants for extracapsular hip fractures in adults. *Cochrane Database Syst Rev.* 2010.
18. Lotzien S, Rausch V, Schildhauer TA, Gessmann J. Revision of subtrochanteric femoral nonunions after intramedullary nailing with dynamic condylar screw. *BMC Musculoskelet Disord.* 2018;19:448.
19. Kuzyk PR, Bhandari M, McKee MD, Russell TA, Schemitsch EH. Intramedullary versus extramedullary fixation for subtrochanteric femur fractures. *J Orthop Trauma.* 2009;23:465-70.
20. Perren S, Fernandez Dell'oca A, Regazzoni P. Fracture fixation using cerclage: research applied to surgery. *Acta Chir Orthop Traumatol Cech.* 2015;82:389-97.
21. Gadegone WM, Shivashankar B, Lokhande V, Salphale Y. Augmentation of proximal femoral nail in unstable trochanteric fractures. *Sicot-j.* 2017;3.
22. Utrilla AL, Reig JS, Muñoz FM, Tufanisco CB. Trochanteric gamma nail and compression hip screw for trochanteric fractures: a randomized, prospective, comparative study in 210 elderly patients with a new design of the gamma nail. *J Orthop Trauma.* 2005;19:229-33.
23. Massoud EIE. Fixation of intracapsular femoral neck fractures: Effect of trans-osseous capsular decompression. *Dicle Medical Journal/Dicle Tip Dergisi.* 2010;37.
24. Frihagen F, Grotle M, Madsen JE, Wyller TB, Mowinckel P, Nordsletten L. Outcome after femoral neck fractures: a comparison of Harris Hip Score, Eq-5d and Barthel Index. *Injury.* 2008;39:1147-56.
25. Hayashi D, Gould ES, Ho C, Caruana DL, Komatsu DE, Yang J, et al. Severity of heterotopic ossification in patients following surgery for hip fracture: a retrospective observational study. *BMC Musculoskelet Disord.* 2019;20:348.

This paper has been checked for language accuracy by JOSAM editors.

The National Library of Medicine (NLM) citation style guide has been used in this paper.