

## Cardiac Amyloidosis in a Patient Presenting with Symptoms of Heart Failure

Sefa Erdi ÖMÜR<sup>1</sup>, Çağrı ZORLU<sup>1</sup>

<sup>1</sup> Tokat State Hospital, Department of Cardiology, Tokat, Turkey

### Abstract

Cardiac amyloidosis (CA); it can be referred to as a progressive cardiomyopathy that occurs as a result of the accumulation of endogenous proteins in the form of amyloid fibrils, whose folding is disrupted in the kidney, liver, gastrointestinal system, soft tissue and heart. The course of the disease depends on the involvement of the organs and treatment options depending on the source of the protein. Immunoglobulin light chain (AL) amyloidosis and transthyretin (TTR) amyloidosis are the most common CA types. While AL amyloidosis is more common in the heart and kidney, TTR amyloidosis is more common in the heart. Although CA is not considered a common disease, TTR amyloidosis is observed in approximately 15% of patients with heart failure with preserved ejection fraction and severe aortic stenosis. CA diagnosis: it can be placed by echocardiography, magnetic resonance or nuclear scintigraphy methods. At the same time, genetic analysis, biopsy and histopathological tests are also useful for early diagnosis. After the diagnosis, antiplasma treatment or stopping the produced protein constitute the main lines of the treatment.

*Turk J Int Med* 2021;3(Supplement 1):S127-S130

DOI: [10.46310/tjim.873267](https://doi.org/10.46310/tjim.873267)

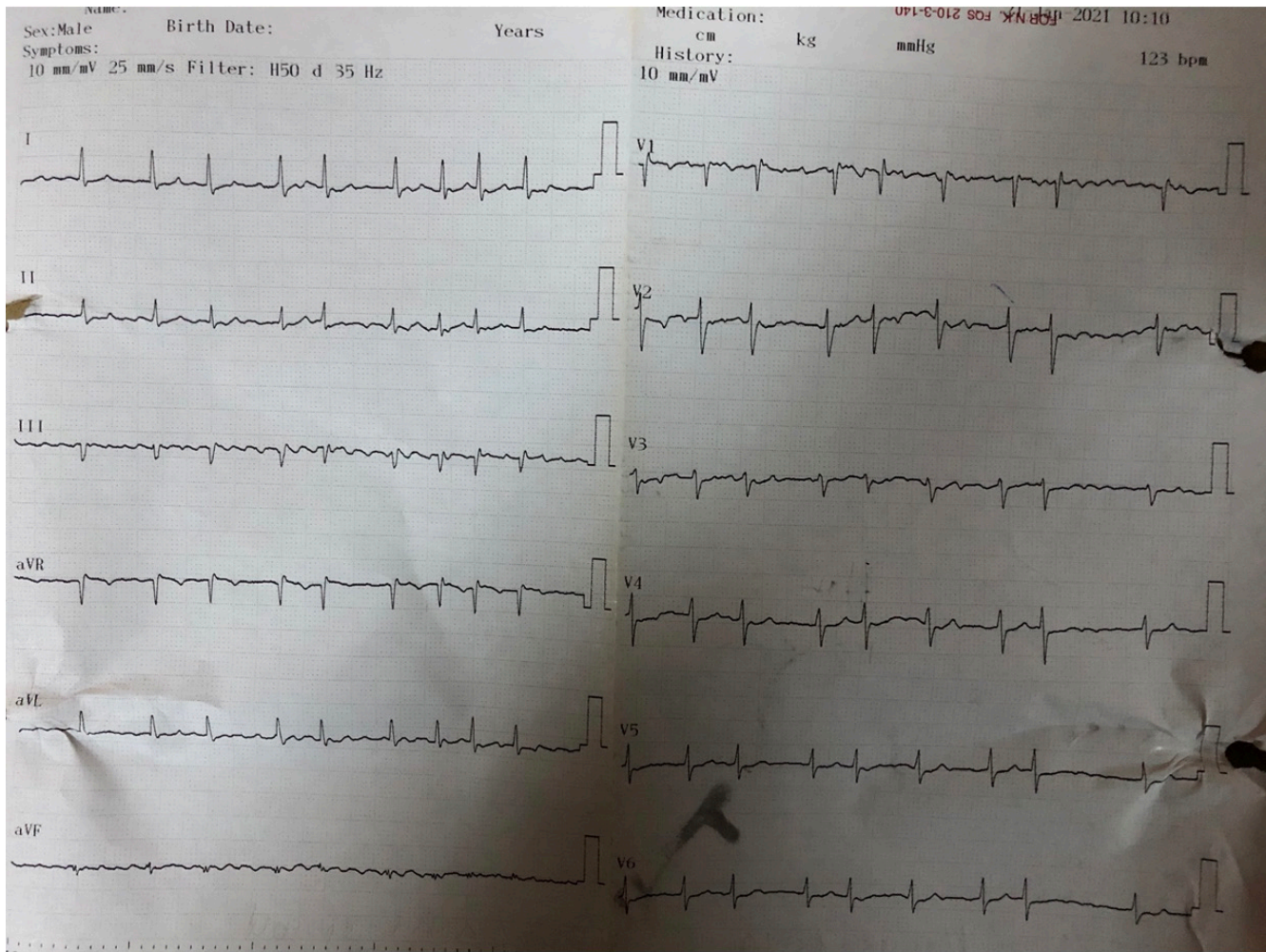
**Keywords:** *Amyloidosis, mitral valve regurgitation, heart failure*

### Introduction

Cardiac amyloidosis is a restrictive form of cardiomyopathy that occurs as a result of improper accumulation of endogenous proteins with impaired folding. Although the diagnostic awareness of this disease is increasing, many cases are easily overlooked due to the need for endomyocardial biopsy and the introduction of genetic diagnosis procedures in the definitive diagnosis of the disease. Due to hypertrophy

caused by cardiac infiltration; It is often confused with hypertensive heart disease or hypertrophic obstructive cardiomyopathy. The cases causing cardiac amyloidosis to occur due to two types of protein accumulation.<sup>1</sup> In immunoglobulin light chain (AL) amyloidosis, which occurs due to the accumulation of immunoglobulin light chain, 50% of the heart, 50% of the kidney involvement, 16% of the gastrointestinal system and 10%





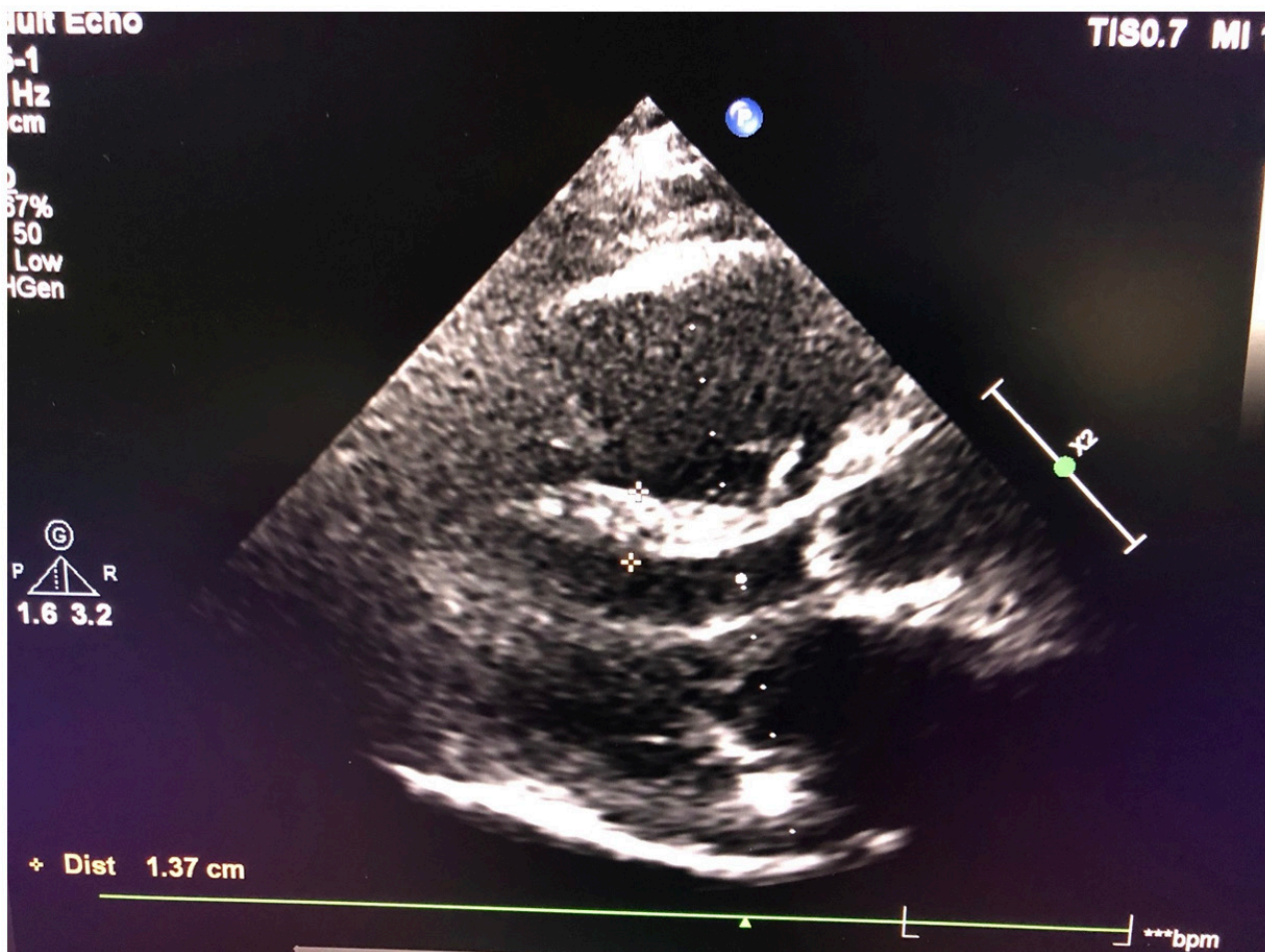
**Figure 1.** Voltage loss and atrial fibrillation were detected in the electrocardiography taken before the examination.

of neurological involvement occur.<sup>2</sup> Although transthyretin (TTR) amyloidosis, which occurs due to the accumulation of TTR produced in the liver, mostly involves the heart, accumulation occurs in soft tissues (carpal tunnel syndrome, etc.) and is called the wild type. In the inherited form of TTR amyloidosis, neurological system is affected, and it is inherited at a rate of 50%.<sup>3</sup> Low voltage<sup>4</sup> and conduction defects (e.g. atrial fibrillation) can be detected in electrocardiography, which is one of the non-invasive diagnostic methods. It occurs before low voltage heart failure findings occurring on electrocardiography (ECG) and hypertrophy on echocardiography (ECHO).<sup>5</sup> In the diagnosis of the disease, ventricular hypertrophy, left ventricular outflow stenosis, biatrial dilatation and hypertrophies in the atrioventricular valves can be detected on ECHO. Cardiac MRI, bone scintigraphy, genetic analysis can be performed

for diagnosis, and the gold standard diagnostic method is endomyocardial biopsy. Treatment in amyloidosis is plasma therapy or the use of stabilizers to prevent accumulation. In this case report, we will be sharing a 61-year-old male patient with hereditary TTR amyloidosis.

### Case Report

A 61-year-old male patient with persistent shortness of breath and headache was referred to our cardiology outpatient clinic by neurology. Hypotension was found in the detailed history of the patient. In the examination of the patient, his general condition was found to be moderate, heart rate 125 beats/min, arterial blood pressure 100/65 mmHg. In cardiac auscultation, a second-degree systolic murmur on the mitral valve and a pansystolic murmur on the tricuspid valve, and



**Figure 2.** Echocardiography revealed left ventricular hypertrophy, left atrial dilation, and 2<sup>nd</sup> degree mitral regurgitation.

rales in the lower zones on lung examination were detected. The patient had +1/+1 pretibial edema. Voltage loss and atrial fibrillation (AF) were detected in the ECG taken before the examination (Figure 1). In the biochemical tests performed on the patient at that moment, creatinine 1.2 g/dL, potassium 5.5 mmol/L and NT-proBNP 1,250 were found. Abnormal values were not found in other biochemical parameters. ECHO revealed left ventricular hypertrophy, left atrial dilation, and 2<sup>nd</sup> degree mitral regurgitation (Figure 2). The patient had 1-2° tricuspid regurgitation in the right ventricular evaluation. With these findings, heart failure with preserved ejection fraction (HFPEF) was initially considered in the patient. On the other hand, cardiac amyloidosis was also suspected due to the presence of left ventricular hypertrophy in echocardiography and low voltage in the precordial leads inconsistent

with left ventricular hypertrophy on the ECG. Internal medicine and neurology consultation was also requested to investigate neurological and gastrointestinal involvement. Diuretic therapy, diltiazem 2x90 mg and anticoagulation were initiated, and cardiology outpatient control was recommended to the patient. The patient was ultimately referred to the gastroenterology clinic after being evaluated by the internal medicine clinic, and as a result of rectal biopsy, primary amyloidosis was diagnosed.

## Discussion

Amyloidosis: it is a disease caused by the accumulation of proteins called amyloid with incorrectly folded beta chains in tissues. There are 4 types of amyloidosis: primary, secondary, familial, and senile amyloidosis. Cardiac

amyloidosis occurs when amyloids are deposited in myocytes. Cardiac amyloidosis can be seen in both primary and secondary types. However, it is more common in primary amyloidosis. Although diffuse myocardial involvement mostly causes restrictive cardiomyopathy, it may rarely cause constrictive pericarditis by causing pericardial involvement in some cases. Much more rarely causes cardiac tamponade.<sup>6</sup> In ECHO, thickening of the left ventricular wall, non-dilated left ventricular cavity, diastolic dysfunction and enlargement of the atria are common features.<sup>7</sup> On the other hand, the most common abnormality in cardiac amyloidosis on ECG is low voltage.<sup>8</sup> Amyloidosis in cardiac involvement leads to restrictive cardiomyopathy, leading to a decrease in early diastolic filling and peripheral edema findings occur. For definitive diagnosis, only if abdominal fat biopsy is negative, endomyocardial biopsy can be considered.<sup>9</sup> Another clinical picture that can be caused by cardiac amyloidosis is congestive heart failure. More rarely, orthostatic hypotension can be seen due to nephrotic syndrome caused by vascular involvement and renal involvement.<sup>10</sup> It has also been reported that it may cause arrhythmias and sudden death by involving her purkinje, which is one of the cardiac conduction pathways.<sup>11</sup> Treatment in primary amyloidosis is chemotherapy and bone marrow transplantation. Many cases of amyloidosis are not suitable for cardiac transplantation due to significant non-cardiac amyloidosis. However, in selected cases, chemotherapy and transplantation after bone marrow transplantation can be applied in primary amyloidosis.<sup>12</sup>

### Conflict of Interests

Authors declare that there are none.

### Acknowledgment

This study has been presented in 17<sup>th</sup> Uludag Internal Medicine National Winter Congress,

6<sup>th</sup> Bursa Family Medicine Association National Congress, 11<sup>th</sup> Uludag Internal Medicine Nursing Congress, 5–7 March 2021, Bursa, Turkey.

### References

- Joshi VV. Peripheral neuroblastic tumors: pathologic Sipe JD, Cohen AS. Review: history of the amyloid fibril. *J Struct Biol*. 2000 Jun;130(2-3):88-98. doi: 10.1006/jsbi.2000.4221.
- Gertz MA. Immunoglobulin light chain amyloidosis diagnosis and treatment algorithm 2018. *Blood Cancer J*. 2018 May 23;8(5):44. doi: 10.1038/s41408-018-0080-9.
- Ruberg FL, Berk JL. Transthyretin (TTR) cardiac amyloidosis. *Circulation*. 2012 Sep 4;126(10):1286-300. doi: 10.1161/CIRCULATIONAHA.111.078915.
- Cyrille NB, Goldsmith J, Alvarez J, Maurer MS. Prevalence and prognostic significance of low QRS voltage among the three main types of cardiac amyloidosis. *Am J Cardiol*. 2014 Oct 1;114(7):1089-93. doi: 10.1016/j.amjcard.2014.07.026.
- Falk RH, Alexander KM, Liao R, Dorbala S. AL (light-chain) cardiac amyloidosis: A review of diagnosis and therapy. *J Am Coll Cardiol*. 2016 Sep 20;68(12):1323-41. doi: 10.1016/j.jacc.2016.06.053.
- Gertz MA, Kyle RA. Primary systemic amyloidosis—a diagnostic primer. *Mayo Clin Proc*. 1989 Dec;64(12):1505-19. doi: 10.1016/s0025-6196(12)65706-1.
- Murtagh B, Hammill SC, Gertz MA, Kyle RA, Tajik AJ, Grogan M. Electrocardiographic findings in primary systemic amyloidosis and biopsy-proven cardiac involvement. *Am J Cardiol*. 2005 Feb 15;95(4):535-7. doi: 10.1016/j.amjcard.2004.10.028.
- Falk RH. Diagnosis and management of the cardiac amyloidoses. *Circulation*. 2005 Sep 27;112(13):2047-60. doi: 10.1161/CIRCULATIONAHA.104.489187.
- Gertz MA, Lacy MQ, Dispenzieri A. Amyloidosis: recognition, confirmation, prognosis, and therapy. *Mayo Clin Proc*. 1999 May;74(5):490-4. doi: 10.4065/74.5.490.
- Fukuda N, Takeichi N, Soeki T, Shinohara H, Yui Y, Tamura Y, Nakamura M. Cardiac amyloidosis with atrioventricular valve thickening and left atrial dysfunction: a case report. *J Cardiol*. 1998;31 Suppl 1:123-9 (in Japanese).
- Reisinger J, Dubrey SW, Lavalley M, Skinner M, Falk RH. Electrophysiologic abnormalities in AL (primary) amyloidosis with cardiac involvement. *J Am Coll Cardiol*. 1997 Oct;30(4):1046-51. doi: 10.1016/s0735-1097(97)00267-2.
- Skinner M, Sancherawala V, Seldin DC, Dember LM, Falk RH, Berk JL, Anderson JJ, O'Hara C, Finn KT, Libbey CA, Wiesman J, Quillen K, Swan N, Wright DG. High-dose melphalan and autologous stem-cell transplantation in patients with AL amyloidosis: an 8-year study. *Ann Intern Med*. 2004 Jan 20;140(2):85-93. doi: 10.7326/0003-4819-140-2-200401200-00008.

