

Clinical Correlation of Change in Sagittal Parameters after Anterior Cervical Microdiscectomy

Timur Yildirim¹

¹Department of Medicana Konya Hospital Neurosurgery, Faculty of Medicine, KTO Karatay University, Konya, Turkey

Copyright@Author(s) - Available online at <https://dergipark.org.tr/en/pub/mbsjohs>

Content of this journal is licensed under a Creative Commons Attribution-NonCommercial 4.0 International License,



Received: 12 February 2021, Accepted: 23 March 2021, Published online: 30 April 2021
© Ordu University Institute of Health Sciences, Turkey, 2021

Abstract

Objective: Cervical radiculopathy is the syndrome of pain and / or sensorimotor deficit caused by compression of the cervical nerve root. Symptoms of cervical radiculopathy in the upper limb are described as pain, numbness, or weakness. Conservative treatment is recommended initially for degenerative cervical radiculopathy. Surgical treatment is recommended in cases where progressive loss of muscle strength does not respond to conservative therapy. Many radiographic parameters are used to define the sagittal alignment of the cervical spine. This variation contrasts with the assessment of caudal spine segments where there are more established guides for measuring deformity angles. The aim of this study is to evaluate the effect of anterior cervical discectomy and fusion, which are widely used in spinal surgery practice, on cervical sagittal alignment.

Methods: We retrospectively evaluated 33 patients who were operated with anterior cervical discectomy and fusion technique with the diagnosis of single level degenerative cervical disc hernia after an average of 3 months of follow-up period. For radiological evaluation, we analyzed the C2-C7 lordosis angles, the anterior and posterior disc heights at the operating level on lateral scoliosis radiographs, preoperatively and at 3rd month postoperatively. Japanese Orthopedic Association scores and visual analog scale scores were examined to evaluate clinical results.

Results: A statistically significant difference was found between the preoperative radiological sagittal parameters and the postoperative 3rd month ($p = 0.001$). When the clinical correlation of the findings was examined, a statistically significant difference was found in the Japanese Orthopedic Association scores and visual analog scale scores of the patients measured preoperatively versus 3 months postoperatively ($p < 0.001$).

Conclusion: Radiological and clinical parameters improve significantly in patients after single level anterior cervical discectomy surgery.

Key words: Cervical disc hernia, microdiscectomy, sagittal lordosis.

Suggested Citation Yildirim T. Clinical correlation of changes in sagittal parameters after anterior cervical microdiscectomy. Mid Blac Sea Journal of Health Sci, 2021; 7(1):64-68

Address for correspondence/reprints:

Timur Yildirim

Telephone number: +90 (332) 221 8080

E-mail: mdtimur@hotmail.com

Introduction

Degenerative changes in the cervical spine can impair quality of life and decrease functionality (1). These degenerative changes can often result in pain, radiculopathy, and myelopathy, and they sometimes require surgery. Both anterior and posterior methods are used in surgical treatment. Anterior cervical discectomy and fusion (ACDF) technique is most commonly used in the surgical treatment of cervical degenerative disc diseases (2). Many studies show that cervical kyphosis is the common cause of increased neck pain before and after cervical surgery. In addition to decompression of neural structures, achieving cervical lordosis is an important surgical goal in ACDF (3). The basic physiopathology of disc degeneration is the dehydration of the disc after changes develop in the collagen tissue in the structure of the disc, which consequently decreases the disc height in the spinal segment (4). Loss of height at the level of the cervical spine in the degenerative process often results in loss of lordosis, causing chronic neck pain. In the degenerative process leading to the loss of disc height, the amount of load carried by the cervical anterior column is transferred to the posterior elements of the spine at an increasing rate. With the disc cages used in anterior surgery, the height between discs can often be restored (5). Thus, the height of the foramen also increases (1). The aims of this study were to evaluate the effect of ACDF on cervical sagittal alignment and to correlate the surgical effect with clinical results.

Methods

In this study, 33 patients who underwent ACDF for a single-level cervical disc hernia at the Ordu University Faculty of Medicine and the KTO Karatay University Faculty of Medicine, Medicana Konya Hospital, Neurosurgery Department, between January 2019 and December 2019 were evaluated (Table 1). Patients younger than age 18 years and patients who had previously undergone anterior and/or posterior cervical surgery were not included in the study. Surgical procedures were performed by a single surgeon who had worked in both academic institutions. In the preoperative and postoperative follow-up of the patients, the visual analog scale (VAS) scores and Japanese Orthopedic Association (JOA) scores were evaluated for neck pain and clinical improvement. The C2-C7 lordosis angle (Figure 1A-B) and the anterior/posterior disc heights (Figure 2A-B) were measured preoperatively and at 3 months postoperatively to assess cervical sagittal parameters.

Operative Technique

The patients underwent operation under general anesthesia using the standard Smith-Robinson method with microscopy (6). After the decompression procedure, a locked polyetheretherketone cage was placed according to the patient's preoperative cervical lordosis or kyphosis (a lower cage was placed in patients with preoperative lordosis, and a higher cage was placed in patients with preoperative kyphosis). The height of the cage used was 6-7 mm

Statistical analysis

The descriptive statistics of the continuous data were reported as the mean \pm standard deviation (SD) and the median range values. Categorical variables were summarized by frequency and percentage. Normality assumptions of continuous variables were evaluated using visual (histogram and Q-Q plots) and statistical (Shapiro-Wilk test) methods. Before-and-after comparisons were performed using the paired samples t-test for normally distributed variables and the Wilcoxon signed-rank test for non-normally distributed variables. All data were analyzed using SPSS 23 software (IBM, Inc., Chicago, IL, USA), and a p value less than 0.05 was considered statistically significant.

Ethics of the Study

This study was conducted with the approval of Ordu University Clinical Research Ethics Committee number (2021/29)

Results

Thirty-three patients were included in the study; 20 (60.6%) of the patients were women, and 13 (39.4%) were men. The mean age of the patients was 44.06 ± 10.33 years (range, 29-74 years), and the median age was 42 years. One patient (3.0%) had C4-C5 disc herniation, two patients (6.1%), C3-C4; 12 patients (36.4%), C5-C6; and 18 patients (54.5%), C6-C7. The sociodemographic and medical characteristics of the patients included in the study are summarized in Table 1.

As shown in Table 2, the Wilcoxon signed-rank test indicated that the postoperative C2-C7 lordosis angle (median = 7.30°) was significantly higher than the preoperative angle (median = 3° ; $p = 0.001$). The postoperative anterior disc height (median = 0.64 cm) was significantly higher than the preoperative height (median = 0.37 cm; $p < 0.001$). The postoperative JOA score (median = 18) was significantly higher than the preoperative score (median = 16; $p < 0.001$). The postoperative VAS score (median = 2) was

significantly lower than the preoperative score (median = 9; $p < 0.001$).

The paired samples t-test indicated that the postoperative posterior disc height (mean \pm SD, 0.54 \pm 0.13 cm) was significantly higher than the preoperative height (mean \pm SD = 0.37 \pm 0.07 cm; $p < 0.001$). A comparison of the pre- and postoperative variables is shown in Figure 3.

Table 1. Patients characteristics

Patient Number	Age	Gender	Spinal Level
1	29	M	C6-7
2	74	F	C3-4
3	38	F	C5-6
4	59	M	C6-7
5	46	F	C5-6
5	31	F	C5-6
7	44	M	C5-6
8	44	M	C6-7
9	38	F	C6-7
10	45	M	C5-6
11	54	F	C6-7
12	48	F	C6-7
13	41	F	C6-7
14	33	F	C6-7
15	40	F	C4-5
16	57	F	C5-6
17	30	F	C5-6
18	42	F	C5-6
19	65	F	C3-4
20	34	M	C6-7
21	44	M	C6-7
22	58	F	C6-7
23	46	M	C6-7
24	41	M	C6-7
25	39	M	C6-7
26	56	F	C6-7
27	41	M	C6-7
28	43	F	C5-6
29	39	F	C5-6
30	37	M	C5-6
31	48	M	C6-7
32	33	F	C6-7
33	37	F	C5-6

M:Male; F:Female.

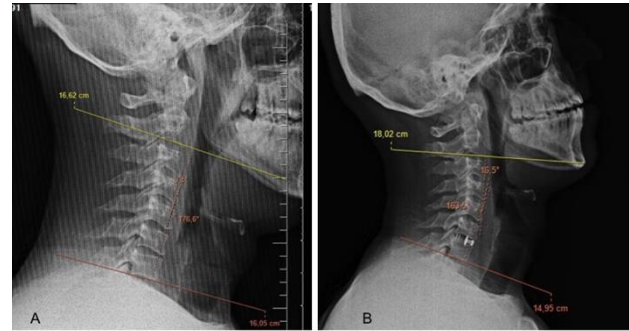


Figure 1. A. Preoperative C2-7 lordosis angle, B. Postoperative C2-7 lordosis angle

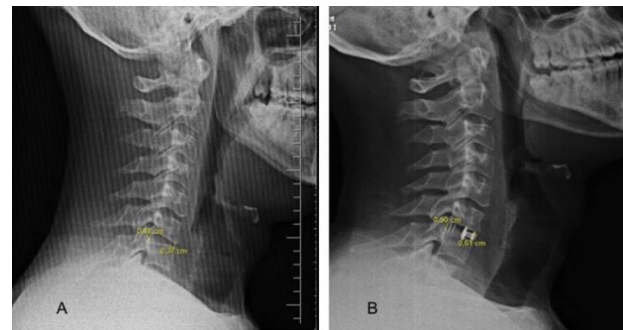


Figure 2. A-B: A.Preoperative disc height, B. Postoperative disc height

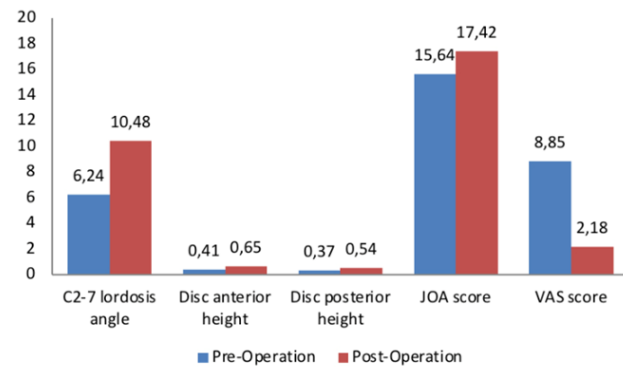


Figure 3. Comparison of the study variable values in preoperative and postoperative period.

Discussion

Cervical disc hernias are one of the most common degenerative diseases of the cervical spine (4, 7). Pain radiating to the neck and arms is typical. Flattening of cervical lordosis is observed in radiological images taken in many patients. In contrast to the lumbar and cervical spine, which should almost always be lordotic for standing with two legs, the thoracic spine must be kyphotic to balance the caudal lumbar spine (8). Continuation of the kyphosis towards the cervical levels disrupts the sagittal alignment and may cause pain. In addition, it is known that the lordosis of the cervical spine is important to maintain a horizontal gaze (9). In the degenerative process leading to the

loss of disc height, the amount of load carried by the cervical anterior column is transferred to the posterior elements of the spine at an increasing rate. Although some studies found flattened cervical spine alignment in asymptomatic participants, most patients with chronic neck pain show lordosis flattening. (10, 11, 12).

Clinical studies have shown that one of the most important causes of neck pain before and after cervical surgery is associated with kyphosis (13). Achieving cervical lordosis is an important surgical goal in ACDF as well as decompression of neural structures. ACDF is currently the most common surgical approach in cervical degenerative disc disease. ACDF effectively restores the sagittal sequence, especially at C2-C7 angle (14). Another study showed that improvement in focal lordosis correlated with improvement in overall cervical lordosis (C2-C7) (15). Another clinical study investigated clinical outcomes and sagittal alignment in patients who underwent ACDF and fusion, and minor changes were detected in preoperative and postoperative kyphosis angles. There was no significant relationship between the change in kyphotic angle and postoperative functional status. In addition, no significant change was found in the mean C2-C7 Cobb angles (16). However, in our study, a statistically significant relationship was observed between postoperative functional status and achieving lordosis. The postoperative C2-C7 lordosis angle (median = 7.30°) was significantly higher than the preoperative angle (median = 3°; $p = 0.001$). In our results, cervical lordosis improved during the postoperative period compared with the preoperative period, and the resulting difference was statistically significant.

In a study, in which 48 patients who were operated with anterior or posterior technique with the diagnosis of spondylotic myelopathy were examined, it was shown that C2-7 lordosis of patients who underwent anterior approach improved more than patients who were operated with the posterior method (17). In our study, anterior surgery was performed with the diagnosis of cervical disc herniation and similar results to the literature were obtained. The difference between the preoperative cervical lordosis angle (between C2 and C7) and the angle measured 3 months postoperatively was statistically significant. In addition, the change in favor of lordosis correlated with a statistically significant improvement in postoperative VAS scores and JOA scores. In our study, the postoperative JOA score was significantly higher than the preoperative score ($p < 0.001$) and the postoperative VAS score was significantly lower than

the preoperative score ($p < 0.001$). Removing all disc material anteriorly from the uncinat process to adjacent uncinat process following placement of bone grafts or cages maintains the cervical disc height and prevent kyphosis resulting in indirect foraminal decompression (18). In our study, the postoperative anterior and posterior disc heights were significantly higher than the preoperative heights. Likely as a result of decompression and increased disc distance, the postoperative VAS scores decreased significantly. Regaining the disc height also increases the carrying capacity of the anterior column and decreases the load on the posterior column. In this way, there is a significant reduction in the pain levels felt in the back of the neck. This work shows that, in patients with abnormal cervical sagittal alignment, single-level ACDF in the cervical region provides significant clinical improvement, as documented by radiological improvements early in the postoperative period.

Conclusions

ACDF is a method that can be used to provide cervical sagittal restoration for patients with cervical degeneration. ACDF in cervical disc hernias has a positive effect on correcting cervical lordosis. In our study, a statistically significant difference was found in the results of the radiological and clinical evaluations before and after surgery. Maintaining the normal disc and foramen height of the cervical spine has a significant effect on clinical pain parameters and lordosis. In terms of clinical evaluation, a significant improvement was observed in VAS and JOA values after ACDF. However, the study is limited by its small number of patients and relatively short patient follow-up periods. More patients and longer follow-up times are required to draw more detailed conclusions about the effectiveness and impact of ACDF on cervical sagittal alignment.

Ethics Committee Approval: This study was conducted with the approval of Ordu University Clinical Research Ethics Committee number (2021/29)

Peer-review: Externally peer-reviewed.

Author Contributions:

Concept, Design, Literature search, Data Collection and Processing, Analysis or Interpretation, Writing: T.Y.

Conflict of Interest: No conflict of interest was declared by the author.

Financial Disclosure: The author declared that this study hasn't received no financial support.

References

1. Ames CP, Blondel B, Scheer JK, Schwab FJ, Le Huec JC, Massicotte EM, et al. Cervical radiographical alignment: comprehensive assessment techniques and potential importance in cervical myelopathy. *Spine (Phila Pa 1976)*. 2013;38:149–60.
2. Korinth MC. Treatment of cervical degenerative disc disease: current status and trends. *Zentralbl Neurochir*. 2008;69(3):113–24.
3. Koeppen D, Piepenbrock C, Kroppenstedt S, Cabraja M. The influence of sagittal profile alteration and final lordosis on the clinical outcome of cervical spondylotic myelopathy: a Delta-Omega-analysis. *PLoS One*. 2017;12:e0174527.
4. Teraguchi M, Yoshimura N, Hashizume H, Muraki S, Yamada H, Minamide A, et al. Prevalence and distribution of intervertebral disc degeneration over the entire spine in a population-based cohort: the Wakayama spine study. *Osteoarthritis Cartilage*. 2014;22:104–10.
5. Cepoiu-Martin, M, Faris P, Lorenzetti D, Prefontaine E, Noseworthy T, Sutherland L. Artificial cervical disc arthroplasty: a systematic review. *Spine (Phila Pa 1976)*. 2011;36(25):1623–33.
6. Smith GW, Robinson RA. The treatment of certain cervical spine disorders by anterior removal of the intervertebral disc and interbody fusion. *J Bone Joint Surg Am*. 1958;40:607–24.
7. de Bruin F, Ter Horst S, van den Berg R, de Hooge M, van Gaalen F, Fagerli KM, et al. Signal intensity loss of the intervertebral discs in the cervical spine of young patients on fluid sensitive sequences. *Skeletal Radiol*. 2016;45:375–81.
8. Takeshima T, Omokawa S, Takaoka T, Masafumi A, Yurito Y, Yoshinori T. Sagittal alignment of cervical exion and extension: lateral radiographic analysis. *Spine*. 2002;27:E348–55.
9. Scheer JK, Tang JA, Smith JS, Acosta FL Jr, Protopsaltis TS, Blondel B, et al. Cervical spine alignment, sagittal deformity, and clinical implications: a review. *J Neurosurg Spine*. 2013;19:141–59.
10. Canavese F, Turcot K, De Rosa V, De Coulon G, Kaelin A. Cervical spine sagittal alignment variations following posterior spinal fusion and instrumentation for adolescent idiopathic scoliosis. *Eur Spine J*. 2011;20:1141–8.
11. Hey HWD, Lau ETC, Wong GC, Tan KA, Liu GK P, Wong HK. Cervical alignment variations in different postures and predictors of normal cervical kyphosis. *Spine*. 2017;42:1614–21.
12. Yu M, Zhao WK, Li M, Wang SB. Analysis of cervical and global spine alignment under Roussouly sagittal classification in Chinese cervical spondylotic patients and asymptomatic subjects. *Eur Spine J*. 2015;24:1265–73.
13. Park MS, Kelly MP, Lee DH, Min WK, Rahman RK, Riew KD. Sagittal alignment as a predictor of clinical adjacent segment pathology requiring surgery after anterior cervical arthrodesis. *Spine J*. 2014;14:1228–34.
14. Kim HJ, Choi BW, Park J, Pesenti S, Lafage V. Anterior cervical discectomy and fusion can restore cervical sagittal alignment in degenerative cervical disease. *Eur J Orthop Surg Traumatol*. 2019;29:767–74.
15. Gillis CC, Kaszuba MC, Traynelis VC. Cervical radiographic parameters in 1- and 2-level anterior cervical discectomy and fusion. *J Neurosurg Spine*. 2016;25:421–9.
16. Jagannathan J, Shaffrey CI, Oskouian RJ, Dumont AS, Herrold C, Sansur CA, et al. Radiographic and clinical outcomes following single-level anterior cervical discectomy and allograft fusion without plate placement or cervical collar. *J Neurosurg Spine*. 2008;8:420–8.
17. Cabraja M, Abbushi A, Koeppen D, Kroppenstedt S, Woiciechowsky C. Comparison between anterior and posterior decompression with instrumentation for cervical spondylotic myelopathy: sagittal alignment and clinical outcome. *Neurosurg Focus*. 2010;28:E15.
18. Kang KC, Lee HS, Lee JH. Cervical Radiculopathy Focus on Characteristics and Differential Diagnosis. *Asian Spine J*. 2020;14;6:921-30.