

Paranasal sinus fungus ball: analysis of clinical characteristics and surgical outcomes

Ercan Pınar, Abdulkadir İmre, Ahmet Ata Ece, İbrahim Aladağ, Hale Aslan,
Yılmaz Özkul, Elif Dinçer

Department of Otorhinolaryngology, İzmir Katip Çelebi University Atatürk Training and Research Hospital, İzmir, Turkey

Abstract

Objective: The aim of the present study was to analyse the clinical, radiographic, and surgical outcomes of paranasal fungus ball.

Methods: A retrospective data analysis was performed on 16 patients who underwent endoscopic sinus surgery for paranasal sinus fungus ball between December 2005 and November 2014. The patient's demographic data, clinical presentations, radiological findings and surgical outcomes were analysed.

Results: There were 10 female (62.5%) and six male (37.5%) patients with a mean age of 53.6 (range: 32 to 74) years. Most common symptoms were headache and facial pain. Computed tomography showed a hyper-dense area in 12 patients (75%) and sclerosis in bony walls of the sinus in 13 patients (81.3%). Magnetic resonance imaging revealed a marked low intensity on T2 weighted images in all cases (100%). All patients were treated with functional endoscopic sinus surgery. Only one patient had a recurrence in the postoperative period.

Conclusion: The surgical opening of affected sinus ostium and removal of the fungal concentration were the treatment of choice in all cases.

Keywords: Paranasal sinus fungus ball, mycetoma, surgery.

Özet: Paranasal sinüs mantar topu: Klinik özellikler ve cerrahi sonuçlar

Amaç: Bu çalışmanın amacı paranasal mantar topunun klinik, radyografik ve cerrahi sonuçlarını analiz etmektir.

Yöntem: 2005 Aralık – 2014 Kasım tarihleri arasında paranasal mantar topu için endoskopik sinüs cerrahisi geçiren 16 hastanın verileri geriye dönük incelendi. Hastanın demografik verileri, klinik sunumları, radyolojik bulguları ve cerrahi sonuçları analiz edildi.

Bulgular: Çalışmaya yaş ortalaması 53.6 (aralık: 32–74) yıl olan 10 (62.5%) kadın ve 6 (37.5%) erkek hasta katılmıştır. En sık görülen semptomlar baş ve yüz ağrısı idi. Bilgisayarlı tomografi 12 (75%) hastada hiperdens bir alan ve 13 (81.3%) hastada sinüsün kemik yapıdaki duvarlarında skleroz olduğunu göstermiştir. Manyetik rezonans görüntüleme olguların tümünde (100%) T2-ağırlıklı görüntüleme, belirgin derecede düşük bir dansitenin var olduğunu ortaya koymuştur. Hastaların hepsi işlevsel endoskopik sinüs cerrahisiyle tedavi edilmiştir. Yalnızca bir hastada postoperatif dönemde nüks olmuştur.

Sonuç: Her olguda etkilenmiş sinüs ağzının cerrahi yolla açılması ve fungal yoğunluğun ortadan kaldırılması tercih edilen tedavi şekli olmuştur.

Anahtar sözcükler: Paranasal mantar topu, misetom, cerrahi.

Fungal rhino-sinusitis (FRS) can be broadly divided into two categories based on histopathological findings: invasive and non-invasive, depending on the status of the mucosal layer. The invasive diseases include (1) acute invasive (fulminant) FRS, (2) granulomatous invasive FRS and (3) chronic invasive FRS. The non-invasive diseases include (1) saprophytic fungal infestation, (2) fungal ball, and (3) fungus related eosinophilic FRS that includes allergic fungal rhino-

sinusitis. Invasive FRS mostly affects immuno-compromised patients, whereas the non-invasive form occurs in immuno-competent patients.^[1]

Fungal ball is described as the presence of non-invasive accumulation of dense conglomeration of fungal hyphae in one sinus cavity. Various terms, such as mycetoma, aspergilloma, and chronic non-invasive granuloma have been used in the literature.^[1,2] Fungal rhinosinusitis is

Correspondence: Ercan Pınar, MD. Department of Otorhinolaryngology, İzmir Katip Çelebi University, Atatürk Training and Research Hospital, İzmir, Turkey. e-mail: epinar66@yahoo.com

Received: October 2, 2015; **Accepted:** October 30, 2015

Online available at:
www.entupdates.org
doi:10.2399/jmu.2015003007
QR code:



encountered in approximately 10% of all the patients requiring surgery for a nose or sinus disease. Fungal or mixed fungal infections are responsible for 13.5% to 28.5% of all maxillary sinusitis cases.^[2,3]

The purpose of this study was to analyse the characteristics of paranasal sinus fungus ball based on presenting symptoms, radiologic findings, and surgical outcomes.

Materials and Methods

Surgical design

We retrospectively reviewed the clinical records of 16 patients diagnosed with paranasal sinus fungus ball between December 2005 and November 2014. The diagnosis was based on histological examination of the surgically removed material.

Outcome parameters

We analysed age, sex, clinical presentation, location of the fungus ball, radiologic imaging, and surgical outcomes. All patients had computed tomography (CT) and 12 of 16 patients had magnetic resonance imaging (MRI). Successful outcome was defined as an adequate opening of the operated sinus ostium. Patients were followed-up for at least three months postoperatively.

Results

There were 10 female (62.5%) and six male (37.5%) patients with a mean age of 53.6 (range: 32 to 74) years. The majority of the patient complaints were headache and facial pain followed by post-nasal discharge. Paranasal fungus ball was seen predominantly in maxillary sinus (75%), followed by sphenoid sinus (25%). Patients' demographic data and clinical presentations are shown in Table 1.

Table 1. Clinic presentation of patients with paranasal sinus fungus ball.

Variable		n (%)
Gender	Female	10 (62.5%)
	Male	6 (37.5%)
Symptoms	Headache	11 (68.8%)
	Facial pain	4 (25%)
	Postnasal discharge	3 (18.8%)
Sinus localizations	Maxillary sinus	12 (75%)
	Sphenoid sinus	4 (25%)
Culture study	Aspergillus	3 (18.8%)
	Candida	1 (6.3%)
	Negative	12 (75%)

CT was performed pre-operatively for all patients. A hyper-dense area was observed in 12 patients (75%) and sclerosis of bony walls of the sinus was noted in 13 patients (87.5%) (Fig. 1). MRI was performed in 12 of the patients and a low intensity area was observed in the affected sinuses of all cases. Hypo-intensity on T1-weighted images and significant hypo-intensity on T2-weighted images were the most common MRI findings (Fig. 2). The radiologic findings of the patients are shown in Table 2.

The definitive diagnosis was made by the pathologist in all cases. There were no cases of invasive fungal sinusitis. *Aspergillus fumigatus* was the main causative fungus. The sensitivity of the culture was 25% (4 of 16 patients).

The treatment of choice was functional endoscopic sinus surgery in all patients. The affected sinus was widely opened and the mass was meticulously removed. The sinus was irrigated with high-pressure saline to remove fungal debris. Recurrence was detected in a single patient, one year after the operation.

Discussion

Paranasal sinus fungus ball is predominantly observed in older and female patients. Nicolai et al. found mean age of 52.7 years and female predominance of 73.8%. Similarly, mean age and the ratio of female patients were 49 years and 60%, respectively, in the study conducted by Dufour et al. In our series, mean age was 53.6 and the ratio of female patients was 62.5%.

Paranasal sinus fungus ball is most frequently encountered in the maxillary sinus followed by the sphenoid

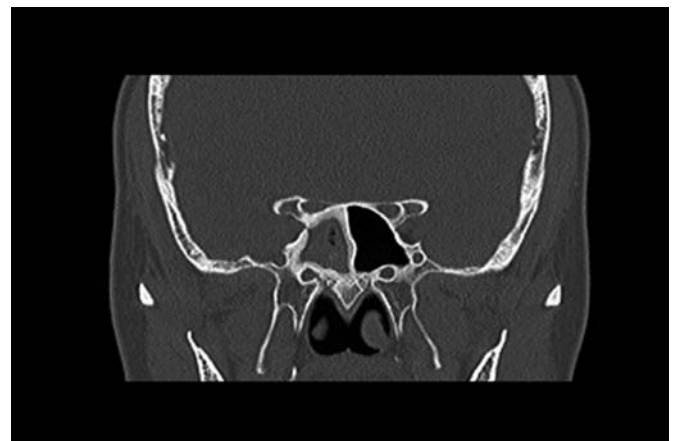


Fig. 1. Coronal paranasal sinus computed tomography showing right sphenoid sinus heterogeneous opacification, and bone thickening of the sinus wall.

Table 2. Radiologic findings of patients with paranasal sinus fungus ball.

Radiologic signs		n (%)
CT signs	Hyperdense area on CT	12 (75%)
	Sclerosis of sinus wall	13 (81.3%)
	Total opacification	13 (81.3%)
MRI signs	T1-weighted Iso-hypointensity	12 (75%)
	T2-weighted Marked hypointensity	16 (100%)

CT: computed tomography; MRI: magnetic resonance imaging

sinus.^[3-5] The reason for this remains unexplained but the aerogenic theory suggests that ethmoid sinus is where inhaled fungus spores accumulate and these become pathogenic when the sinus begins to become anaerobic. Similarly, in our study, paranasal fungus ball was more common in maxillary sinus (75%) than in sphenoid sinus (25%).

The patients' demographic CT findings include ipsilateral involvement, bone thickening of the diseased sinus wall and complete heterogeneous sinus opacity with a hyperdense area within the sinus. This high density is the consequence of the high content of heavy metals (iron and manganese) and calcium within the fungal hyphae and is extremely specific but lacks sensitivity.^[6,7] In our case series, CT showed high-density mass in 75% of cases. However, sclerosis and thickening of the diseased sinus wall was found in 87.5% of cases. Sclerosis of the sinus wall was the most common CT finding in previous studies.^[8-10] When there is a suspicion of a fungal disease with or without an intra-cranial or intra-orbital invasion and the CT images are not conclusive for identification of fungal disease, MRI should be used for differential diagnosis.

The causative fungus was mainly *Aspergillus* species for paranasal sinus fungus ball as shown by previous histological examinations and culture studies.^[1,2,10] However, culture findings had extremely low sensitivity, previous studies observed a sensitivity ranging from 20.3% to 31.0%.^[2,11,12] This difficulty in getting fungi to grow can be attributed to the absence of the fungus ball.

Typical symptoms of paranasal sinus fungus ball are headache, nasal obstruction and postnasal drip; however, headache is reportedly the most common symptom.^[2,12-15] Headache and facial pain were the most common symptoms also in our series.

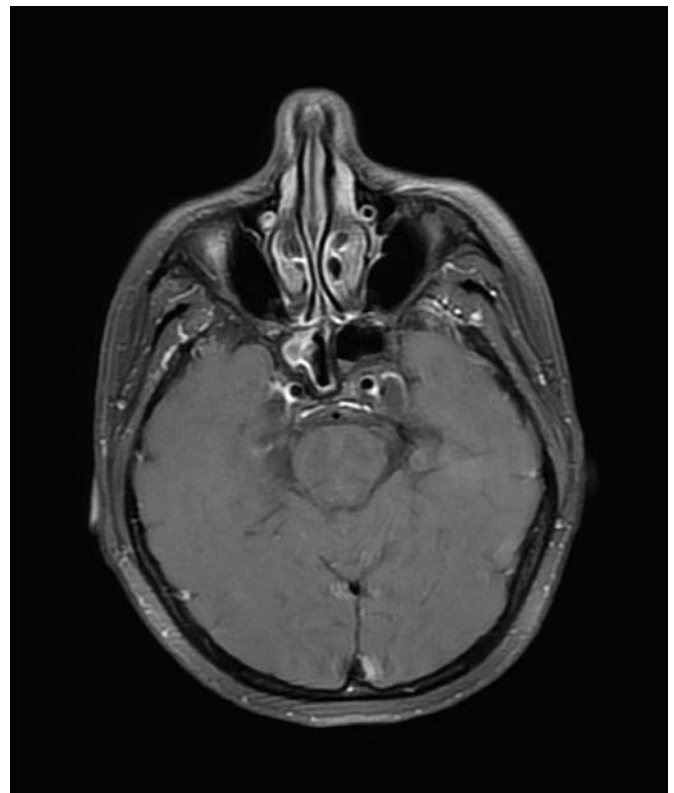


Fig. 2. Axial post-contrast T1 weighted magnetic resonance imaging showing hypo- and isointensity.

The prognosis for sinus fungus ball is favourable. Functional endoscopic sinus surgery is the treatment of choice. The affected sinus was widely opened and the mass was meticulously removed. The sinus was irrigated with saline at high pressure to remove fungal debris. The reported recurrence rates ranging from 0% to 10%.^[3,9,10,13-16] In our series only one patient had a recurrence, one year after operation.

The clinician should suspect sclerosis and micro-calcifications when the CT shows unilateral complete or partial opacity of the paranasal sinus. The treatment is surgical. Wide opening of the affected sinus and complete removal of the fungus ball are essential. The prognosis is very good.

Acknowledgement

The English in this document has been checked by at least two professional editors, both native speakers of English.

Conflict of Interest: No conflicts declared.

References

1. Chakrabarti A, Denning DW, Ferguson BJ, et al. Fungal rhinosinusitis: a categorization and definitional schema addressing current controversies. *Laryngoscope* 2009;119:1809–18.
2. Grosjean P, Weber R. Fungus balls of the paranasal sinuses: a review. *Eur Arch Otorhinolaryngol* 2007;264:461–70.
3. Nicolai P, Lombardi D, Tomenzoli D, et al. Fungus ball of the paranasal sinuses: experience in 160 patients treated with endoscopic surgery. *Laryngoscope* 2009;119:2275–9.
4. Dufour X, Kauffmann-Lacroix C, Ferrie JC, Goujon JM, Rodier MH, Klossek JM. Paranasal sinus fungus ball: epidemiology, clinical features and diagnosis. A retrospective analysis of 173 cases from a single medical center in France, 1989–2002. *Med Mycol* 2006;44:61–7.
5. Lai JC, Lee HS, Chen MK, Tsai YL. Patient satisfaction and treatment outcome of fungus ball rhinosinusitis treated by functional endoscopic sinus surgery. *Eur Arch Otorhinolaryngol* 2011;268:227–30.
6. Chen JC, Ho CY. The significance of computed tomographic findings in the diagnosis of fungus ball in the paranasal sinuses. *Am J Rhinol Allergy* 2012;26:117–9.
7. Bowman J, Panizza B, Gandhi M. Sphenoid sinus fungal balls. *Ann Otol Rhinol Laryngol* 2007;116:514–9.
8. Robey AB, O'Brien EK, Richardson BE, Baker JJ, Poage DP, Leopold DA. The changing face of paranasal sinus fungus balls. *Ann Otol Rhinol Laryngol* 2009;118:500–5.
9. Kim TH, Na KJ, Seok JH, Heo SJ, Park JH, Kim JS. A retrospective analysis of 29 isolated sphenoid fungus ball cases from a medical centre in Korea (1999–2012). *Rhinology* 2013;51:280–6.
10. Eloy P, Grenier J, Pirllet A, Poirrier AL, Stephens JS, Rombaux P. Sphenoid sinus fungal ball: a retrospective study over a 10-year period. *Rhinology* 2013;51:181–8.
11. Seo YJ, Kim J, Kim K, Lee JG, Kim CH, Yoon JH. Radiologic characteristics of sinonasal fungus ball: an analysis of 119 cases. *Acta Radiol* 2011;52:790–5.
12. Dufour X, Kauffmann-Lacroix C, Ferrie JC, et al. Paranasal sinus fungus ball and surgery: a review of 175 cases. *Rhinology* 2005;43:34–9.
13. Grosjean P, Weber R. Fungus balls of the paranasal sinuses: a review. *Eur Arch Otorhinolaryngol* 2007;264:461–70.
14. Socher JA, Cassano M, Filheiro CA, Cassano P, Felippu A. Diagnosis and treatment of isolated sphenoid sinus disease: a review of 109 cases. *Acta Otolaryngol* 2008;128:1004–10.
15. Pagella F, Matti E, De Bernardi F, et al. Paranasal sinus fungus ball: diagnosis and management. *Mycoses* 2007;50:451–6.
16. Lee TJ, Huang SF, Chang PH. Characteristics of isolated sphenoid sinus aspergilloma: report of twelve cases and literature review. *Ann Otol Rhinol Laryngol* 2009;118:211–7.

This is an open access article distributed under the terms of the Creative Commons Attribution-NonCommercial-NoDerivs 3.0 Unported (CC BY-NC-ND3.0) Licence (<http://creativecommons.org/licenses/by-nc-nd/3.0/>) which permits unrestricted noncommercial use, distribution, and reproduction in any medium, provided the original work is properly cited.

Please cite this article as: Pınar E, İmre A, Ece AA, Aladağ İ, Aslan H, Özkul Y, Dinçer E. Paranasal sinus fungus ball: analysis of clinical characteristics and surgical outcomes. *ENT Updates* 2015;5(3):124–127.