

# A Case of Tracheobronchitis Caused by *Chryseobacterium indologenes* in an Immunosuppressed Patient

Bağışıklığı Baskılanmış Bir Hastada  
*Chryseobacterium indologenes* Kaynaklı  
Trakeobronşit Olgusu

## Özet

*Chryseobacterium indologenes*, önceki adıyla *Flavobacterium indologenes*, toprak, su, bitki ve yiyeceklerde doğal olarak bulunan, hastane ortamında ise su sistemleri ve ıslak yüzeylerde saptanabilen bir bakteridir. İnsan florasında yer almayan bakteri, enfeksiyon etkeni olarak nadiren izole edilmekle birlikte, son yıllarda *Chryseobacterium indologenes* kaynaklı enfeksiyonların sıklığında artış görülmektedir. Bu raporda, karaciğer transplantasyonundan ardından immünoşüpresif tedavi gören bir hastada gelişen *Chryseobacterium indologenes* kaynaklı trakeobronşitin sunulması amaçlanmıştır.

**Anahtar Kelimeler:** *Chryseobacterium indologenes*; immünoşüpresyon; trakeobronşit

## Abstract

Found in water systems and on damp surfaces in the hospital environment, *Chryseobacterium indologenes* is a naturally occurring bacterium which is rarely isolated in clinical samples. However, in recent years, *Chryseobacterium indologenes* has increasingly emerged as an agent of infection in patients with suppressed immune systems. This report presents the case of a patient receiving immunosuppressive treatment following a liver transplant who developed *Chryseobacterium indologenes*-related tracheobronchitis.

**Key Words:** *Chryseobacterium indologenes*; immunosuppression; tracheobronchitis

Emel Caliskan<sup>1</sup>, Nida Kilic<sup>1</sup>,  
Fatih Alasan<sup>2</sup>, Ozge Kilincel<sup>1</sup>,  
Ildris Sahin<sup>1</sup>, C. Elif Ozturk<sup>1</sup>,  
Sukru Oksuz<sup>1</sup>

<sup>1</sup> Duzce University Faculty of Medicine,  
Department of Medical Microbiology,  
Duzce, Turkey.

<sup>2</sup> Duzce University Faculty of Medicine,  
Department of Chest Diseases,  
Duzce, Turkey

Geliş Tarihi /Received : 01.12.2015  
Kabul Tarihi /Accepted: 29.01.2016

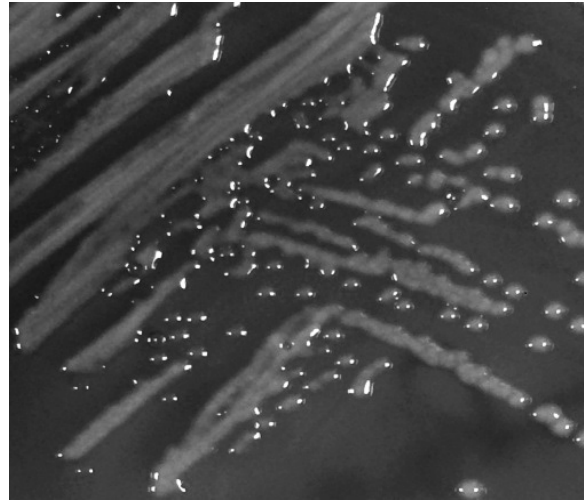
Sorumlu Yazar/Corresponding Author  
Dr. Nida Kılıç  
Duzce University Faculty of Medicine,  
Department of Medical Microbiology,  
Duzce, Turkey.  
E-mail: nidakilic87@gmail.com

## INTRODUCTION

*Chryseobacterium indologenes*, formerly known as *Flavobacterium indologenes*, is a naturally occurring bacterium found in soil, water, plants and food. In the hospital environment it can be detected in water systems and on damp surfaces (1). Flavobacteria are not generally known as infectious agents and are rarely isolated in humans (2). However, in recent years an increase in the frequency of *C. indologenes* infection has been observed. Its being resistant to chlorination does not constitute the cause of hospital infection (3). The organism is a non-motile, catalase-positive, indole-positive, nonfermentative, Gram-negative aerobic bacillus whose colonies can be easily detected as dark yellow spots in blood agar (1). Infection studies have identified risk factors to include hospitalization, cancer, immunosuppression, diabetes mellitus and prolonged antibiotic therapy (>14 days) (2-4). In the literature, *C. indologenes*-related cases of pneumonia, meningitis, pyomyositis, keratitis and bacteremia have been reported (1,3,4). Moreover, *C. indologenes*-related pneumonia has also been reported in a patient with non-Hodgkin lymphoma (5).

## CASE REPORT

A 60-year-old male presented at the thoracic diseases polyclinic with complaints of weakness, hemoptysis, and a productive cough with sputum. The patient was alert and his general condition was good. Physical examination detected a pulse rate of 88/min, temperature of 36.8 °C, and blood pressure of 110/70 mmHg. Auscultation revealed coarse crackles, but no rhonchus, in the left infrascapular region. White blood cell count was 3380/mm<sup>3</sup>. The patient's medical history revealed a diagnosis of tuberculosis 27 years previously and a subsequent 6 months' course of anti-tuberculosis treatment. The patient had a history of smoking 60 packets of cigarettes per year until 9 years previously, when he was diagnosed with chronic obstructive lung disease. Two years previously, after developing hepatic cirrhosis secondary to hepatitis C, the patient received a liver transplant. Following the transplant, therapy was begun with tacrolimus, ursodeoxycholic acid, mycophenolate mofetil, and prednisolone. The prednisolone treatment was stopped after a year, while



**Figure 1.** A typical yellow-pigmented *C. indologenes* colony in blood agar medium.

the other treatments were continued. As a result of the history and physical examination findings, a posterior-anterior (PA) radiograph was taken. An opacity was observed in the lower left lobe of the lung, and the patient was diagnosed with pneumonia. Ampicillin/sulbactam therapy was initiated. There was no growth in the sputum culture taken before treatment, and the results of the direct acid-fast stain performed on the sputum were negative. As the opacity in the lower left lobe seen on the PA radiograph had not regressed post treatment, and due to the lack of clinical improvement in the patient, a CT scan and bronchoscopy examination were indicated. As a result of the CT scan, it was considered that the cause of the opacity seen on the PA radiograph of the lower left lobe might be secondary fibrotic changes and not pneumonic infiltration. The results of the bronchoscopy showed that all bronchial mucosae were hyperemic, edematous and tended to bleed upon touch. In addition, white-colored secretions were observed on the right bronchus and even more on the left bronchus. It was thought that the mucosal findings were consistent with acute tracheobronchitis, and the likely focus of hemoptysis was determined in the upper division of the left upper lobe.

A bronchial lavage sample from this region was sent to the microbiology laboratory for examination. Examination of the Gram stain sample prepared from the patient's bronchial lavage specimen showed leukocytes and Gram-negative bacilli. Giemsa staining of the leukocytes determined their polymorphonuclear

character. Specimens were cultured in 5% Sheepblood agar (HiMedia, India), Eosin Methylene Blue agar (HiMedia, India) and Chocolate agar (HiMedia, India) and incubated at 37 °C for 24 hours. After incubation, yellow-pigmented colonies were observed in the blood agar (Fig. 1). Conventional methods were applied to identify the colonies. Oxidase and indole tests were positive and lactose, citrate and urease tests were negative. At the same time, in order to verify the diagnosis, the BD Phoenix System (Becton Dickinson, USA) was applied to identify the bacteria. *C. indologenes* was identified as the causative microorganism. According to the minimum inhibitory concentration (MIC) values, *C. indologenes* was found to be susceptible to trimethoprim-sulfamethoxazole ( $\leq 1/19$  mg/ $\mu$ l), ciprofloxacin ( $\leq 0.5$  mg/ $\mu$ l) and levofloxacin ( $\leq 1$  mg/ $\mu$ l), while it was shown to be resistant to amikacin ( $> 32$  mg/ $\mu$ l), gentamicin ( $> 8$  mg/ $\mu$ l), imipenem ( $> 8$  mg/ $\mu$ l), meropenem ( $> 8$  mg/ $\mu$ l), ceftazidime ( $> 16$  mg/ $\mu$ l), cefepime ( $> 16$  mg/ $\mu$ l), aztreonam ( $> 16$  mg/ $\mu$ l), piperacillin/tazobactam ( $> 64/4$  mg/ $\mu$ l), and colistin ( $> 4$  mg/ $\mu$ l) (6).

After the patient was treated with a single daily dose of 500 mg levofloxacin over a period of three weeks, clinical improvement of the tracheobronchitis was observed.

## DISCUSSION

*Chryseobacterium indologenes*, which can be found in natural as well as in hospital environments, is a Gram-negative bacillus. It has rarely been isolated as an infectious agent in humans. However, in recent years, the incidence of *Chryseobacterium indologenes*-related infections has been increasing, particularly in immunosuppressed patients and in newborns (4). It may be the cause of bacteremia and pneumonia as well as peritonitis, meningitis, endocarditis, pyomyositis, keratitis and urinary system infections (4,7,8).

A review of the literature shows that *C. indologenes*-related pneumonia has been encountered in patients, but no cases have been determined in those with tracheobronchitis (2,3). *C. indologenes* was first clinically isolated in 1993 from deep tracheal aspirate (DTA) specimens of a patient with ventilator-associated pneumonia (2). Monteen et al. (3) report-

ed *C. indologenes* as a factor in ventilator-associated pneumonia in a critically injured patient. In Turkey, Feyzioğlu et al. (9) isolated *C. indologenes* from the DTA specimen of a patient under intensive care treatment for organophosphate poisoning, and Ceylan et al (4) reported a *C. indologenes*-related case of sepsis in a hydrocephalic patient. In this case, in a patient under immunosuppressive treatment following a liver transplant, tracheobronchitis occurred and *C. indologenes* was found growing in the culture from the bronchoalveolar lavage (BAL). Atypical findings of infections in immunosuppressed patients can generally be seen as insignificant, a situation which can be life-threatening to the patient (10). The reason why the present case did not develop fever or leukocytosis was attributed to the patient's suppressed immune system.

*Chryseobacterium*-type Gram-negative bacterial infections exhibit intrinsic resistance to the use of aminoglycoside, beta-lactam, tetracycline and chloramphenicol. However, Gram-positive bacteria are often susceptible to the use of rifampin, clindamycin, erythromycin, trimethoprim-sulfamethoxazole and vancomycin. The most suitable antibiotic group for treatment is known to be that of the quinolones. Because the disc diffusion method is not reliable in showing antimicrobial susceptibility, antimicrobial susceptibility of clinically significant strains should be determined by the minimum inhibitory concentration (MIC) test (1). In this case, the empirical treatment initiated with ampicillin/sulbactam was not the answer. The results of the culture revealed *C. indologenes* as susceptible to levofloxacin, and for this reason the patient's antibiotic was changed to levofloxacin and his treatment was successful.

Consequently, among the opportunistic infections that may arise in cases with underlying disease and especially in those with suppressed immune systems, *C. indologenes* is emerging with increasing frequency. *C. indologenes* must be considered as being among the treatment-resistant agents in lower respiratory infections in this group of patients, and as these infections affect morbidity, timely treatment must be provided.

## REFERENCES

1. Winn W, Allen S, Janda W, Koneman E, Procop G, Schreckenberger P, et al. Koneman's Color Atlas and Textbook of Diagnostic Microbiology. 6th ed. Philadelphia: Lippincott Williams and Wilkins; 2006.
2. Yasmin S, Garcia G, Sylvester T, Sunenshine R. *Chryseobacterium indologenes* in a woman with metastatic breast cancer in the United States of America: a case report. *J Med Case Rep.* 2013;7:190.
3. Monteen MR, Ponnappula S, Wood GC, Croce MA, Swanson JM, Boucher BA, et al. Treatment of *Chryseobacterium indologenes* ventilator-associated pneumonia in a critically ill trauma patient. *Ann Pharmacother.* 2013;47(12):1736–9.
4. Ceylan A, Gdcođlu H, Akbayram S, Bektař A, Beraktař M. Sepsis caused by *Chryseobacterium indologenes* in a patient with hydrocephalus. *Mikrobiyol Bul.* 2011;45(4):735–40.
5. Shahul HA, Manu MK, Mohapatra AK, Chawla K. *Chryseobacterium indologenes* pneumonia in a patient with non-Hodgkin's lymphoma. *BMJ Case Rep.* 2014; doi: 10.1136/bcr-2014-204590.
6. CLSI. Performance standards for antimicrobial susceptibility testing; Twenty-third informational supplement. CLSI document M100-S23. Wayne, PA: Clinical and Laboratory Standards Institute; 2013.
7. Çelik AD, Yuluđkural Z, Durmuř G, Kulođlu F, Saridođan K, Akata F. *Chryseobacterium indologenes*'in etken olduđu nozokomiyal septik artrit olgusu. *İnfeksiyon Derg.* 2009;23(3):133–5.
8. Cunha V, Ferreira M, Fonseca AG, Diogo J. Community-acquired *Chryseobacterium indologenes* in an immunocompetent patient. *JMM Case Rep.* 2014; doi: 10.1099/jmmcr.0.000588.
9. Feyziođlu B, zdemir M, Kutlu NO, Baykan M, Baysal B. Pulmonary infection caused by *Chryseobacterium indologenes* in a patient with a diagnosis of organophosphate poisoning. *Anatol J Clin Investig.* 2014;8(3):137–9.
10. zst H, Karadeniz A. What is immunosuppressive host? *J Int Med Sci.* 2007;3(46):1–20.