

## Submucosal Dermoid Cyst of The Rectum in an Adult Female (a case report)

### *Yetişkin Bayanda Rektumun Submukozal Dermoid Kisti (bir olgu sunumu)*

Sezgin YILMAZ<sup>1</sup>, Gülelül KÖKEN<sup>2</sup>, Serkan TÜREL<sup>1</sup>,  
Önder ŞAHİN<sup>3</sup>, Mehmet YILMAZER<sup>2</sup>

<sup>1</sup> Kocatepe Üniversitesi Tıp Fakültesi Genel Cerrahi AD., Afyonkarahisar

<sup>2</sup> Kocatepe Üniversitesi Tıp Fakültesi Kadın Hastalıkları ve Doğum AD, Afyonkarahisar

<sup>3</sup> Kocatepe Üniversitesi Tıp Fakültesi Patoloji AD, Afyonkarahisar

**ABSTRACT:** Dermoid cysts are rare developmental teratomatous lesions composed of ectodermally derived stratified squamous epithelium and mesodermally derived skin adnexal structures. Although several theories have been postulated, the pathogenesis of dermoid cysts and teratomatous lesions in general is unclear. Ovary is the most frequent affected organ, but it can occur in the mediastinum retroperitoneum, testis, and even in the liver. Presacral dermoid cyst accounts for small percentages of all dermoid cysts. These tumours may be totally asymptomatic and 15 percent of them are discovered incidentally on rectal and pelvic examination or on radiological evaluation. The treatment of rectal dermoid cyst is complete surgical removal. We present a case of dermoid cyst located at the submucosal layer of the posterior rectal wall. The patient presented in current paper was treated with complete submucosal cyst excision via transanal route and the mass was diagnosed as epidermoid type of dermoid cyst.

**Key Words:** Dermoid cyst, rectum, transanal approach, excision

**ÖZET:** Dermoid kistler nadir görülen gelişimsel teratomatöz lezyonlardır ve ektoderm kökenli çok katlı yassı epitel ve mesoderm kökenli cilt eklerini içerirler. Her ne kadar pek çok teori varsa da dermoid kistlerin ve teratomatöz lezyonların patogenezi genel olarak bilinmemektedir. Overler en sık tutulan organlar olmakla birlikte mediasten, retroperiton, testis ve hatta karaciğerde de hastalık görülebilir. Bu tümörler tamamen asemptomatik olabilirler ve %15'i tesadüfi olarak rektal ve pelvik muayenede veya radyolojik inceleme esnasında tespit edilirler. Rektal dermoid kistlerin tedavisi cerrahi olarak çıkarılmalarıdır. Bu yazıda posterior rektal duvarda submukozal tabakada yerleşmiş bulunan dermoid kist olgusunu sunduk. Hasta trans-anal yaklaşımla submukozal yerleşimli kist tam olarak eksize edilerek tedavi edilmiş ve postoperatif tanısı da epidermoid tip dermoid kist olarak gelmiştir.

**Anahtar Sözcükler:** Dermoid kist, rectum, transanal yaklaşım, eksizyon

### INTRODUCTION

Tumors arising in the presacral area are uncommon and account for about 1 in 10000 hospital admissions. The incidence of teratoma among presacral tumors is between 9 and 12 percent. Dermoid cysts are benign cystic teratomas lined by skin and epidermal appendages. They occur mostly in infants and newborns and only 10 percent of patients are adults and eighty percent of them are females (1).

Dermoid cyst is a cyst of developmental origin and histologically characterized with squamous cell lining, keratinoid or mucoid content, occasionally associated with fatty component and calcified structure (2). Ovary is the most frequent affected organ, but it can occur in the mediastinum retroperitoneum, testis, and even in the liver. Dermoid cyst is distinguished from teratoma that is composed of tissues from all three germ layers.

Presacral dermoid cyst accounts for small percentages of all dermoid cysts, arising from remnants of the embryonal urogenital apparatus, which includes both epithelial and mesothelial origin (3). Although the treatment of presacral dermoid cyst is complete surgical removal it is rare for a

rectal dermoid cyst to be large enough to necessitate a laparotomy for its removal.

Primary rectal dermoid cyst is very rare and only a few cases have been reported in literature. So in the current we report a case of dermoid cyst located at the presacral space and reviewed the literature.

### CASE

A 35 years old female married for 9 years was admitted to our clinic for primary infertility. The previous treatments for infertility were ovulation induction with clomiphene citrate (6 times) and human menopausal gonadotrophins (4 times) followed by intrauterine insemination. Since these modalities failed invitro fertilization was applied to the patient and resulted in single pregnancy. Unfortunately this pregnancy has resulted in abortus at seven weeks. The diagnostic laparoscopy and hysteroscopy revealed any pathology. The past history of patient was uneventful.

The gynecological examination of patient revealed a 3X4 cm sized semi solid mass with a smooth surfaces located at posterior fornix. The cervix, ovaries and uterus were normal. On rectal evaluation there was a 3X4 cm sized smooth surfaced semi solid mass at 8cm of posterior rectum. On gynecological ultrasound the uterus was 58x36x40 mm in size and in antevert position, myometrium was homogenous, endometrium was 5mm/2 regular and both ovaries were in normal follicular pattern. However there was a 35X22 mm sized smooth mass located at posterior part of rectum (fig 1, 2). The tumor markers including CEA, AFP, CA125, CA199, CA 15-3 were in normal range. The biochemical and blood parameters were also normal. The computerized tomography of patient revealed a 3X3 cm smooth round mass embedded in the perirectal fatty tissue. It was located at posterior part of cervix and left lateral side of the posterior rectum.

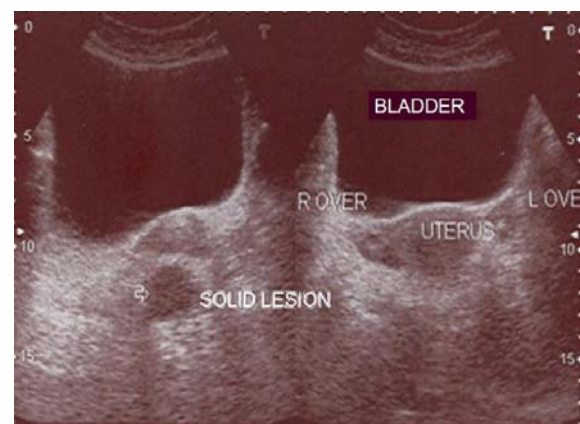
The patient has been consulted to General Surgery Department with the diagnosis of the retrorectal mass. Following the general anaesthesia gynecological position was applied to patient and an anoscope was placed through rectum. A rectal mass measuring about 3X3 cm was palpated on posterior rectum. It was a submucosally located smooth mass. The overlying rectal mucosa was incised and a flap was performed over the mass. The mass was excised from the underlying muscular tissue following the circumferential blunt and sharp

dissections. However the mass was ruptured at the end of the dissection and cyst content containing muddy material was observed. The cyst content and capsule was removed completely. The histopathological diagnosis was obtained as dermoid cyst at the operation after frozen section. The operation area was irrigated with saline vigorously and overlying rectal mucosa was sutured with interrupted 3/0 vicryl sutures. The postoperative course of the patient was uneventful and the patient was discharged on the 2nd postoperative day.

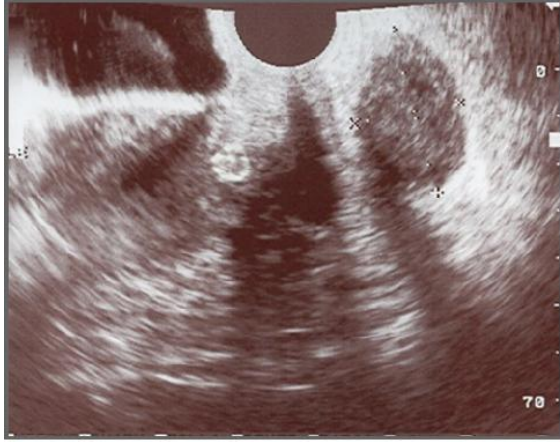Macroscopically, the specimen was 5X2X1 cm dark grey colored cystic mass. There were white cheesy tissue fragments measuring in 1.5 cm in largest inside of the cyst. The surface of the mass was rather smooth. When the cross-section of the mass was cut, it was observed that the lumen was filled with white cheesy material, and the inner lining was smooth and glistening

Microscopically, the section consisted of stratified squamous cell epithelium with considerable piling of keratin into the lumen. The underlying connective tissue was dense and contained blood vessels, fibrous tissue, and inflammatory cells (fig 3). Based on these findings, the tumor was determined as a dermoid cyst (epidermoid type).

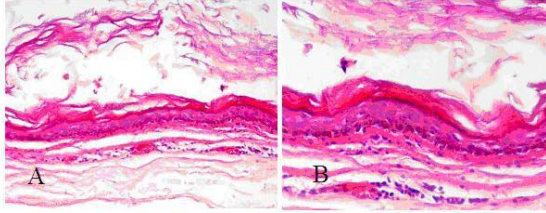
No complication observed during patient follow-up. Three months after the operation, in-vitro fertilization has been applied to the patient and than singleton pregnancy has been obtained. A healthy female baby has been delivered at 39 week cesarean section.



**Picture 1.** The transabdominal ultrasonographic view of the mass located at posterior to rectum.



**Picture 2.** The transvaginal ultrasonographic view of the mass located at posterior to rectum.



**Picture 3.** The photograph showing the section consisted of stratified squamous cell epithelium with considerable piling of keratin into the lumen. The underlying connective tissue was dense and contained blood vessels, fibrous tissue and inflammatory cells H&E (A:200 $\mu$  - B:400 $\mu$ )

### DISCUSSION

Dermoid cysts are rare developmental lesions containing elements from the ectoderm and mesoderm. As a part of the teratomatous neoplasm group, dermoid cysts are thought to arise from embryologic stem cell rest that is able to develop into the tissues of all three germ layers.

Histological characteristics are stratified squamous lining, keratinoid or mucoid content, fatty component and calcified epithelial derivative such as teeth (2).

Dermoid cysts are histopathologically classified in to three types of epidermoid, dermoid, and teratoid. The epidermoid type is lined with simple squamous epithelium and surrounding connective tissue. Dermoid cyst presented in current paper was pathologically classified as an epidermoid type. The dermoid type is an epithelium-lined cyst that contains skin appendages. The teratoid type is also

epithelium-lined, and it contains mesodermal or endodermal elements such as muscle, bone, teeth and mucous membranes (4).

Dermoid cysts can be found throughout the patient's body. These tumours may be totally asymptomatic and 15 percent of them are discovered incidentally on rectal and pelvic examination or on radiology (1). The presentations of dermoid cysts are different depending on the localization. The abscess formation in the cystic may be misdiagnosed as high lying pararectal abscesses (5). There may be gynecological problems that may be attributed to the cyst or not and the cyst is diagnosed during the routine check up (6). Due to their size, they may cause pelvic discomfort or bladder symptoms. On physical examination, the most constant finding is a mass ventral to the sacrum. In our case, rectal examination revealed an extraluminal, smooth and non tender spherical mass. Anal sphincter tone was normal and rectal mucosa was intact. On ultrasonography the mass was partly solid and cystic.

Differential diagnoses of presacral dermoid cyst include tailgut cyst, epidermoid cyst, lymphangioma, rectal duplication, anal gland cyst, neurenteric cyst. Tailgut cysts are multiloculated, hamartomatous cyst, lined by squamous, columnar, transitional epithelium. The content is serous to mucoid, and lacks fatty component. Epidermoid cyst contains keratinoid substance, lined by squamous epithelia, and, therefore diffusion-weight MR image may not distinguish epidermoid cysts from dermoid cysts. However, epidermoid cyst also lacks fat, calcification and dermal appendages, as well. Lymphangioma is usually a mono or multiloculated cystic tumor containing serous fluid. Duplication cyst and anal gland cyst are both serous cyst, lined by columnar/cuboidal and squamous epithelium respectively. A neurenteric cyst may communicate with subarachnoid space. Low value of possibility of later four entities, and the presence of small amount of fat as suggested by chemical shift imaging may preclude tail gut cyst and epidermoid cyst.

The treatment of presacral teratoma is complete surgical removal. Retrorectal tumors have been previously resected by a posterior trans or parasacral approach, while the anterior abdominal approach is generally reserved for small tumors situated above the sacral promontory (7). For small tumours, a posterior trans-sacral approach similar to Kraske approach to the rectum with the patient in prone position has been quite popular (8). Removal of the coccyx has been emphasized to reduce the chance of

recurrence. It is rare for a presacral teratoma to be large enough to necessitate a laparotomy for its removal (1). Removal of a low lying presacral tumour by a vaginal incision has been reported in females. The anterior abdominal approach allows the complete resection of a retrorectal large tumor mass, and provides an interesting alternative to the posterior approach with low morbidity and an absence of functional impairment (6). In cases presented as polypoid lesion, endoscopic polypectomy may be valuable to excise the cyst (9). In our case, trans anal approach was adequate to excise the cyst following the creation of rectal mucosal flap. We have not observed any technique related complication such as perirectal infection, abscess, fistula and incontinence. It may be recommended for low lying rectal lesions since it has low morbidity and excellent postoperative course according to the other approaches.

#### REFERENCES

1. Kripalani AK, Sharma LK. Large pre-sacral teratoma in an adult male (a case report). *J Postgrad Med.* 1986; 32: 231-232
2. Outwater EK, Siegelman ES, Hunt JL. Ovarian Teratomas: Tumor types and imaging characteristics. *Radiographics.* 2001; 21: 475-490.
3. Sharpe LA, Van Oppen DJA. Laparoscopic removal of a benign pelvic retroperitoneal dermoid cyst. *J Am Assoc Gynecol Laparosc.* 1995; 2(2): 223-6.
4. Meyer I. Dermoid cysts of the floor of the mouth. *Oral Surg.* 1955; 8: 1149-1164.
5. Saygun O, Avsar FM, Topaloglu S, Yuksel BC, Ozel H, Ustun H, et al. Retrorectal benign cystic teratoma misdiagnosed with high lying pararectal abscess. *Hepatogastroenterology.* 2003; 50 Suppl 2: cclii-ccliii.
6. Sakurai Y, Uruguchi T, Imazu H, Hasegawa S, Matsubara T, Ochiai M et al. Submucosal dermoid cyst of the rectum: report of a case. *Surg Today.* 2000; 2: 195-198
7. Guillem P, Ernst O, Herjean M, Triboulet JP. Retrorectal tumors: an assessment of the abdominal approach. *Ann Chir.* 2001; 126(2): 138-142.
8. Kanemitsu T, Kojima T, Yamamoto S, Koike A, Takeshige K, Naruse T. The trans-sphincteric and trans-sacral approaches for the surgical excision of rectal and presacral lesions. *Surg Today.* 1993; 10: 860-866.
9. Tabuchi Y, Tsunemi K, Matsuda T. Variant type of teratoma appearing as a primary solid dermoid tumor in the rectum : report of a case. *Surg Today.* 1995; 1: 68-71.