

**LETTER TO  
EDITOR**

-  **Abdullah Demirbas<sup>1</sup>**  
 **Omer Faruk Elmas<sup>2</sup>**  
 **Mustafa Atasoy<sup>3</sup>**  
 **Gozde Ulutas Demirbas<sup>4</sup>**  
 **Umit Tursen<sup>5</sup>**  
 **Torello Lotti<sup>6</sup>**  
 **Asuman Kilitci<sup>7</sup>**

<sup>1</sup>Kütahya Health Sciences University, Evliya Çelebi Training and Research Hospital, Department of Dermatology, Kütahya, Turkey

<sup>2</sup>Kırıkkale University, Faculty of Medicine, Department of Dermatology, Kırıkkale, Turkey

<sup>3</sup>Health Science University, Kayseri City Hospital, Department of Dermatology, Kayseri, Turkey

<sup>4</sup>Akçaabat Haçkalı Baba State Hospital, Department of Dermatology, Trabzon, Turkey

<sup>5</sup>Mersin University, Faculty of Medicine, Department of Dermatology, Mersin, Turkey

<sup>6</sup>Guglielmo Marconi University, Department of Dermatology, Rome, Italy

<sup>7</sup>Kırşehir Ahi Evran University, Faculty of Medicine, Department of Pathology, Kırşehir, Turkey

**Corresponding Author:**

Asuman Kilitci

Kırşehir Ahi Evran University Faculty of Medicine, Department of Pathology, Kırşehir, Turkey

mail: dr.asuk@gmail.com

Phone: +90 5079553256

Received: 16.03.2021

Acceptance: 26.06.2021

DOI: 10.18521/kt.896761

**Konuralp Medical Journal**

e-ISSN1309-3878

konuralptipdergi@duzce.edu.tr

konuralptipdergisi@gmail.com

www.konuralptipdergi.duzce.edu.tr

## **A Case of COVID-19 in a Patient with Pemphigus Successfully Managed with Favipiravir**

### **ABSTRACT**

COVID-19 is not only a respiratory disease, but a multisystem disease that can cause organ dysfunction and coagulation disorder associated with high mortality and morbidity, particularly in vulnerable populations. Severe complications can be seen especially in elderly patients with systemic disease and immunosuppressive patients. We present the case of COVID-19 that developed in a 38-year-old female patient with pemphigus successfully managed with favipiravir.

**Keywords:** COVID-19, Pemphigus, Favipiravir

## **Favipiravir ile Başarılı Şekilde Tedavi Edilen Pemfiguslu bir COVID-19 Vakası**

### **ÖZET**

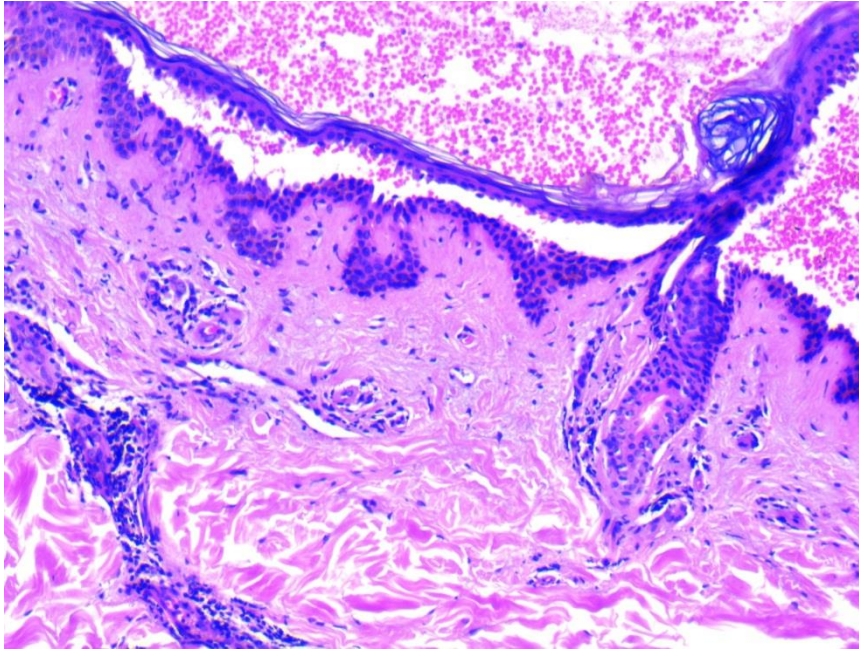
COVID-19 sadece bir solunum hastalığı değil, aynı zamanda özellikle hassas popülasyonda yüksek mortalite ve morbidite ile ilişkili organ disfonksiyonuna ve pıhtılaşma bozukluğuna neden olabilen multisistemik bir hastalıktır. Özellikle sistemik hastalığı olan yaşlı hastalarda ve immünsüpresif hastalarda ciddi komplikasyonlar görülebilmektedir. Favipiravir ile başarılı bir şekilde tedavi edilen pemfiguslu 38 yaşındaki bir kadın hastada gelişen COVID-19 vakasını sunuyoruz.

**Anahtar Kelimeler:** COVID-19, Pemfigus, Favipiravir

Dear Editor,

Coronavirus disease 2019 (COVID-19) is a multisystemic infectious disease caused by severe acute respiratory syndrome coronavirus 2 (SARS-CoV-2) (1,2). COVID-19 has caused many social, cultural, and economic problems since declared as a pandemic by the World Health Organization and caused disruptions in health activities. The management of cutaneous diseases, including

pemphigus, has also been affected from the difficulties and disruptions caused by the pandemic (2,3). A 38-year-old female presented with cough and loss of taste and smell. She was followed up with the diagnosis of pemphigus vulgaris that confirmed by histomorphologic and immunofluorescence findings three years before (Fig. 1). She had no further disease.



**Figure 1.** Cutaneous biopsy specimen showed suprabasal intraepidermal acantholysis (H&E,  $\times 100$ ).

She was in remission with 1500 mg/day mycophenolate mofetile and 2 mg oral methylprednisolone. The nasopharyngeal swab test for SARS-CoV-2 turned out to be positive while laboratory investigation including complete blood count, ferritin, acute phase reactants, d-dimer, fibrinogen, liver and renal function tests were within normal limits. Mycophenolate mofetil treatment was discontinued immediately and favipiravir was started (1st day at loading dose 2x800 mg; 2-5th day at maintaining dose 2x300 mg). In addition, the dose of oral methylprednisolone treatment was increased to 10 mg/day. Oral methylprednisolone dose was increased to 18 mg after 1 week following the diagnosis of COVID-19 due to few superficial erosive foci appeared in the oral mucosa. Symptoms related to COVID-19 were completely disappeared after 15 days following the diagnosis. The dose of methylprednisolone was gradually reduced to 2 mg within four week and mycophenolate mofetil treatment was restarted. No recurrence was observed in the following 3 months.

COVID-19 is considered not only a respiratory disease but a multisystemic disorder associated with a significant mortality and morbidity rates, particularly in vulnerable population. The main risk factors for mortality and

morbidity includes advanced age, comorbidities and immunosuppressive conditions. Pemphigus vulgaris is a life-threatening autoimmune bullous disease with mucocutaneous involvement that usually requires immunosuppressive therapy (4,5,6).

Some authors suggested that, in patients with pemphigus immunosuppressive treatment should be suspended until sign and symptoms related to COVID-19 is regressed, while others recommended that immunosuppressive medications should only be discontinued in confirmed cases of SARS-CoV-2 infections (3).

Systemic corticosteroids are generally considered the mainstay therapy in pemphigus. Although corticosteroids have positively changed the course of pemphigus, their adverse effects including susceptibility to serious infections, has become more pronounced with the COVID-19 pandemic. It has been recently suggested that COVID-19 causes excessive production of pro-inflammatory mediators causing exaggerated inflammatory tissue response, which is considered to be associated with increased mortality and morbidity. Despite the concerns that corticosteroids may vitiate viral clearance, a low to medium dose of systemic corticosteroids seem to have a significant role in the management of severe COVID-19 cases. In their expert consensus,

Kasperkiewicz et al suggested that 10 mg or lower daily doses of prednisolone can be maintained in patients with pemphigus, while doses higher than 10 mg/day should be decreased considering the activity of the disease, accompanying systemic diseases, and severity of the infection (7).

The relevant guide published by the European Academy of Dermatology and Venereology Task Force Autoimmune Blistering Diseases also recommended to discuss reducing the dose of systemic corticosteroids for pemphigus patients with COVID-19 (8).

Favipiravir, a purine nucleoside analogue, was identified to have in vitro antiviral activity against SARS-CoV-2 (9,10).

It is one of the proposed antiviral drugs for COVID-19 but no study focused on the efficacy of favipiravir alone for the treatment of COVID-19. Although there was no robust evidence, some studies showed positive effects on disease progression and viral clearance in patients with COVID-19. The side effects reported were mainly mild and manageable (11).

To conclude, low-dose methylprednisolone and favipiravir combination may offer a safe and successful management for COVID-19 in patients with pemphigus. It is clear that, however, more reports are needed to demonstrate the efficacy and safety of this combination.

## REFERENCES

1. Demirbaş A, Elmas ÖF, Türsen Ü, Atasoy M, Lotti T. Superficial thrombophlebitis in a patient with COVID 19: Heparin treatment after evaluation of D-Dimer. *Dermatol Ther.* 2020;33(4): e13768.
2. Beyazçiçek Ö, Beyazçiçek E, Demir S. Are Blood Groups Protective Against COVID-19?. *Konuralp Med J.* 2021;13(1): 160-7.
3. Elmas ÖF, Demirbaş A, Türsen Ü, Atasoy M, Lotti T. Pemphigus and COVID-19: Critical overview of management with a focus on treatment choice. *Dermatol Ther.* 2020: e14265.
4. Shakshouk H, Daneshpazhooch M, Murrell DF, Lehman JS. Treatment considerations for patients with pemphigus during the COVID-19 pandemic. *J Am Acad Dermatol.* 2020;82(6): e235-e236.
5. Schmidt E. Rituximab as first-line treatment of pemphigus. *Lancet.* 2017;389(10083): 1956-8.
6. Karabay O, İnci M, Öğütü A, Ekerbiçer H, Güçlü E, Dheir H, et al. Is it possible to predict mortality using initial data of adult patients hospitalized with COVID-19? A mortality prediction model in the early phase of COVID-19. *Konuralp Med J.* 2021;13(1): 36-44.
7. Kasperkiewicz M, Schmidt E, Fairley JA, Joly P, Payne AS, Yale ML, et al. Expert recommendations for the management of autoimmune bullous diseases during the COVID-19 pandemic. *J Eur Acad Dermatol Venereol.* 2020;34(7): e302-e303.
8. Guidance from the EADV Task Force Autoimmune Blistering Diseases during the COVID-19 pandemic. The EADV Task force Autoimmune Blistering Diseases supports patients and their families during this difficult period of COVID-19 pandemic and provides the following advices. 2020.
9. Coomes EA, Haghbayan H. Favipiravir, an antiviral for COVID-19?. *J Antimicrob Chemother.* 2020;75(7): 2013-4.
10. Dheir H, Yaylacı S, Sipahi S, Şenocak D, Toptan H, Aşıcı N, et al. The effectiveness of favipiravir treatment in severe COVID-19 pneumonia: A single center experience. *Konuralp Med J.* 2021; 13(1): 4-10.
11. Nasir M, Perveen RA, Saha SK, Talha KA, Selina F, Islam MA. Systematic Review on Repurposing Use of Favipiravir Against SARS-CoV-2. *Mymensingh Med J.* 2020;29(3): 747-54.