

Hemangioma: Case Report of A Lesion of The Mid-Face Focusing Upon Imaging Findings

Filiz Namdar Pekiner¹, Nihat Kodallı², Sinan Horasan³

¹Department of Oral Diagnosis and Radiology Marmara University Faculty of Dentistry, Istanbul-Turkey

²Department of Radiology Marmara University Faculty of Medicine, Istanbul-Turkey

³Teknodent, Istanbul-Turkey

Yazışma Adresi / Address reprint requests to: Filiz Namdar Pekiner

Marmara University Faculty of Dentistry, Department of Oral Diagnosis and Radiology, Güzelbahçe Büyükciftlik Sok. No: 6 34365 Nişantaşı-Istanbul

Telefon / Phone: +90-212-231-9120/120 Faks / Fax: +90-212-246-5247 Elektronik posta adresi / E-mail address: fpekiner@yahoo.com

Kabul tarihi / Date of acceptance: 13 Ekim 2011 / October 13, 2011

ÖZET

Hemanjiom: Orta -yüz bölgesinde yer alan lezyonun görüntüleme bulgularının değerlendirildiği olgu sunumu

Bu makalede; 43 yaşında bir kadın hastada, maksilla ve üst dudak derisi ile sol burun kanadını da tutan subkutanöz geniş yayımlı hemanjiom olgusu sunulmaktadır. Hastanın protetik restorasyonunun yapılabilmesi amacıyla magnetic rezonans görüntüleme (MRG) ve bilgisayarlı tomografi (BT) ile lezyonun komşu dokularla ilişkisi değerlendirilmiştir. Görüntüleme bulguları, lezyonun vasküler kaynaklı bir yapı içerdiğini ve sol maksilla anterior duvarında deformiteye neden olduğunu göstermiştir. Bu bulgular ışığında, hastaya uygulanabilirliği mümkün olan protetik restorasyon üç boyutlu görüntüleme ile de değerlendirilerek konsülte edilmiştir.

Anahtar sözcükler: Bilgisayarlı tomografi, konik ışınli hacimsel tomografi, hemanjiom, magnetic rezonans görüntüleme, subkutanöz

ABSTRACT

Hemangioma: case report of a lesion of the mid-face focusing upon imaging findings

A 43-year-old female patient with an extensive subcutaneous hemangioma in the body of the maxilla was presented. In addition, skin of the upper lip and left lateral aspect of nose appeared to be involved. However, patient was in need of prosthetic restoration. Therefore, the lesion was evaluated by magnetic resonance imaging (MRI) and computed tomography (CT). Imaging findings showed that the lesion was a mass including vascular structure and there was a deformity in the left anterior maxillary wall because of this lesion. For consultation regarding prosthetic restoration, three-dimensional reconstruction was performed.

Key words: Computed tomography, cone beam computed tomography, hemangioma, magnetic resonance imaging, subcutaneous

INTRODUCTION

The term hemangioma has traditionally been used to describe a variety of developmental vascular anomalies. Hemangiomas are benign, enlarged, vascular hamartomas that may be seen in any soft tissue or bony intra-oral location. They occur early in life and somewhat more commonly in women than in men (1,2).

Soft tissue hemangiomas occur commonly in the dorsum of the tongue, gingiva and buccal mucosa. Vascular lesions of the face are not very common. These lesions are a perplexing group of problems that over the years have generated a significant debate and confusion as regards their terminology and classification. Descriptive anatomic, pathologic and embriologic classification scheme have been devised however generally have not offered the clinician significant guidance for treatment. The

classification developed by Mulliken and Glowacki in 1982 is based on the cellular kinetics of anomalous vessels, providing a diagnostic and therapeutic approach based on the biologic behaviour of the lesion. In this classification, two entities exist: 1) hemangiomas and 2) vascular malformations (1,2).

Hemangiomas are considered to be benign tumors of infancy that are characterized by a rapid growth phase with endothelial cell proliferation. On the other hand, vascular malformations are structural anomalies of blood vessels without endothelial proliferation (1-3).

In this study, we present a 43-year-old female patient who revealed extensive spreading hemangioma from body of the maxilla to left lateral aspect of the nose and clarify the lesion by magnetic resonance imaging (MRI), computed tomography (CT) and cone beam computed tomography (CBCT).

CASE REPORT

Clinical Findings

A 43-year-old female patient with an edentulous maxilla in need of prosthetic treatment was referred to the clinic of Department of Oral Diagnosis and Radiology, Faculty of Dentistry, Marmara University, Istanbul. The lesion appeared to involve the skin of the upper lip and left side of lateral aspect of the nose (Fig 1a and b). Intra-oral examination revealed spreading red-blue-violet protuberances at palate region and right side of the tongue surface (Fig 1c and d). This area blanched on pressure but was without any pulsations. The overall appearance of the lesion gave a clinical impression of vascular malformation in the body of the maxilla.

Imaging Findings

MRI (1.5 T Signa Horizon, USA) was the first radiographic examination choice (Axial T1-weighted spin echo images were obtained with the following variables: TR=350, TE=9, 256x160, 2NEX, 4mm slice thickness. Fat sat T2-weighted

images were obtained with the following variables: TR=3600, TE=88, 256x160, 3NEX, 4mm slice thickness. Contrast enhanced fat sat T1-weighted images were obtained with the following variables: TR=350, TE=9, 256x160, 2NEX, 4mm slice thickness). On MRI, an inhomogenous hyperintense lesion was seen beginning from left lateral aspect of the nose extending through subcutaneous soft tissue and left side of the palate (Fig 2). On T1-weighted MRI of the lesion, there was of low signal intensity. On T2-weighted images with the fat suppression technique, tumors tended to show higher signal intensity compared to surrounding tissues. There were tubular structures with flow signal void areas characteristic for vascular structures and linear septa (Fig 3). After contrast enhanced fat saturated T1-weighted axial image (20 cc Gd-DTPA, Magnevist, Schering, Germany) media application, there was a strong enhancement within the lesion (Fig 4). According to MRI, this lesion was a mass including vascular structure and the lesion extended towards subcutaneous soft tissue and to the left side of the palate. The area was examined with CT imaging to evaluate any bone involvement. CT imaging (GE Medical System, High Speed, Milwaukee, WI, USA) showed a hypodense soft

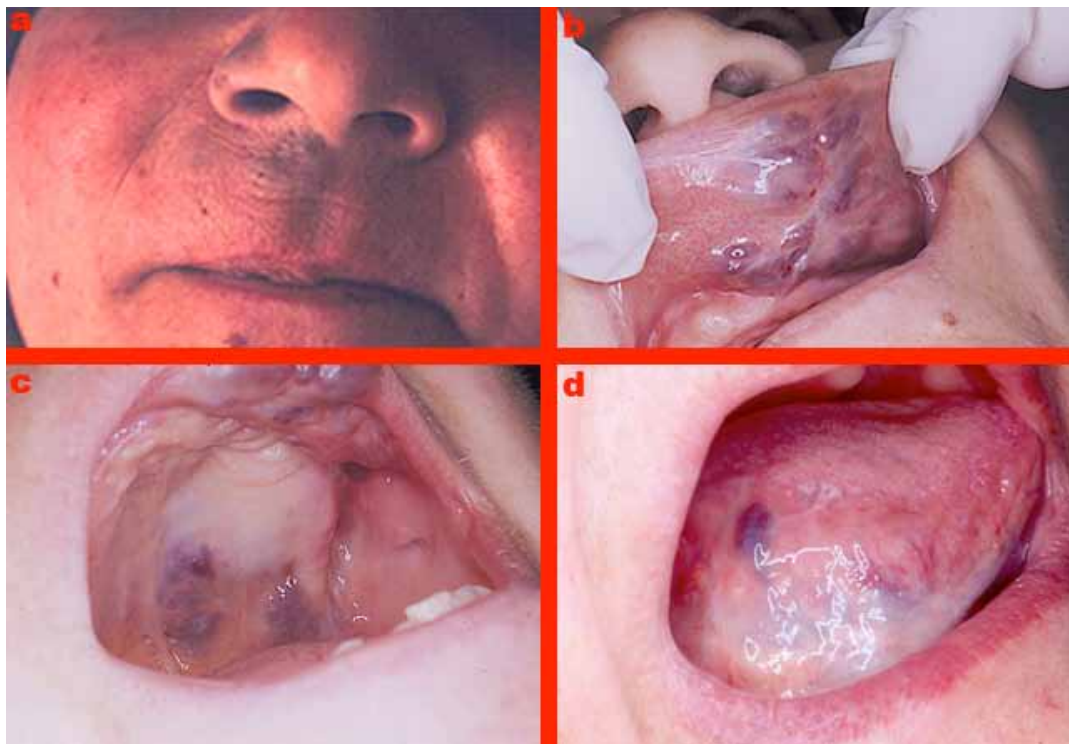


Figure 1: The bluish lesion spreading from left lateral aspect of the nose (a) upper lip (b) to palate region (c) and right side of the tongue (d) in the oral cavity.

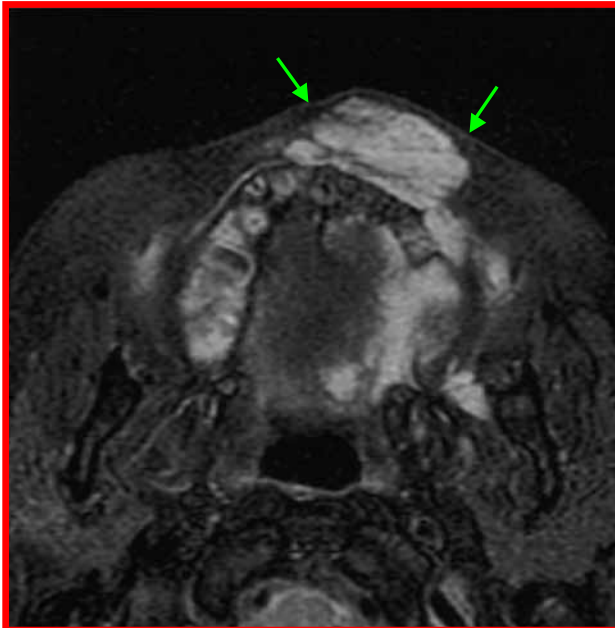


Figure 2: On fat saturated T2W axial MR images, an inhomogenous hyperintense lesion is seen beginning from left lateral aspect of the nose extending through subcutaneous soft tissue and left side of the palate (arrow).

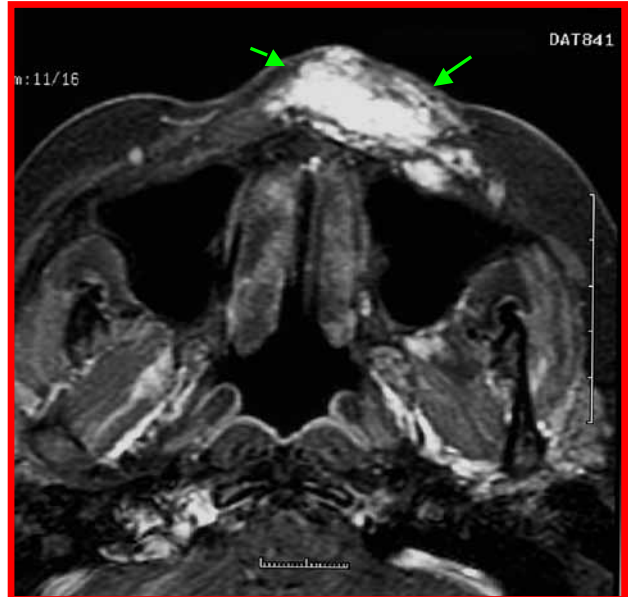


Figure 4: On contrast enhanced fat saturated T1W axial image as strong inhomogenous contrast enhancement is seen in the lesion (arrow).

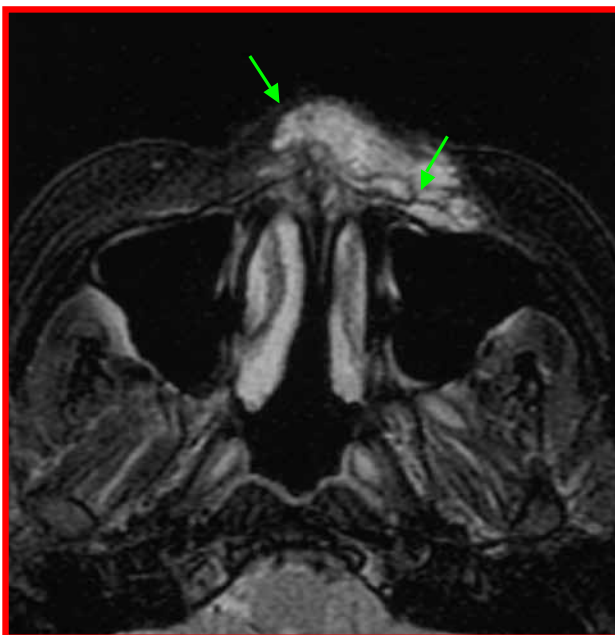


Figure 3: The linear hypointense structures which is compatible with fibrous septa (arrow).

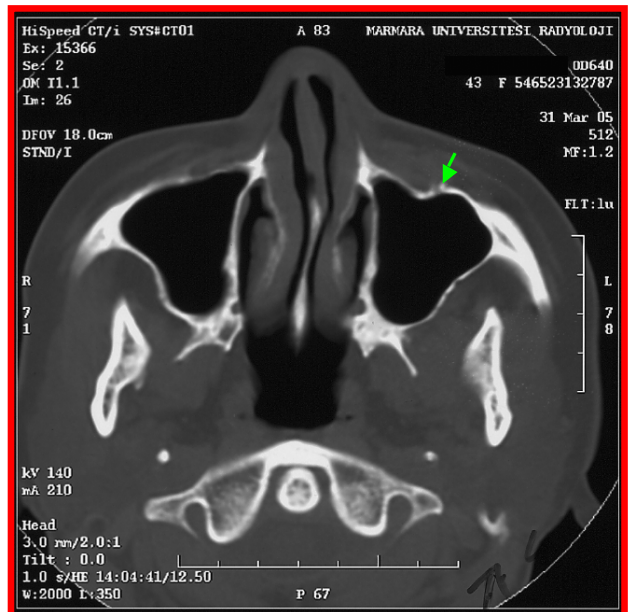

Figure 5: There is deformity of the left anterior maxillary wall on axial CT image (arrow).

tissue mass beginning from left lateral aspect of the nose, extending towards the palate and deformity on the left anterior maxillary wall (Fig 5). Due to the presence of hemangioma, prosthetic replacement with a maxillary

complete denture was risked and the most suitable restorative treatment choice was considered to be implants.

Many and varied reconstructions could be carried out using CBCT (NewTom 3G NNT Software, Mod.QR-DVT 9000, Verona, Italy). This reconstruction showed compressed bony defects probably caused by the tumor in the left




Figure 6: 3D CT radiograph of the maxilla illustrating the anterior wall.

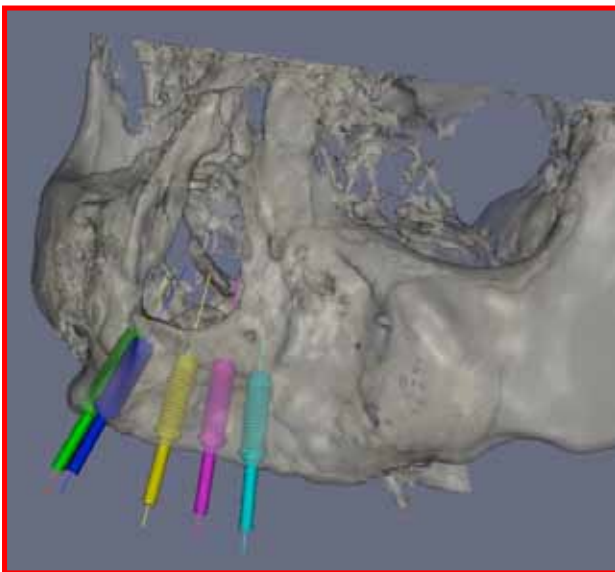


Figure 7: Three-dimensional reconstruction was performed for a consultation regarding dental implants.

anterior maxillary wall (Fig 6). In addition, three-dimensional reconstruction was performed for consultation regarding dental implants (Fig 7).

DISCUSSION

Hemangiomas are the most common tumors of infancy, occurring in 5% to 10% of 1-year-old children. They are much more common in females than males. The most common location is the head and neck region, which

accounts for 60% of all cases. Eighty percent of hemangiomas occur as single lesions, but 20% of affected patients will have multiple tumors. Hemangiomas of the oral mucosa may be flat or raised, often multinodular, and distinctly reddish, blue, or purple (4,5).

The diagnosis of hemangioma is based on clinical history and physical examination. Imaging studies may be necessary to clarify and confirm the diagnosis, and in order to analyze the extent of the lesions by permitting an evaluation of their non-visible component as well as the affection of neighbouring structures. The imaging techniques employed for hemangiomas include MRI, CT, CT with contrast media, ultrasonography and angiographic techniques (arteriography, phlebography) (6-13).

The standard imaging technique for evaluation of soft-tissue hemangiomas is MRI (11). MRI is becoming an important modality in the evaluation of soft tissue masses because of its superior soft tissue contrast resolution without the use of contrast materials and its ability to provide direct sagittal and coronal images, although bone destruction is more difficult to see (7,14-16). Most hemangiomas have typical MR appearance of low signal intensity (similar to that of muscle) on T1-weighted images and high signal intensity (greater than that of subcutaneous fat) on T2-weighted images, which reflects the preponderance of fluid-filled cystic spaces (17). Yonetsu et al. (8) suggested that MRI should be the first choice in detecting soft tissue masses including hemangiomas of oral and maxillofacial region. MRI can significantly contribute to the preoperative diagnosis of these masses and also can supply valuable information about the extent of the lesion.

In the present study, MRI of the lesion displayed a soft tissue mass with a similar signal to adjacent muscle on T1-weighted images and a very high signal on T2-weighted images. Therefore, this lesion was evaluated to be a subcutaneous hemangioma by the radiologist.

CT may not be specific for these tumors and does not always provide sufficient information about the extent of the hemangiomas (8,17). On non-contrast-enhanced CT the density of hemangiomas is similar to that of muscle and other soft tissues, while on contrast-enhanced CT hemangiomas do not always enhance adequately to show sufficient contrast between lesions and muscles (5,7,8,18). If large enough, they may manifest as smooth, palpable soft-tissue masses and in close proximity to adjacent bone,

osseous changes (5,19-23). In some cases, pressure erosion from the adjacent mass can result in a pathologic fracture (5). In our case, the CT presentation showed deformity of the left anterior maxillary wall.

CBCT systems have been designed for imaging hard tissues of the maxillofacial region. CBCT is capable of providing sub-millimetre resolution in images of high diagnostic quality, with short scanning times (10-70 seconds) and radiation dosages reportedly up to 15 times lower than those of conventional CT scans. When compared to conventional medical CT scanners; CBCT is more accurate, requires less radiation, captures the maxilla and mandible in a single rotation of the X-ray source, and is cost-effective for patients. Increasing availability of this technology provides the dental clinician with an imaging modality capable of providing a 3-dimensional representation of the maxillofacial skeleton with minimal distortion. When combined with application-specific software tools, CBCT can provide dentomaxillofacial practitioners with a complete solution for performing specific diagnostic and surgical tasks, such as dental implant planning, and radiographic information, as far as depth and proximity to critical anatomic landmarks (24-30).

Therefore, extensive subcutaneous hemangioma is clarified by 3-D volumetric imaging for prosthodontic restoration.

CONCLUSION

Clinical and MRI findings suggest diagnosis of extensive subcutaneous hemangioma. CT can show the tumour tissue breaking through the wall of the left maxilla which can not be visualized in MRI, but the MRI was superior to CT in showing the interface between hemangioma and neighbouring structures. However, CBCT allows 3-D imaging similar to CT, but at lower equipment cost, simpler image acquisition and lower patient radiation dose. Therefore, in this study the combination of MRI and CBCT is shown to facilitate the diagnosis and identification of the localization of extensive subcutaneous hemangioma and guide the dentists for prosthetic restorations.

Acknowledgements

This article was presented in the 10th European Congress of Dentomaxillofacial Radiology on May 31-June 3 2006, Leuven, Belgium.

REFERENCES

- Patel SB, Desai A, Desai S, Vyas RR, Soni HC. Case Report: Vascular lesions of face. *Ind J Radiol Imag.* 2003; 13: 257-260.
- Regezi JA, Sciubba JJ, Jordan RCK (ed): *Oral pathology: Clinical pathologic correlations*, 4th edn. St Louis: W.B. Saunders, 2003; pp 111-112.
- Wu JH, Du JK, Lu PC, Chen CM. Interdisciplinary management of mandibular intraosseous haemangioma. *Br J Oral Maxillofac Surg.* 2011; 49:e55-57.
- Neville BW, Damm DD, Allen CM, Bouquot JE (ed): *Oral & maxillofacial pathology*, 2nd edn. Philadelphia: W.B. Saunders, 2002, pp 467-468.
- Olsen KI, Stacy GS, Montag A. Soft-tissue cavernous hemangioma. *RadioGraphics.* 2004; 24: 849-854.
- Martinez de la Cuesta A. Imaging studies in the diagnosis of haemangiomas and vascular malformations. *An Sist Sanit Navar.* 2004; 27: 71-80.
- Kakimoto N, Tanimoto K, Nishiyama H, Murakami S, Furukawa S, Kreiborg S. CT and MR imaging features of oral and maxillofacial hemangioma and vascular malformation. *Eur J Radiol.* 2005; 55: 108-112.
- Yonetsu K, Nakayama E, Miwa K, Tanaka T, Kazuyuki A, Kanda S, et al: Magnetic resonance imaging of oral and maxillofacial angiomas. *Oral Surg Oral Med Oral Pathol.* 1993; 76: 783-789.
- Kaplan PA, Willams SM. Mucocutaneous and peripheral soft-tissue hemangiomas: MR imaging. *Radiology* 1987; 163: 163-166.
- Levine E, Wetzel LH, Neff JR. MR imaging and CT of extra-hepatic cavernous hemangiomas. *AJR Am J Roentgenol.* 1986; 147: 1299-1304.
- Paltiel HJ, Burrows PE, Kozakewich HPW, Zurakowski D, Mulliken JB. Soft-tissue vascular anomalies: Utility of US for diagnosis. *Radiology* 2000; 214: 747-754.
- Fontes A, Campos MS, de Sousa SCOM, Martins MT, Nunes FD. Diagnostic implications of oral intravascular endothelial hyperplasia. *Odontology* 2011; 99: 92-97.
- Cohen A, Maly A, Azaz B. Intravascular papillary endothelial hyperplasia of the lower lip: surgical approach and review of the literature. *Gerodontol* 2009; 26:305-308.
- Murphey MD, Fairbairn KJ, Praman LM, Kirkman GB, Parsa MB, Smith WS. Musculoskeletal angiomatous lesions: Radiologic-pathologic correlation. *RadioGraphics* 1995; 15: 893-917(Abs).
- Cohen EK, Kressel HY, Perosio T, Burk DL Jr, Dalinka MK, Kanal E, et al. MR imaging of soft-tissue hemangiomas: Correlation with pathologic findings. *AJR Am J Roentgenol.* 1988; 150: 1079-1081.
- George CD, Ng YY, Hall-Craggs MA, Jones BM. Parotid haemangioma in infants: MR imaging at 1.5T. *Pediatr Radiol.* 1991; 21: 483-485.

17. Siegel MJ, Glazer HS, St Amour TE, Rosenthal DD. Lymphangiomas in children: MR imaging. *Radiology* 1989; 170: 467-470.
18. Itoh K, Nishimura K, Togashi K, Fujisawa I, Nakano Y, Itoh H, et al. MR imaging of cavernous hemangioma of the face and neck. *J Comput Assist Tomogr*. 1986; 10: 831-835.
19. Resnick D. Vascular and lymphatic tumors. In: *Diagnosis of bone and joint disorders* (Draud LA, Fix CF, ed). Philadelphia: Pa: Saunders, 2002; pp 4186-4195.
20. Bunel K, Sindet-Pedersen S. Central hemangioma of the mandible. *Oral Surg Oral Med Oral Pathol*. 1993; 75: 565-570.
21. Sapp JP, Eversole LR, Wysocki GP. *Contemporary oral and maxillofacial pathology*, 2nd edn. St Louis: Mosby, 2004; pp 321-322.
22. Calcaterra TC, Weiss AJ. Adult invasive subcutaneous hemangioma. *Otolaryngology* 1978; 86: 750-754.
23. Ly JQ, Sanders TG, Mulloy JP, Soares GM, Beall DP, Parsons TW, et al: Osseous change adjacent to soft-tissue hemangiomas of the extremities: Correlation with lesion size and proximity to bone. *AJR Am J Roentgenol*. 2003; 180: 1695-1700.
24. Danforth RA, Dus I, Mah J. 3-D volume imaging for dentistry: A new dimension. *J Calif Dent Assoc*. 2003; 31: 817-823.
25. Scarfe WC, Farman AG, Sukovic P. Clinical applications of cone-beam computed tomography in dental practice. *J Can Dent Assoc*. 2006; 72: 75-80.
26. Sukovic P. Cone beam computed tomography in craniofacial imaging. *Orthod Craniofac Res*. 2003; 6 Suppl 1: 31-36 (Abs).
27. Winter AA, Pollack AS, Frommer HH, Koenig L. Cone beam volumetric tomography vs. medical CT scanners. *NY State Dent. J* 2005; 71: 28-33.
28. Marmulla R, Wortche R, Muhling J, Hassfeld S. Geometric accuracy of the NewTom 9000 Cone Beam CT. *Dentomaxillofac Radiol*. 2005; 34: 28-31.
29. Ludlow JB, Davies-Ludlow LE, Brooks SL. Dosimetry of two extraoral direct digital imaging devices: Newtom cone beam CT and Orthophos Plus DS panoramic unit. *Dentomaxillofac Radiol*. 2003; 32: 229-234.
30. Almog DM, LaMar J, LaMar FR, LaMar F. Cone beam computerized tomography-based dental imaging for implant planning and surgical guidance, Part 1: Single implant in the mandibular molar region. *J Oral Implantol*. 2006; 32: 77-81.