

Clinical and Radiological Features of a Large Radicular Cyst Involving the Entire Maxillary Sinus

Filiz Namdar Pekiner¹, Oğuz Borahan¹, Faysal Uğurlu², Sinan Horasan³, B. Cem Şener², Vakur Olgaç⁴

¹Department of Oral Diagnosis and Radiology, Marmara University Faculty of Dentistry, Istanbul-Turkey

²Department of Oral and Maxillofacial Surgery, Marmara University Faculty of Dentistry, Istanbul-Turkey

³Teknogem CBCT Imaging Center, Istanbul-Turkey

⁴Department of Oncologic Cytology and Tumor Pathology, Istanbul University, Institute of Oncology-Turkey

Yazışma Adresi / Address reprint requests to: Filiz Namdar Pekiner

Marmara University Faculty of Dentistry, Department of Oral Diagnosis and Radiology, Güzelbahçe Büyükdüğü Sok. No: 6, 34365 Nişantaşı-Istanbul

Telefon / Phone: +90-212-231-9120/120 Faks / Fax: +90-212-246-5247 Elektronik posta adresi / E-mail address: fpekiner@yahoo.com

Kabul tarihi / Date of acceptance: 09 Şubat 2012 / February 09, 2012

ÖZET

Tüm maksiller sinüsü kaplayan büyük bir kistin klinik ve radyolojik özellikleri

Amaç: Devital bir dişin apeksindeki epitel olası bir enflamasyon ile uyarılarak radiküler kist oluşturabilir. Epitelin kaynağı Malassez artıklarıdır; ancak sinüs sınırı veya fistül yollarının epitelinden de kaynaklanabilir. Radyografik olarak saptanan radyolüsent alanların %7-%54'ünü kistler oluşturmaktadır. Radiküler kistler; 30-60'lı dekatta ve erkeklerde daha fazla görülmektedir.

Metodlar: 38 yaşında erkek hasta Marmara Üniversitesi Diş Hekimliği Fakültesi Oral Diagnoz ve Radyoloji Anabilim Dalı'na palatinal anterior bölgede çift taraflı ağrısız şişlik şikayeti ile başvurmuştur. Şişlik yüzeyi pürüzsüz ve boyutu yaklaşık 6 cm olarak ölçüldü. Vitalometrik muayenede sağ maksiller kaninin devital olduğu belirlenmiştir. Panoramik radyografide sağ 1. Premolardan sol kanine doğru kısmen sklerotik sınır ile çevrili radyolüsent alan izlenen olgunun koronel ve aksiyel bilgisayarlı tomografi görüntülerinde de çevresi ince bir sklerotik sınır ile çevrili sağ maksiller sinüsün büyük bölümünü kaplayan ekspansif süreç izlenmiştir. Volumetrik Bilgisayarlı Tomografi rekonstrüksiyonunda agresif tarzda destrüksiyon ve maksiller sinüse doğru geniş yayılım saptanmıştır. Hasta genel anestezi altında opere edilmiş, insizyon ve mukoperiosteal flap kaldırıldıktan sonra kist bilateral olarak enükle edilmiştir. Post-operatif kanama veya ödemi engellemek için antrotomi yapılarak, operasyon sahası primer olarak suture edilmiştir.

Sonuç: Bu çalışmada maksiller sinüse doğru geniş yayılım gösteren nadir bir radiküler kist olgusunun klinik-radyolojik değerlendirilmesi ve tedavisi sunulmuştur.

Anahtar sözcükler: Bilgisayarlı tomografi, dental volumetrik tomografi, radiküler kist

ABSTRACT

Clinical and radiological features of a large radicular cyst involving the entire maxillary sinus

Objectives: Epithelium at the apex of a nonvital tooth can be presumably stimulated by inflammation to form a true epithelium-lined cyst, or radicular cyst. The source of the epithelium is usually a rest of Malassez but also may be traced to sinus lining or epithelial lining of fistulous tracts. Cyst development is common; the reported frequency varies from 7% to 54% of periapical radiolucencies. The incidence of radicular cysts is greater in the third to sixth decades and shows a slight male predominance. Most of the radicular cysts are found in the maxilla, especially around incisors and canines.

Methods: A 38-year-old male patient was referred to the Department of Oral Diagnosis and Radiology, Faculty of Dentistry, Marmara University, with a complaint of bilateral painless swelling on the anterior of hard palate. The swelling was smooth-surfaced and measured roughly 6 cm. in size. There were no filled teeth, but right maxillary canine was nonvital. Panoramic radiography showed radiolucency with partially sclerotic border from right premolar to left canine in alveolar process. The area was examined with conventional computed tomography to evaluate bone involvement. Coronal and axial computed tomography images showed expansive process occupying most of right maxillary sinus with a very thin sclerotic border. Cone-beam computed tomography image reconstructions showed aggressive destruction and extension into the maxillary sinus. The patient's operation was carried out under general anesthesia. Enucleation after incision and mucoperiosteal flap elevation was performed for both cysts in bilateral locations. In order to avoid postoperative hemorrhage and edema antrotomy was performed. Operation side was sutured primarily.

Conclusion: This presentation describes a relatively rare case of giant radicular cyst occurrence in maxillary sinus and its treatment. Radiological examinations provided valuable information.

Key words: Computed tomography, dental volumetric tomography, radicular cyst

INTRODUCTION

The radicular cyst is a chronic inflammatory lesion with a closed pathologic cavity lined either partially or

completely by non-keratinized stratified squamous epithelium (1-4). The underlying fibrous connective tissue wall is inflamed with varying degrees of cell infiltration, which consists mainly of macrophages and small blood

vessels (3,5). Occasionally however, radicular cysts are found to be lined, partially or predominantly, by columnar ciliated epithelium or mucosecretory cells, which may be due to the migration of these cells from either the maxillary sinus or the nasal cavity, the metaplasia of the stratified squamous epithelium, or to the differentiation of pluripotent cells within the jaw (6).

The radicular cyst is the most frequent cyst found in the jaw (between 38 % and 68 % of all the jaw cysts) (7- 9). The prevalence of periapical cysts varies between 8.7% and 37.7% of chronic inflammatory periapical lesions. This discrepancy is possibly due to the different criteria used in the histological studies; although the boundary between one diagnosis and another is not clearly defined in the literature (6).

The aim of this study is to describe a relatively rare case of giant radicular cyst occurrence in maxillary sinus and its treatment.

CASE REPORT

A 38-year-old male patient was referred to the Department of Oral Diagnosis and Radiology, Faculty of Dentistry, Marmara University, with a complaint of bilateral painless swelling on the anterior of hard palate. The swelling was smooth-surfaced and measured roughly 6 cm. in size, and the lesion was fixed to the underlying bone and was non-mobile (Figure 1). The clinical feature was non-specific, and the patient's medical history was non-

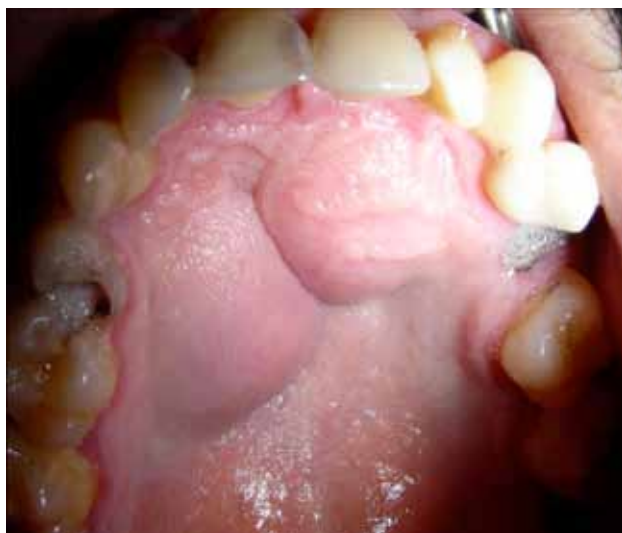

Figure 1: Clinical appearance of the patient showing bilateral painless swelling on the anterior of hard palate.

contributory. There were no filled teeth, but right maxillary canine was nonvital.

Occlusal radiographic investigation revealed a large radiolucency on the anterior of hard palate (Figure 2). Panoramic radiography showed round process (more dense than air) with sclerotic border and radiolucency with partially sclerotic border from right premolar to left canine in alveolar process (Figure 3). The area was examined with conventional Computed tomography (CT) to evaluate bone involvement. Coronal and axial CT images showed expansive process occupying most of right maxillary sinus with a very thin sclerotic border (Figure 4,5,6).

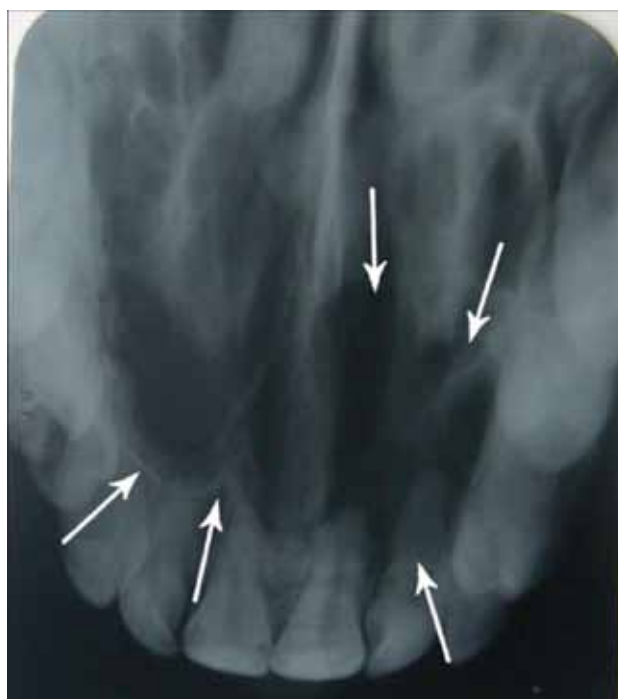

Figure 2: A large radiolucency on the anterior of hard palate on occlusal radiographic view

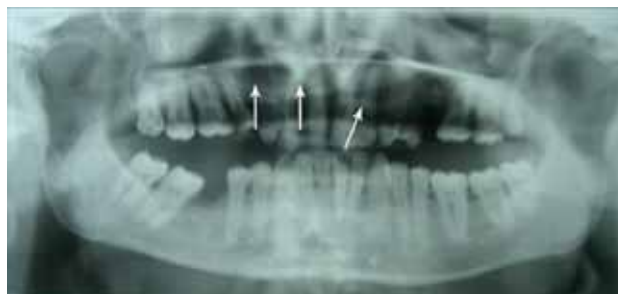

Figure 3: Panoramic radiography showed round process (more dense than air) with sclerotic border and radiolucency with partially sclerotic border from right premolar to left canine in alveolar process

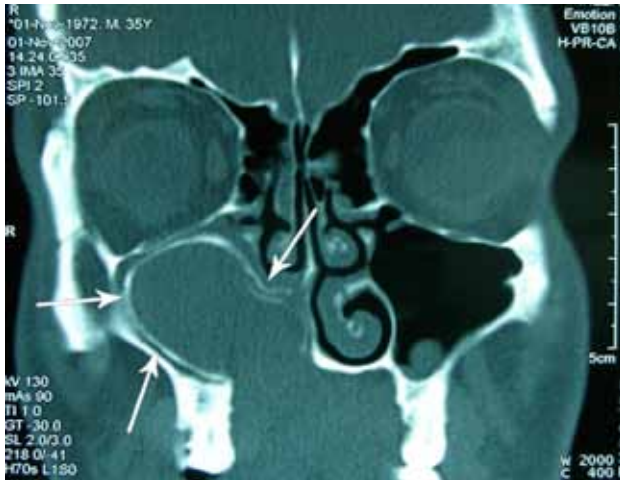

Figure 4: Coronal CT image shows expansive process displacing part of nasal cavity, with intact and sclerotic border, occupying most of right maxillary sinus

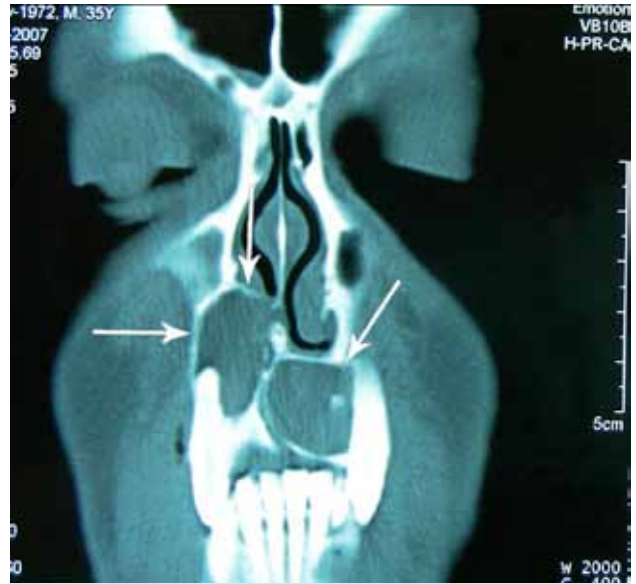

Figure 5: Bilateral scalloped process destroying alveolar bone and hard palate on coronal CT image

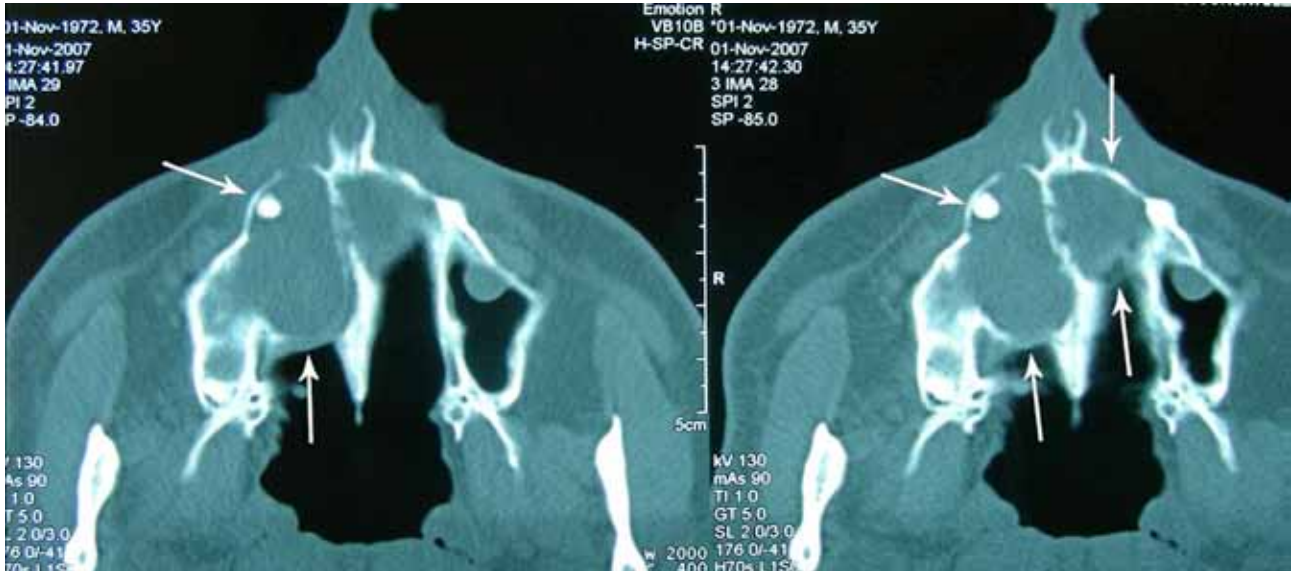


Figure 6: Axial CT image shows scalloped process destroying alveolar bone and hard palate

Many different reconstructions could be carried out using dental volumetric tomography (NewTom 3G NNT Software, Mod.QR-DVT 9000, Verona, Italy). This reconstruction showed aggressive destruction and extension into the maxillary sinus (Figure 7). The patient's operation was carried out under general anesthesia. Enucleation after incision and mucoperiosteal flap elevation was performed for both cysts in bilateral locations. In order to avoid postoperative hemorrhage and edema antrotomy

was performed. Operation side was sutured primarily. As a result of the histopathological examination, the lesion was reported to be compatible with radicular cyst. No complication or residue was seen on the follow-up controls.

DISCUSSION

The etiopathogenesis of cysts is particularly controversial; the formation has been explained by

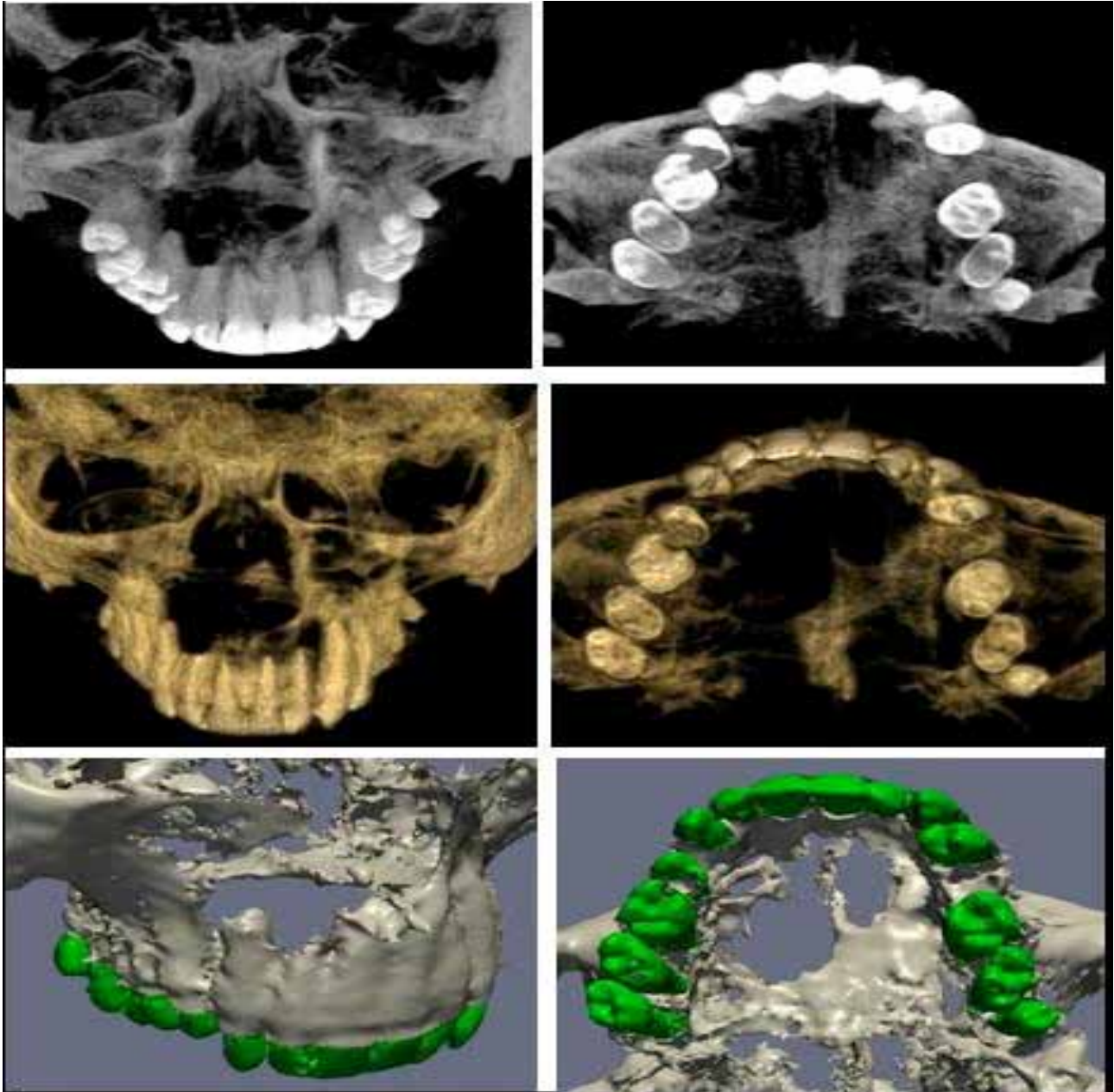


Figure 7: Cone-beam computed tomography image reconstructions of the patient

diverse theories, such as epithelial colonization, epithelial cavitation or the formation of microabscesses. The first is based on the formation of an epithelized fistulous tract up to the granuloma from a periapical abscess fistulized to the oral cavity; when the communication is closed, the epithelial cells have already fully colonized the abscess, epithelizing it and giving rise to a radicular cyst. In the theory of epithelial cavitation, accumulations of epithelial cells are created; those furthest from the connective tissue

which feeds them are left without vascularization and undergo degeneration and necrosis, thus forming the central area of the cyst. The theory of microabscess formation is based on the degeneration of the connective tissue leading to the development of the cyst; the formation of a microabscess in the nucleus of the granuloma, with the presence of stimulated epithelial cells, would lead to their growth in an attempt to line the created cavity (6).

The pathogenesis of cysts has been described in three phases. During the first phase, the epithelial cell rests of Malassez begin to proliferate as a direct result of the inflammation and influenced by bacterial antigens, the epidermal growth factors, metabolic and cellular mediators. In the second, a cavity is formed, lined by epithelium (according to the above described theories), and in the third phase the cyst grows, probably by osmosis (5,9).

Radiographically, the radicular cyst is a unilocular radiolucent lesion with well-circumscribed sclerotic borders that are often radiopaque. The lesion is associated with the apex of the tooth and a diameter of at least 1 cm is postulated to be necessary to differentiate it from that of a normal follicular space (11). Other odontogenic cysts like dentigerous cysts, odontogenic keratocysts, and odontogenic tumors such as ameloblastoma, Pindborg tumor, odontogenic fibroma, and cementomas may share the same radiologic features as radicular cysts. Microscopic evaluation is necessary most of the time to define the type of lesion. In extensive cases, radiography alone may not be sufficient to show the full extent of the lesions, and advanced imaging may be needed.

Of the lesions included in the differential diagnosis of radicular cysts, dentigerous cysts are the most common. Radicular cysts are odontogenic cysts that develop from a periapical granuloma in a carious tooth. Odontogenic keratocysts are often multilocular and most commonly located in the body or the ramus of the mandibula. Ameloblastoma is the most common radiolucent, benign odontogenic tumor that may be unilocular or multilocular. It may cause expansion and destruction of the maxilla and mandibula. Pindborg tumors are rare odontogenic tumors that are radiolucent with well-defined borders and associated calcified radiopaque foci. Odontomas and cementomas are lytic lesions most often accompanied by amorphous calcification. Odontogenic fibromyxoma usually has multiple radiolucent areas of varying size and bony septations, but unilocular lesions have also been described (12).

Chronic abscesses resulted in a loss of the outline of the lower border of the sinus where it abutted the associated tooth, and a related thickening of the sinus mucosa was occasionally evident. Radicular cysts (generally associated with the root apex of a carious or fractured tooth) and

residual cysts caused an upward displacement of the floor of the sinus, but the cortical outline remained intact. Extensive dental cysts extended into the sinus away from the original epicenter. Even a very large radicular cyst arising in the maxilla resulted in surprisingly little in the way of clinically noticeable jaw expansion. Dentigerous cysts had a similar effect on the floor of the maxillary sinus to that observed for radicular cysts, however, the dentigerous cyst enveloped the crown of an unerupted tooth. As the tooth was displaced there was the appearance of a tooth suspended within the sinus (13).

When cysts are especially large, with maxillary sinus involvement as in our patient, the panoramic radiograph is often not of great aid. CT scans provide superior bony detail, allowing for the visualization of the size and extent of the lesion with determination of orbital or nasal invasion or involvement. Again, with larger lesions, it also aids in planning of a surgical approach. Mucoceles, retention cysts, and pseudocysts are also included in the differential diagnosis when a maxillary sinus cyst is visualized involving maxillary expansion; this is in addition to the array of radiolucent lesions mentioned above that can also be visualized on CT (14).

The digital volumetric tomography has become a very useful tool in the field of a series of cases like preoperative and postoperative views of trauma patients, giant-cell granuloma of the mandible, a cyst in the maxillary sinus. The device and the software program are easy to use. Furthermore, the radiation exposure of the patient during the digital volumetric tomography examination is lower when compared with a standard CT examination performed in the same area (15). The digital volumetric tomography was used in our case and the radicular cyst involving the entire maxillary sinus could be visualized in all directions.

CONCLUSION

The present case report demonstrates a radicular cyst invading in the maxillary sinus. The clinical characteristics of this cyst could be used as an interesting data due to its rarity and giantness. In this case; in order to display the size of the cyst, panoramic radiograph and CT is used. However, as the range of diagnostic and planning options (unlimited number of sections) is extremely wide and because of lower

patient radiation dose, lower equipment cost and visualizing 3D reconstructions in all directions, dental volumetric tomography is superior to other imaging methods. Therefore; in this study dental volumetric tomography is shown to facilitate the visualization of a giant radicular cyst.

REFERENCES

- Ramachandran Nair PN, Pajarola G, Schroeder HE. Types and incidence of human periapical lesions obtained with extracted teeth. *Oral Surg Oral Med Oral Pathol Oral Radiol Endod* 1996; 81(1):93-102.
- Nair PN, Sundqvist G, Sjögren U. Experimental evidence supports the abscess theory of development of radicular cysts. *Oral Surg Oral Med Oral Pathol Oral Radiol Endod* 2008; 106(2):294-303.
- Kafas P, Dalfas S, Upile T, Jerjes W. Uncommon synchronous histopathological features of a radicular cyst: a case report. *Cases J* 2009; 25;2:9067.
- Neville BW, Damm DD, Allen CM, Bouquet JE. *Oral and Maxillofacial Pathology*. 3rd Edition, 2009, Saunders Elsevier: 130-131.
- Tsai CH, Weng SF, Yang LC, Huang FM, Chen YJ, Chang YC. Immunohistochemical localization of tissue-type plasminogen activator and type I plasminogen activator inhibitor in radicular cysts. *J Oral Pathol Med* 2004;33(3):156-161.
- García CC, Sempere FV, Diago MP, Bowen EM. The post-endodontic periapical lesion: histologic and etiopathogenic aspects *Med Oral Patol Oral Cir Bucal* 2007; 1;12(8):E585-590.
- Grossmann SM, Machado VC, Xavier GM, Moura MD, Gomez RS, Aguiar MC, Mesquita RA. Demographic profile of odontogenic and selected nonodontogenic cysts in a Brazilian population. *Oral Surg Oral Med Oral Pathol Oral Radiol Endod* 2007;104(6):e35-41.
- Ustuner E, Fitoz S, Atasoy C, Erden I, Akyar S. Bilateral maxillary dentigerous cysts: a case report. *Oral Surg Oral Med Oral Pathol Oral Radiol Endod* 2003;95(5):632-635.
- Açıkgöz A, Uzun-Bulut E, Ozden B, Gündüz K. Prevalence and distribution of odontogenic and nonodontogenic cysts in a Turkish Population. *Med Oral Patol Oral Cir Bucal* 2012; 17(1):e108-115.
- Brave D, Madhusudan AS, Ramesh G, Brave VR. Radicular cyst of anterior Maxilla. *Int J Dent Clin* 2011;3(2):16-17.
- Ricucci D, Mannocci F, Ford TR. A study of periapical lesions correlating the presence of a radiopaque lamina with histological findings. *Oral Surg Oral Med Oral Pathol Oral Radiol Endod* 2006;101(3):389-394.
- Schramm A, Rücker M, Sakkas N, Schön R, Düker J, Gellrich N-C. The use of cone beam CT in cranio-maxillofacial surgery. *International Congress Series* 1281 (2005) 1200-1204.
- Farman AG, CJ Nortjé. *Panoramic Imaging News*. 2002; 2(3).
- AS Tournas, MA Tewfik, PJ Chauvin, JJ Manoukian Multiple unilateral maxillary dentigerous cysts in a non-syndromic patient: A case report and review of the literature. *Int J Pediatric Otorhinol Extra* 1,(2) 2006; 100-106.
- Neyaz Z, Gadodia A, Gamanagatti S, Mukhopadhyay S. Radiographical approach to jaw lesions. *Singapore Med J* 2008; 49(2):165-175.

Acknowledgements

This study is presented in 11th European Congress of Dentomaxillofacial Radiology on 25-28 June 2008, Budapest, Hungary and supported by Marmara University Scientific Research Project Council (Project no: SAG-D-050608-0114).