

Cleidocranial Dysplasia: A Case Report with Clinical, Radiographic, and Genetic Findings

Filiz Namdar Pekiner¹, Mehmet Oğuz Borahan¹, Korkut Ulucan²

¹Marmara University, Faculty of Dentistry, Department of Oral Diagnosis and Radiology, Istanbul - Turkey

²Marmara University, Faculty of Dentistry, Department of Medical Biology and Genetics, Istanbul - Turkey

Yazışma Adresi / Address reprint requests to: Filiz Namdar Pekiner

Marmara University, Faculty of Dentistry, Department of Oral Diagnosis and Radiology, Guzelbahce Buyukciftlik Sok. No: 6, 34365 Nisantasi, Istanbul - Turkey

Telefon / Phone: +90-212-231-9120 Faks / Fax: +90-212-246-5247 Elektronik posta adresi / E-mail address: fpekiner@yahoo.com

Kabul tarihi / Date of acceptance: 30 Nisan 2012 / April 30, 2012

ÖZET

Kleidokranial displazi: klinik, radyografik ve genetik bulgularla bir olgu sunumu

Amaçlar: Bu çalışmanın amacı kleidokranial displazi (disostozis)li bir hastayı sunmaktır.

Yöntem: Kleidokranial displazili bir hasta oligodonti şikayeti ile Marmara Üniversitesi Dişhekimliği Fakültesi Oral Diagnoz ve Radyoloji Kliniği'ne başvurmuştur. Ekstra oral fiziksel muayenede; omuzunu hareket ettirmesi istendiğinde humeral başların normalden daha yakına geldiği görüldü. İntra-oral muayenede maksillada atrezi, derin damak ve mikst dentisyon olduğu belirlendi. Gömük dişlerin daha detaylı görüntülenmesi için dental volumetrik tomografi alındı. Klinik ve radyolojik muayeneyi teyit etmek için genetik analiz yapıldı. Hasta çocuk ve annesinden alınan kan örneklerinde High PCR Template Preparation Kit kullanılarak DNA incelemesi yapıldı.

Bulgular: Genin ilk iki eksonu primer kullanılarak genişletildi. İki adet sıralanmış eksonda herhangi bir mutasyon izlenmedi.

Sonuçlar: Bu hastalarda ortodontik ve cerrahi tedavi uygundur. Bu vakanın tedavi planlaması periodontal, cerrahi ve ortodontik tedavileri içermektedir ve gerektiğinde protetik rehabilitasyon planlanmıştır.

Anahtar sözcükler: Kleidokranial disostozis, dental volumetrik tomografi, supernumerer diş

ABSTRACT

Cleidocranial dysplasia: a case report with clinical, radiographic, and genetic findings

Objectives: The purpose of this study is to present a patient with cleidocranial dysostosis.

Materials and Methods: A 17 year-old male patient with cleidocranial dysostosis referred to Marmara University, Dentistry Faculty, Department of Oral Diagnosis and Radiology with complaints of oligodontia. In the extra-oral physical examination when the patient was asked to move his shoulders, he was capable of bringing closer the humeral heads, which characterized the hipermobility of the shoulders. In the intra-physical examination the atresia of the maxilla, ogival, deep palatum, and a mixed dentition were clear. In order to evaluate the impacted teeth in detail, dental volumetric tomography was taken. In order to confirm clinical and radiological diagnosis of cleidocranial dysostosis, the genetic analysis of the patient was performed. DNA from affected child and his mother was obtained from peripheral blood by using High PCR Template Preparation Kit.

Results: The first two exons of the gene were amplified by using primers. No mutation was found in two sequenced exons.

Conclusion: For patients with compromised esthetics, surgical treatment with orthodontic traction is a convenient and viable alternative. Our treatment plan consisted of periodontal and orthodontic treatments and further prosthodontic rehabilitation was planned in case of need.

Key words: Cleidocranial dysostosis, dental volumetric tomography, supernumerary tooth

INTRODUCTION

Cleidocranial dysplasia (CCD, also known as cleidocranial dysostosis) is an autosomal dominant skeletal dysplasia characterized by abnormal clavicles. The term cleidocranial dysostosis was first introduced in 1898 by Marie and Sainton (1,2). CCD was originally thought to involve only bones of membranous origin. More recent and detailed clinical investigations have shown that CCD is a generalised skeletal dysplasia affecting not only the clavicles and the skull but the entire skeleton. CCD was therefore considered

to be a dysplasia rather than a dysostosis (3). The estimated prevalence of CCD is one per million, but it is most likely underdiagnosed because of the relative lack of medical complications in comparison to other skeletal dysplasias (4).

Apart from anomalies of the clavicles, which appear to be present in nearly all patients, changes in the dental, oral and maxillary areas are among the most striking and most frequent pathological conditions associated with CCD (5). The craniofacial morphology of the affected persons in particular presents some special features. For example,

while the length of the maxilla is unremarkable, its anterior and posterior height is reduced. The maxillary sinus is also diminished in comparison to that of healthy persons. The palate is described as high, narrow and strongly arched (6). The length and posterior height of the mandible are diminished. In addition, the mandible is inclined anteriorly and closure of the mandibular symphysis is delayed (7). In nearly all cases, there is retention of the deciduous teeth, associated with delayed eruption of the permanent teeth, which often marks a delayed development of the roots. A further impressive feature is the existence of supernumerary teeth, which disturbs the position and eruption of the regular teeth. In isolated cases, up to 30 additional (3) or up to 63 non-erupted teeth (8,9) have been reported.

CCD is associated with mutations of mammalian runt-related gene 2 (Runx2) (MIM 600211) that has been mapped to 6p21 (10). Its protein product, RUNX2 protein, acts as a transcriptional factor that is essential for osteoblast and dental cell differentiation as well as tooth and bone formation. Several RUNX2 mutations have been published in independent cases of CCD, that include missense mutations, deletions, insertions, frameshift, and splice mutations (11). However, mutational screening of the RUNX2 gene is still far from saturation, and more mutations should be identified to fulfill the molecular mechanism of the pathogenesis of CCD.

In this article, we present a clinical, radiographic and RUNX2 exon analyses of a patient who referred to us with oligodontia complaints and whose physical appearance led to the diagnosis of CCD.

CASE REPORT

A 17 year-old male patient referred to Marmara University, Dentistry Faculty, Department of Oral Diagnosis and Radiology with complaints of oligodontia. In the extra-oral physical examination, the patient showed a straight profile with prominent chin and beaked nose. (Figure 1,2). When asked to move the shoulders, he was capable of bringing closer the humeral heads, which characterized the hypermobility of the shoulders. Chest X-ray showed absence of clavicle in both sides, scapula and glenoid cavity were small and ribs were directed obliquely downwards (Figure 3).

In the intraoral examination the atresia of the maxilla, ogival and deep palatum, and also a mixed dentition were

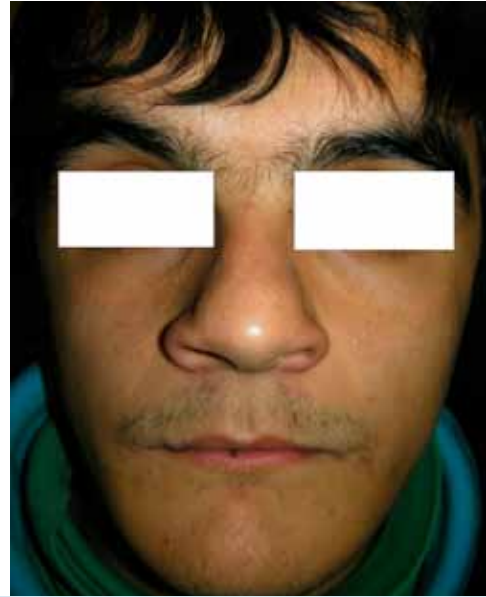

Figure 1: Clinical appearance of the patient showing hypoplastic midface.

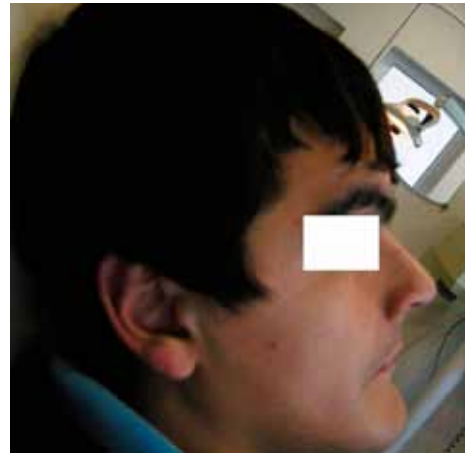

Figure 2: Lateral view of the patient showing a straight profile with prominent chin and beaked nose.

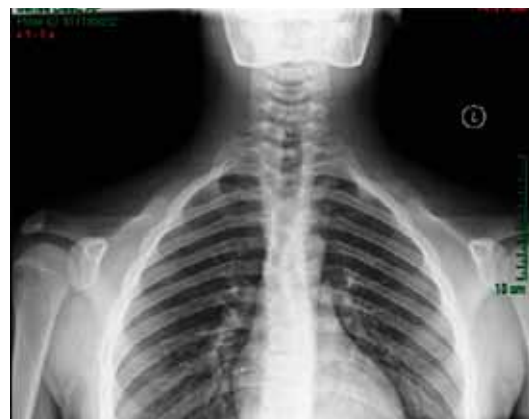

Figure 3: Chest radiograph showing aplasia of clavicles in both sides.

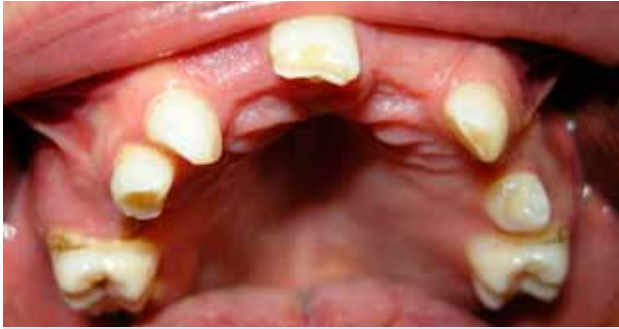

Figure 4: The palate is described as high, narrow and strongly arched.

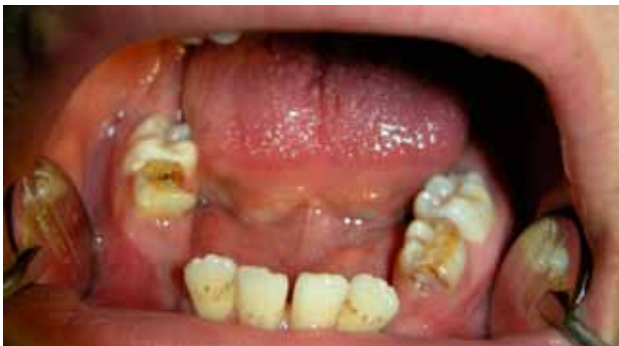

Figure 5: Mandibula with mixed dentition.

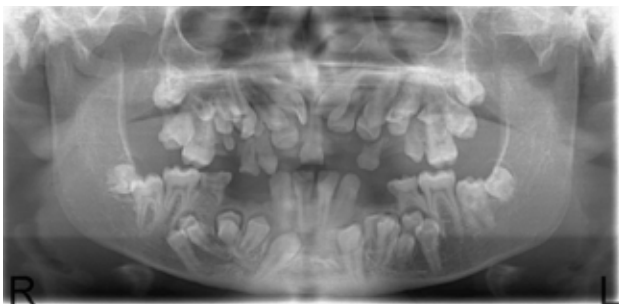


Figure 6: Panoramic radiography that shows the existence of several dental elements retained and impacted in maxilla and mandible, supernumerary teeth and underdeveloped maxillary sinus.

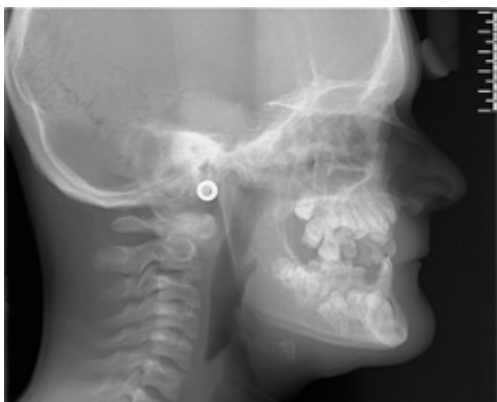

Figure 7: In lateral cephalogram, underdeveloped maxilla and deep mandibular notch is seen.

clear (Figure 4,5). The orthopantomogram and cephalometric radiograph outlined the presence of total 52 teeth in both jaws and underdeveloped maxillary sinus (Figure 6,7). Out of these, 15 teeth were seen in the oral cavity and other were impacted and supernumerary. In order to re-evaluate the impacted teeth in detail, dental volumetric tomography was taken (Figure 8,9).

To identify the RUNX2 mutations in the diagnosis of cleidocranial dysostosis, a molecular genetic analysis of the underlying gene was carried out using amplification through polymerase chain reaction (PCR). DNA from affected child and his mother was obtained from peripheral blood by using High Pure PCR Template Preparation Kit. Exons 0–7 of the RUNX2 gene were amplified by using primers previously described (10). Amplicons were directly sequenced by the same primers in ABI PRISM 310 Genetic Analyzer (Applied Biosystems, USA) by using DYEnamic ET Terminator Cycle Sequencing Kit (Amersham, England). We could not detect any mutation in the coding regions of RUNX2 gene with exon-intron boundaries (Figure 10).

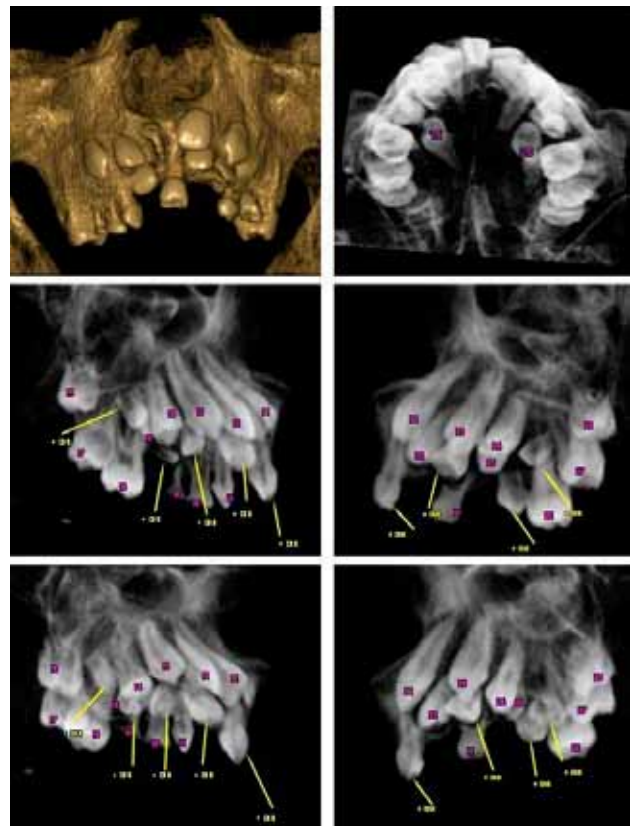


Figure 8: 3D and sagittal view of the maxilla acquired with dental volumetric tomography.

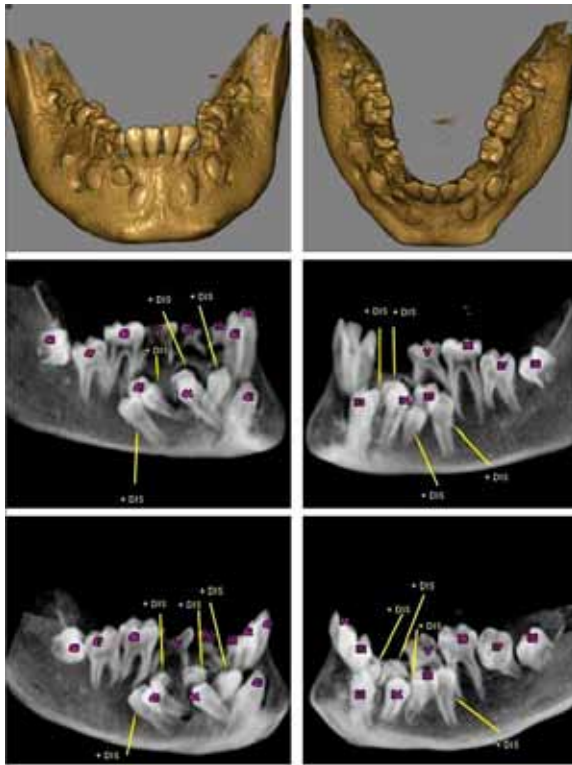


Figure 9: 3D and sagittal view of the mandibula acquired with dental volumetric tomography.

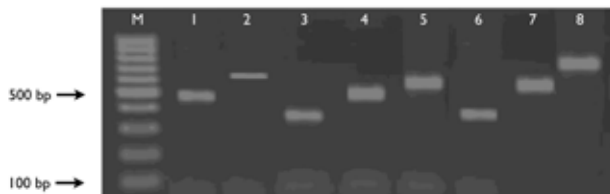


Figure 10: Agarose gel electrophoresis view of the examined amplicons; M: Molecular marker, 100 bp (Fermentas, Germany); Lane 1: Exon 0 (484 bp); Lane 2: Exon 1 (630 bp); Lane 3: Exon 2 (388 bp); Lane 4: Exon 3 (489 bp); Lane 5: Exon 4 (514 bp); Lane 6: Exon 5 (373 bp); Lane 7: Exon 6 (587 bp); Lane 8: Exon 7 (781 bp).

DISCUSSION

The dental characteristics in cleidocranial dysplasia are essentially, the retention of the deciduous dentition, the presence of many supernumerary teeth, and noneruption of the permanent dentition. The reasons for these phenomena are unclear but, in common with a lack of medical and physical disability, actual dental discomfort may also be absent, unless the deciduous teeth become decayed or shed naturally and the patient may have no substantive complaint, other than facial appearance (12).

It is stated that the failure in the eruption can be related

with the absence or inadequate cellular cementum in the permanent teeth roots (13). This was also claimed by Smith, who had observed the absence of cellular cementum in the deciduous and permanent dentition (14). There are also other hypotheses that explain this fact, as the lack of absorption of the deciduous teeth and subjacent bone and also the presence of a physical barrier, represented by the supernumerary teeth impacted or by a fibrous connective tissue interposed between the dental folliculus and the mucosa (15).

The radiological molecular of CCD is almost sufficient for diagnosis. Various features that are evident on panoramic radiographs are multiple unerupted teeth, a narrow ascending ramus, a slender and pointed coronoid process, a thin zygomatic arch with a severe downward tilt, small or absent maxillary sinuses, coarse trabeculation of the mandible, supernumerary teeth mainly in the premolar region, and increased density of the alveolar crestal bone over unerupted teeth (16). Our case showed the typical features of CCD as multiple unerupted teeth, small maxillary sinus and lack of clavicles.

RUNX2 gene consists of eight coding exons and spans a genomic region of 130 kb and encodes a transcription factor that is a member of the runt family of proteins. RUNX2 contains a DNA-binding domain (runt domain) highly homologous to the *Drosophila* pair-rule gene runt, a region of glutamine and alanine repeating in the N-terminal region (QA domain), and a region rich in proline-serine-threonine (PST), which is necessary for transcriptional activation of target genes. RUNX2 is essential for the development of osteoblasts from their mesenchymal precursors (10). CCD is usually caused by a mutation of RUNX2. However 40% of CCD cases appear spontaneously with no apparent genetic cause (17). We detected no mutation in RUNX2 coding regions. There are several studies reporting mutations of RUNX2 gene on the onset of CCD (18-21). Insertions or deletions that can not be analysed by direct exon sequencing of coding regions may be one of the reasons that we could not make genotype-phenotype correlation. Methylation profile is also important in gene expression and this may help us to explain the role of gene in anomalies where no variation in the related gene was observed.

Other genes that play role in the same metabolic pathway with RUNX2 may be mutated rather than RUNX2,

and these will be the focus of our further studies.

In terms of dental management of CCD, several approaches have been reported over the years. The option of no treatment was common in the past (22). Edentulation followed by provision of dentures has also been suggested. Some regard this approach as too invasive, especially considering the extensive bone loss experienced after removal of teeth in a patient already deficient in alveolar bone. Removal of only the erupted teeth and use of a removable prosthesis to minimize alveolar bone loss are suggested. However, subsequent eruption of retained teeth can require further surgery and modification of the prosthesis. The current treatment involves a combination of orthodontics and maxillofacial surgery (23). Our protocol involves timely extraction of deciduous teeth, staged surgical removal of

supernumerary teeth, exposure of selected unerupted permanent teeth and orthodontic forced eruption. The delay in the eruption and the absence of permanent teeth, observed in our case, caused a strong sentiment of sadness in the patient and led him to look for treatment.

CONCLUSION

Although several bones in the body could present the cleidocranial dysplasia, the craniofacial characteristic is the main reason for the medical-odontological visits to the doctor. That is why the dentist is so important in the diagnosis of this condition, as well as in the implementation of a therapeutic multidisciplinary planning, aiming the improvement in the life quality of the patients.

REFERENCES

- Segal N, Puterman M. Cleidocranial dysplasia - review with an emphasis on otological and audiological manifestations. *Int J Pediatr Otorhinolaryngol.* 2007;71(4): 523-526.
- Pamuk ON, Mundlos S, Cakir N. Cleidocranial dysplasia in a mother and her two children. *Joint Bone Spine.* 2008;75(6): 725-727.
- Mundlos S. Cleidocranial dysplasia: clinical and molecular genetics. *J Med Genet* 1999;36: 177-182.
- Cooper SC, Flaitz CM, Johnston DA, Lee B, Hecht JT. A natural history of cleidocranial dysplasia. *Am J Med Genet.* 2001;104(1): 1-6.
- Lossdörfer S, Abou Jamra B, Rath-Deschner B, Götz W, Abou Jamra R, Braumann B, Jäger A. The role of periodontal ligament cells in delayed tooth eruption in patients with cleidocranial dysostosis. *J Orfac Orthop.* 2009;70(6): 495-510.
- Kargul B, Salih IM, Yilmaz L, et al. Cleidocranial dysostosis: report of a case. *J Clin Pediatr Dent.* 1997;22: 83-86.
- Jensen BL. Cleidocranial dysplasia: craniofacial morphology in adult patients. *J Craniofac Genet Dev Biol.* 1994;14: 163-176.
- Yamamoto H, Sakae T, Davies JE. Cleidocranial dysplasia: a light microscope, electron microscope, and crystallographic study. *Oral Surg Oral Med Oral Pathol.* 1989;68: 195-200.
- Garg RK, Agrawal P. Clinical spectrum of cleidocranial dysplasia: a case report. *Cases J.* 2008;1(1): 377.
- Wang GX, Sun RP, Song FL. A novel RUNX2 mutation (T420I) in Chinese patients with cleidocranial dysplasia. *Genetics and Molecular Research.* 2010;9(1): 41-47.
- Shen Z, Zou CC, Yang RW, Zhao ZY. Cleidocranial dysplasia: report of 3 cases and literature review. *Clin Pediatr.* 2009;48: 194-198.
- Becker A, Lustmann J, Shteyer A. Cleidocranial dysplasia: Part 1-General principles of the orthodontic and surgical treatment modality. *Am J Orthod Dentofac Orthop.* 1997;111: 28-33.
- Rushton, M. A. An anomaly of cementum in cleidocranial dysostosis. *Br Dent J.* 1956;100: 81.
- Smith, N.H.H. A histologic study of cementum in a case of cleidocranial dysostosis. *Oral Surg.* 1968;25: 470.
- Alves N, Oliveira R. Cleidocranial Dysplasia - A Case Report. *Int J Morphol.* 2008;26(4): 1065-1068.
- McNamara CM, O'Riordan BC, Blake M, Sandy JR. Cleidocranial dysplasia: radiological appearances on dental panoramic radiography. *Dentomaxillofac Radiol.* 1999;28(2): 89-97.
- Mohan RP, Suma GN, Vashishth S, Goel S. Cleidocranial dysplasia: clinico-radiological illustration of a rare case. *J Oral Sci.* 2010;52(1): 161-166.
- Bergwitz C, Prochnau A, Mayr B, Kramer FJ, Rittierodt M, Berten HL, Hausamen JE, Brabant G. Identification of novel CBFA1/RUNX2 mutations causing cleidocranial dysplasia. *J Inherit Metab Dis.* 2001;24: 648-656.
- Zheng Q, Sebald E, Zhou G, Chen Y, Wilcox W, Lee B, Krakow D. Dysregulation of chondrogenesis in human cleidocranial dysplasia. *Am J Hum Genet.* 2005;77: 305-312.
- Sadikovic B, Yoshimoto M, Chilton-MacNeill S, Thorne P, Squire JA, Zielenska M. Identification of interactive networks of gene expression associated with osteosarcoma oncogenesis by integrated molecular profiling. *Hum Molec Genet.* 2009;18: 1962-1975.
- Yoshida T, Kanegane H, Osato M, Yanagida M, Miyawaki T, Ito Y, Shigesada K. Functional analysis of RUNX2 mutations in Japanese patients with cleidocranial dysplasia demonstrates novel genotype-phenotype correlations. *Am J Hum Genet.* 2002;71: 724-738.
- Becker A. The orthodontic treatment of impacted teeth. London: Martin Dunitz Ltd.; 1998. p. 199-227.
- Daskalogiannakis J, Piedade L, Lindholm TC, Sándor GK, Carmichael RP. Cleidocranial dysplasia: 2 generations of management. *J Can Dent Assoc.* 2006;72(4): 337-342.