

Fluorescence-Guided Resection of Oral Verrucous Carcinoma

Gökhan Göçmen¹, Asım Dumlu², Altan Varol¹, Selçuk Basa¹, Kamil Göker¹

¹Department of Oral and Maxillofacial Surgery, Marmara University, Faculty of Dentistry, Istanbul - Turkey

²Department of Oral Diagnosis and Radiology, Marmara University Faculty of Dentistry, Istanbul - Turkey

Yazışma Adresi / Address reprint requests to: Gökhan Göçmen,
Department of Oral and Maxillofacial Surgery, Marmara University, Faculty of Dentistry, Istanbul - Turkey
Elektronik posta adresi / E-mail address: gocmengokhan@hotmail.com
Kabul tarihi / Date of acceptance: 6 Eylül 2012 / September 6, 2012

ÖZET

Oral verrüköz karsinomun floresans rehberli rezeksiyonu

Oral verrüköz karsinomunun (OVC) cerrahi tedavisinde rezeksiyon sınırlarının doğru belirlenmesi hastalığın prognozu ve reküransı açısından oldukça önemlidir. Ameliyat sırasında malignite ve rezeksiyon sınırlarının belirlenmesi genellikle dokunun normalden farklı görünüşüne göre yapılmaktadır. Direkt floresans ışık rehberliğinde yapılan rezeksiyon yeni bir metot olup, ameliyat sırasında lezyon sınırlarının konvansiyonel yöntemlerden daha güvenilir ve kolay şekilde yapılmasını sağlar. Bu vaka raporunda, direk floresans ışık rehberliğinde OVC rezeksiyonu uygulaması sunulmuştur.

Anahtar sözcükler: Oral verrüköz karsinoma, floresans

ABSTRACT

Fluorescence-guided resection of oral verrucous carcinoma

Maximum safe resection plays a key role for the postoperative prognosis of patients with oral verrucous carcinoma (OVC). Preoperative and intraoperative assessment of the malignancy free margin is dependent on the visual appearance in current practice. Fluorescence-guided resection is a novel method, which has demonstrated utility in increasing resection quality by providing real-time visualization of lesion. Herein, we report the resection of OVC with the assistance of direct fluorescence visualization (DFV).

Key words: Oral verrucous carcinoma, fluorescence

INTRODUCTION

Oral verrucous carcinoma (OVC) is a non-metastasizing variant of well- differentiated squamous cell carcinoma, which often presents as an exophytic, white keratotic, warty tumour (1,2). White keratotic mucosal lesions cannot be ascertained on clinical grounds; therefore, surgical biopsy with microscopic examination by a pathologist remains the standard for the diagnosis (3). Participation of screening devices could be an alternative to facilitate initial diagnosis, intraoperative determination and follow-up.

Direct fluorescence visualization (DFV) is a promising approach that facilitates the visualization and management of carcinoma (4). Recently, Pautke et al. introduced fluorescence-guided bone resection (FGBR) method for necrotic bone identification (5). Fluorescence visualization could prevent from inadequate surgical resection when compromising surgical margins of locally aggressive

carcinoma. Herein, we present a case report of OVC that was diagnosed, resected and followed with the assistance of DFV.

CASE

A 46-year-old female patient complaining about thick white cauliflower like lesion at maxillary anterior vestibular mucosa for 3 years was referred to Marmara University, Faculty of Dentistry on March 9, 2010. The medical history revealed no systemic disease. She had a history of tobacco use for 15 years. No regional lymph node involvement was found during neck palpation.

Patient had consulted to several private dental centers for the white lesions and only undergone primary periodontal therapy. After 2 years, she had lost upper lateral and central incisors. She was rehabilitated prosthetically with fixed metal-ceramic bridge between two canines but

still had these white lesions with swelling and pain this time. Thereon, the dentist who made the prosthetic rehabilitation undertook antibiotic treatment and referred the patient to our hospital (Fig. 1). Initially, fluorescence visualization examination (FVE) was performed by the assistance of VELscope (LED Dental Inc., White Rock, Canada) to decide the most favorable biopsy region. Concurrently, diascopy was conducted to set aside eventuality of inflammation. Two excisional biopsies were taken from two different and dark-colored fluorescence visualization loss (FVL) regions where it was considered as a potential carcinoma in situ (CIS)

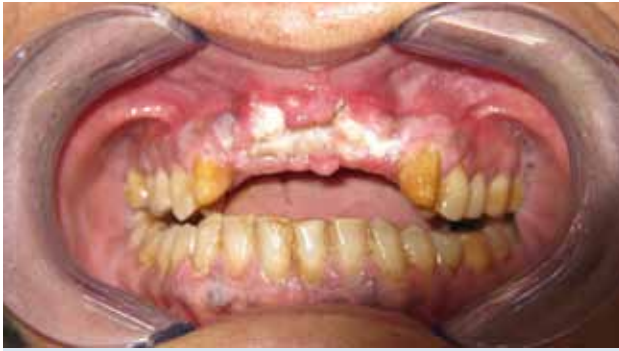

Figure 1: Exophytic, white keratotic view under white light examination.

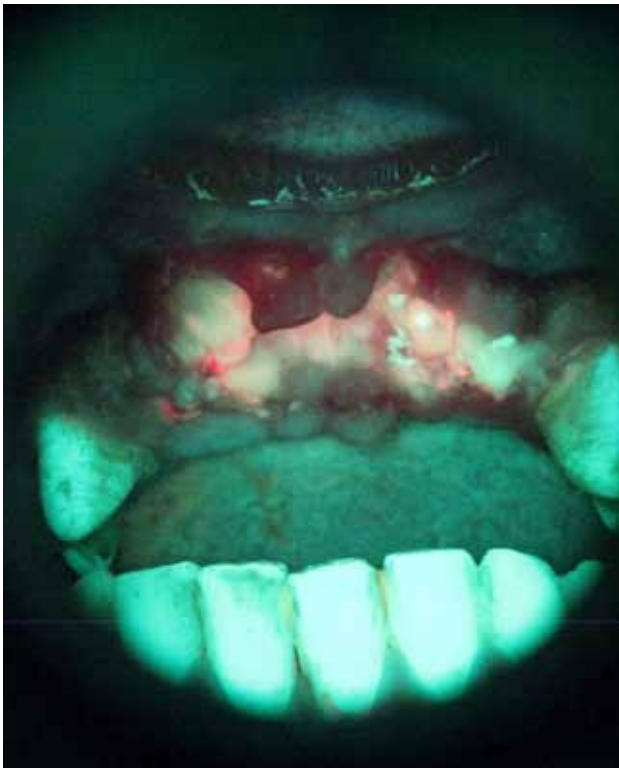

Figure 2: Dark area is VEL-scope- positive, which was confirmed by biopsy as Verrucous Carcinoma (VC)

or carcinoma (Fig. 2). Histopathological characteristics of the excised specimens revealed acanthosis, papillomatosis and hyperkeratosis of the epithelium of the lesion, continuing with characteristics of healthy mucosa. Squamous epithelial cell composition of the tumor did not give a definite atypical character, but showed blunt rete processes towards the sub-epithelial area. Lymphocyte infiltration was noted in the periphery of the tumor islands.

Soft tissue invasion of the tumor was defined by FVE. Patient received doxycycline, 100 mg twice a day for 10 days preoperatively for bone labeling. FVL was detected 2 mm lateral to both canine teeth. Superior and palatal edges of invasion were observed as well. According to predetermined soft tissue edges, initial incisional margins were defined. Doxycycline-derived bone fluorescence visualization was followed under blue excitation. Bony infiltration was inspected under fluorescence illumination,

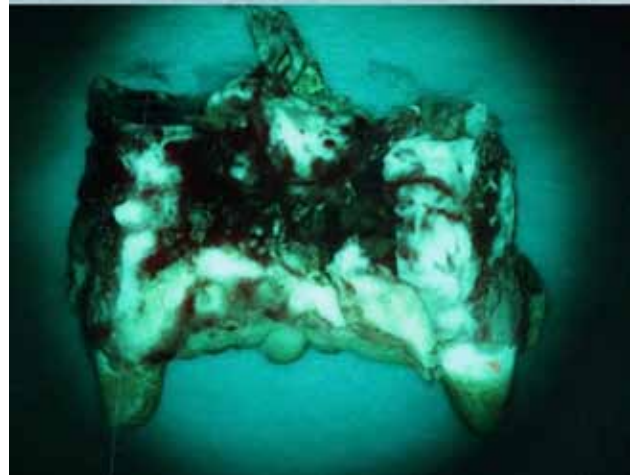
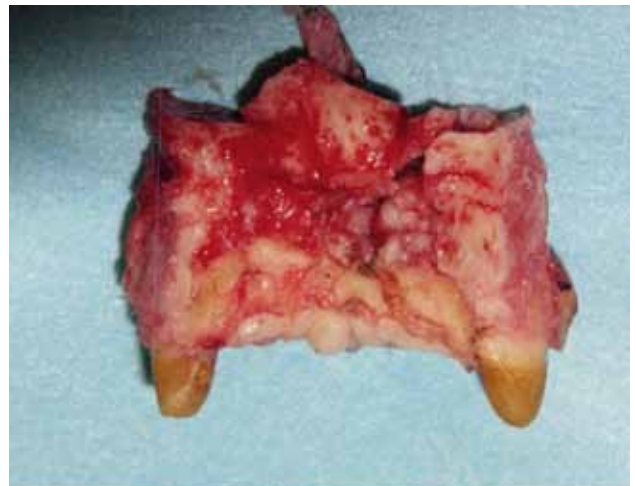

Figure 3: Infiltration of VC which was identified by fluorescence visualization

so outline and debridement of the exact margins of the necrosis was performed (Fig. 3).

Patient did not receive any radiotherapy and chemotherapy postoperatively. At 1-year postoperative follow-up, control FVE was performed and no clinical and radiological findings were detected. The patient was disease-free for 2 years.

DISCUSSION

Optical technology with light-based detection systems can be employed in obtaining biopsy and intraoperative determination process (6). Laboratory and clinical studies suggest that changes in natural fluorescence reflect biochemical and morphological alterations to tissues that could serve as noninvasive indicators of malignancies (7-9).

Sampling error, insufficient epithelial tissue and inflammation are the most common reasons for discordant results of preoperative biopsy and frozen sections (10). In this case, we used fluorescence guidance to indicate the most potential region to obtain specimens and gain accurate resection.

OVC has a tendency to erode bony structures with a sharp margin rather than infiltrating the marrow spaces. (11). The incidence of bone involvement is generally low, 1.2% in 426 cases (12). It has also been reported that the slow growth of OVC and lower invasive potential could

induce inadequate surgical resections (13). Surgery is considered the primary mode of treatment for OVC. Irradiation alone or in combination with surgery is rarely performed. OVC have an excellent prognosis with surgical management but local recurrences can be attributed to inadequate surgical resection (14).

Frozen sections can be used for distinguishing benign from malignant disease, which is generally associated with a high degree of accuracy (15). However, it is difficult and time consuming to control intraoperative margins with these sections (10). DFV has its own advantages as quick and easy appliance. It presents more accuracy than former methods, considering bone color or bleeding (17). Pautke et al. presented first clinical results of FGBR and claimed that it is a valuable technique to distinguish viable and necrotic bone (5). We decided surgical debridement of the margins according to soft tissue involvement and proceeded with regard to bone and mucosal invasion.

In conclusion, FVE is a promising method, which can be used while obtaining the biopsy specimen and detecting surgical excision margins of both mucosa and bone. Furthermore, it is feasible for capturing the dysplasias or the recurrences during the follow-up periods of VOC. However, further studies including more cases and long time follow-up are necessary to evaluate the outcomes of fluorescence-guided resection of VOC.

REFERENCES

- Ackerman LV. Verrucous carcinoma of the oral cavity. *Surgery*. 1948;23(4):670-678.
- Rekha KP, Angadi PV. Verrucous carcinoma of the oral cavity: a clinico-pathologic appraisal of 133 cases in Indians. *Oral Maxillofac Surg*. 2010;14(4):211-218.
- Melrose RJ, Handlers JP, Kerpel S, Summerlin DJ, Tomich CJ. The use of biopsy in dental practice. The position of the American Academy of Oral and Maxillofacial Pathology. *Gen Dent*. 2007;55(5):457-461.
- Lane PM, Gilhuly T, Whitehead P, Zng H, Poh CF, Ng S, Willis PM, Zhang L, Rosin MP, MacAulay CE. Simple device for the direct visualization of oral-cavity tissue fluorescence. *J Biomet Opt*. 2006;11(2):024006.
- Pautke C, Bauer F, Otto S, Tischer T, Steiner T, Weitz J, Kreutzer K, Hohlweg-Majert B, Wolff KD, Hafner S, Mast G, Ehrenfeld M, Sturzenbaum SR, Kolk A. Fluorescence-guided bone resection in bisphosphonate-related osteonecrosis of the jaws: first clinical results of a prospective pilot study. *J Oral Maxillofac Surg*. 2011;69(1):84-91.
- Poh CF, Ng SP, Williams PM, Zhang L, Laronde DM, Lane P, Macaulay C, Rosin MP. Direct fluorescence visualization of clinically occult high-risk oral premalignant disease using a simple hand-held device. *Head Neck*. 2007;29(1):71-76.
- Wang CY, Chiang HK, Chen CT, Chiang CP, Kuo YS, Chow SN. Diagnosis of oral cancer by light-induced autofluorescence spectroscopy using double excitation wavelengths. *Oral Oncol*. 1999;35(2):144-150.
- Svistun E, Alizadeh-Nederi R, El-Naggar A, Jacop R, Gillenwater A, Richards-Kortum R. Vision enhancement system for detection of oral cavity neoplasia based on autofluorescence. *Head Neck*. 2004;26(3):205-215.
- Onizawa K, Okamura N, Saginova H, Yoshida H. Characterization of autofluorescence in oral squamous cell carcinoma. *Oral Oncol*. 2003;39(2):150-156.
- Guthrie D, Peacock ZS, Sadow ZS, Dodson TB, August M. Preoperative incisional and intraoperative frozen section biopsy techniques have comparable accuracy in the diagnosis of benign intraosseous jaw pathology. *J Oral Maxillofac Surg*. 2012. Epub ahead of print

11. Shear M, Pindborg JJ. Verrucous hyperplasia of the oral mucosa. *Cancer*. 1980;46(8):1855-1862.
12. Rajendran R, Sugathan CK, Augustine J, Vasudevan DM, Vijayakumar T. Ackerman's tumour (Verrucous carcinoma) of the oral cavity: a histopathologic study of 426 cases. *Singapore Dent J*. 1989;14(1): 48-53.
13. Jacobson S, Shear M. Verrucous carcinoma of the mouth. *J Oral Pathol*. 1972;1(2): 66-75.
14. Walvekar RR, Chaukar DA, Deshpande MS, Pai PS, Chaturvedi P, Kakade A, Kane SV, D'Cruz AK. Verrucous carcinoma of the oral cavity: A clinical and pathological study of 101 cases. *Oral Oncol*. 2009;45(1): 47-51.
15. Gal AA, Cagle PT. The 100-year anniversary of the description of the frozen section procedure. *JAMA*. 2005;294(24): 3135-3137.
16. Zheng JW, Song XY, Nie XG. The accuracy of clinical examination versus frozen section in the diagnosis of parotid masses. *J Oral Maxillofac Surg*. 1997;55(1): 29-31.
17. Huff K, Stark PC, Solomon LW. Sensitivity of direct tissue fluorescence visualization in screening for oral premalignant lesions in general practice. *Gen Dent*. 2009; 57(1): 34-38.