

Gingival Changes in a Drug-Induced Gingival Overgrowth Patient Using Tacrolimus: A Case Report

Neslihan Nal Acar¹, Leyla Kuru², Ulku Noyan³

¹Sancaktepe Center of Mouth and Tooth Health, Istanbul - Turkey

²Marmara University, Department of Periodontology, Dental Faculty, Istanbul - Turkey

³Acibadem Hospital, Department of Mouth and Tooth Health, Istanbul - Turkey

Yazışma Adresi / Address reprint requests to: Neslihan Nal Acar
Sancaktepe Center of Mouth and Tooth Health, Istanbul - Turkey
Elektronik posta adresi / E-mail address: neslihanal@hotmail.com
Kabul tarihi / Date of acceptance: 30 Kasım 2014 / November 30, 2014

ÖZET

İlaca bağlı dişeti hiperplazisinde takrolimusa bağlı değişimler: Olgu raporu

Bu vaka raporu, kliniğimize dişeti büyümesi şikayetiyle başvuran 33 yaşında, kadın, böbrek transplantasyon hastasını sunmaktadır. Klinik ve radyografik muayeneyi takiben, siklosporin A ve nifedipine bağlı dişeti hiperplazisinin eşlik ettiği kronik periodontitis teşhisi koyulmuştur. Başlangıç periodontal tedavinin yanında siklosporin A tacrolimusa değiştirilmiş, nifedipin kullanımına devam edilmiştir. 3 ayda klinik parametrelerde önemli gelişmeler görülmüştür. Tacrolimus kullanımından 2 ay sonra ortaya çıkan ve alt ve üst küçük azı bölgelerinde çift taraflı olarak gözlenen ülser lezyonlar histopatolojik olarak incelenmiş ve spesifik olmayan ülserasyon olarak değerlendirilmiştir. Lezyonlar tacrolimus dozu azaltıldıktan 2 ay sonra kaybolmuştur. Bu vaka raporunda, kronik periodontitis ve dişeti hiperplazisi görülen böbrek transplantasyon hastası, diştaşı temizliği ve kök yüzeyi düzleştirmeye birlikte siklosporinin tacrolimusa değiştirilmesiyle tedavi edilmiştir. Dişetindeki ülserasyonların tacrolimus kullanımından kaynaklanabileceği düşünülmüştür.

Anahtar sözcükler: Dişeti büyümesi, siklosporin A, takrolimus

ABSTRACT

Gingival changes in a drug-induced gingival overgrowth patient using tacrolimus: a case report

This case report presents a 33 year-old female renal transplant recipient who presented to our clinic with her chief complaint of gingival overgrowth. Following clinical and radiographic examinations, she was diagnosed with chronic periodontitis accompanied by cyclosporin A and nifedipine-induced gingival overgrowth. Initial periodontal therapy and replacement of cyclosporin A with tacrolimus, with continued nifedipine usage, were performed. Marked improvements in clinical parameters were observed within 3 months. Bilateral ulcerated lesions which were observed on attached gingiva of the upper and lower premolar regions 2 months after commencement of tacrolimus usage, were histopathologically examined and diagnosed with nonspecific ulcerations. These lesions disappeared within 2 months after the dose of tacrolimus was decreased. In this case report, a renal transplant patient with chronic periodontitis and gingival overgrowth was treated with scaling/root planning and conversion from cyclosporin A to tacrolimus. Ulcerations on the gingiva were assumed to have resulted from tacrolimus usage.

Key words: Gingival overgrowth, cyclosporin A, tacrolimus

INTRODUCTION

Gingival overgrowth (GO), may represent an adverse response to certain drug groups, including cyclosporin A (CsA), an immunosuppressant agent used to inhibit organ rejection after transplantation (1,2). It has possible adverse side effects, including nephrotoxicity, hypertension, and GO (1) of which incidence varies between 6 to 81% (3).

In addition to CsA, nifedipine is prescribed to control hypertension. The incidence and severity of GO is increased in patients medicated with both agents (2). To avoid side effects of CsA, tacrolimus has been proposed. Although a link between tacrolimus and GO has been

reported (4), studies have suggested that tacrolimus alone does not induce GO (5,6,7).

CASE REPORT

A 33-year-old female nonsmoker kidney transplant recipient presented to our clinic with a chief complaint of overgrown gingiva. She was medicated with CsA (75 mg/day), nifedipine (120 mg/day), doxazosin (8 mg/day), mycophenolate mophethyl (1500 mg/day), allopurinol (150 mg/day), and lansoprazol (30 mg/day). She stated that she was diagnosed with hypertension, and after nine months, renal dysfunction was diagnosed. She underwent

a kidney transplantation operation 6 years after diagnosis and she had been using drugs stated above for 2 years.

Upon her arrival at our clinic, thorough dental, periodontal and radiographic examinations were performed. Clinically, plaque and calculus accumulations were present on the teeth. The mean plaque score of lower anterior region was 2.4 and whole mouth 1.7 (8). Bleeding on probing scores were 66% for the lower anterior and 35% for the full mouth, with mean probing depth of 2.83 mm for the lower anterior region and 2.24 mm for the full mouth. GO was more severe in the mandibular anterior region, with values of 2.4 for the lower anterior region and 1.7 for the full mouth (Fig.1a)(9). Tooth decay was not detected. The teeth with number 37, 47, 26, 17 were missing. She had difficulty in chewing and grinding food because her lower removable partial denture no longer fit. Radiographic examination revealed minimal horizontal bone loss (Fig.1b). She was diagnosed with chronic periodontitis accompanied by CsA and nifedipine-induced GO.

Consultation with her physician and initial periodontal therapy were planned. After consultation, her physician

replaced CsA with tacrolimus (4 mg/day), the sera level of tacrolimus was 5.5 ng/ml. Nifedipine treatment was not changed. Nonsurgical periodontal therapy consisted of scaling/root planning under antibiotic prophylaxis was started after consultation and repeated once a week for 1 month. Then recall and control sessions were repeated

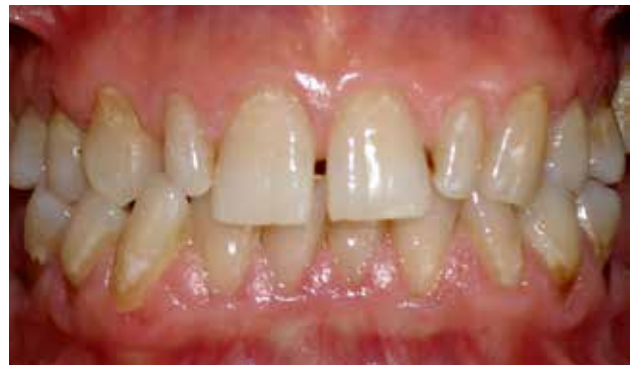

Figure 2: Clinical view 3 months after initial periodontal therapy.

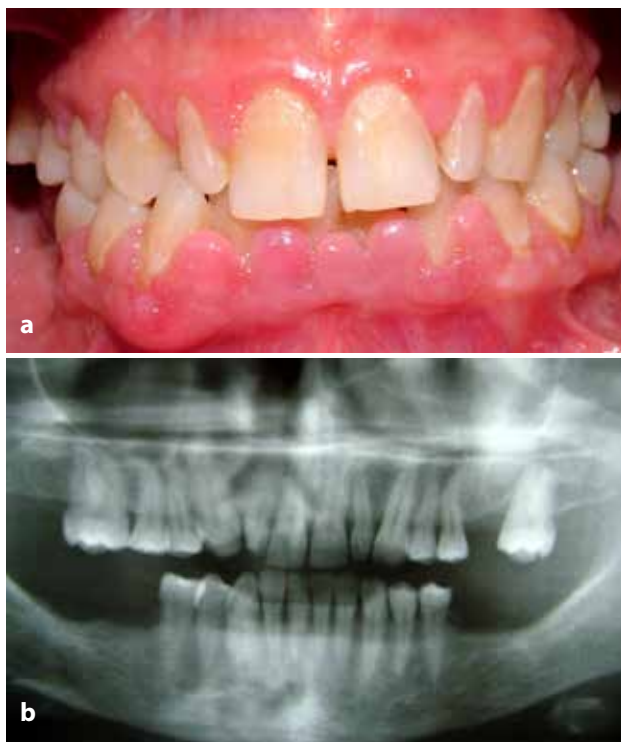

Figure 1: (a) Clinical view on the day the patient presented. (b) Panoramic radiography showing minimal horizontal bone loss.

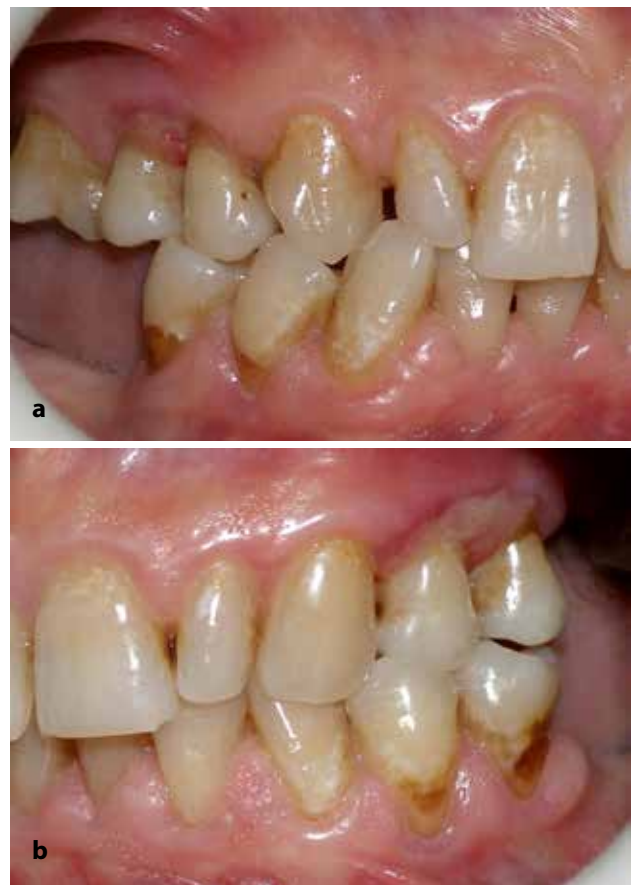

Figure 3: Ulcerated lesions on the (a) right and (b) left premolar regions of the attached gingiva.

once over a 2-week period. A follow-up assessment at 3 months revealed marked improvement: full-mouth plaque score was reduced to 0.8, bleeding on probing to 30%, probing depth to 0.63 mm, and GO score to 1.2 (Fig. 2). Furthermore, in the lower anterior region her GO score was 1.7. There was no need for surgical intervention. The patient was scheduled for control sessions once every 3 months and maintained during a 2.5 year follow-up period.

Four months after therapy, the patient presented to our clinic with a complaint of sensitivity during brushing. Three weeks prior to this visit, her physician had increased the dose of tacrolimus from 4 mg to 5 mg per day. The sera level of tacrolimus was 4.7 ng/ml. There were bilateral ulcerated lesions on the attached gingiva of both the upper and lower premolar regions (Figs. 3a and b). A soft toothbrush was suggested to the patient in order to reduce her complaint during brushing and to prevent deterioration of her oral hygiene. On further consultation with her physician, the dose was decreased to alternating dosages between 4 mg and 5 mg per day. The sera level of tacrolimus has become 4.3 ng/ml. Laboratory evaluations of complete blood counts, peripheral spreading and serum gave normal results (Tables 1, 2, 3). Smear samples from the lesions, palate, and dorsum of the tongue were taken to check for the presence of *Candida* species, given

Table 1: Whole blood evaluation data

Parameter	Result	Normal range
WBC	7.8	4.0-10.0
NE%	60.0	37.0-73.0
LY%	32.8	20.0-50.0
MO%	6.3	2.5-10.0
EO%	0.7	0.5-11.0
BA%	0.2	0.0-2.0
NE#	4.7	1.4-6.2
LY#	2.6	1.2-3.1
MO#	0.5	0.0-0.7
EO#	0.1	0.0-0.7
BA#	0.0	0.0-0.2
RBC	4.24	3.5-5.7
HGB	12.6	12.0-17.0
HCT	37.3	36.0-50.0
MCV	88.0	82.0-97.0
MCH	29.9	27-34
MCHC	33.9	32.0-36.0
RDW	13.2	11.6-16.5
PLT	210	150.0-440.0
MPV	8.0	7.4-11.0
PCT	0.168	
PDW	17.5	

Table 2: Serum evaluation data

Parameter	Result	Normal range
Glucose	92	70-110
BUN	19	6-23
Creatinine	1.10	0.5-1.1
Uric Acid	5.8	3.4-7
AST(GOT)	14	10-37
ALT(GPT)	12	10-40
Alkaline Phosphatase	258	0-270
Sodium	142	138-147
Potassium	3.52	3.5-5.3
Chloride	103	98-108

Table 3: Peripheral spreading data

Rod	3
Neutrophil	62
Lymphocyte	28
Eosinophil	-
Monocyte	7
Basophil	-
Erythrocyte morphology	Normochromic, normocytic
Reticulocyte	-
Platelets	Normal

that immunosuppression may result in *Candida* infections. However, the result was negative. Histopathological analysis of the gingival sample stained with hematoxylin and eosin revealed nonspecific ulceration (Fig.4 and 5). These lesions disappeared within 2 months after the dose of tacrolimus was decreased (Figs. 6a and b).

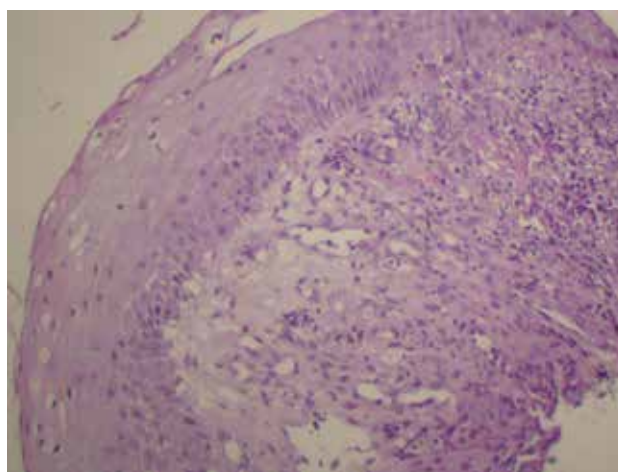


Figure 4: Light microscopic observation showing keratinized squamous epithelium and granulation tissue. Specific inflammation findings are not seen. (original magnification x 200, haematoxylin & eosin)

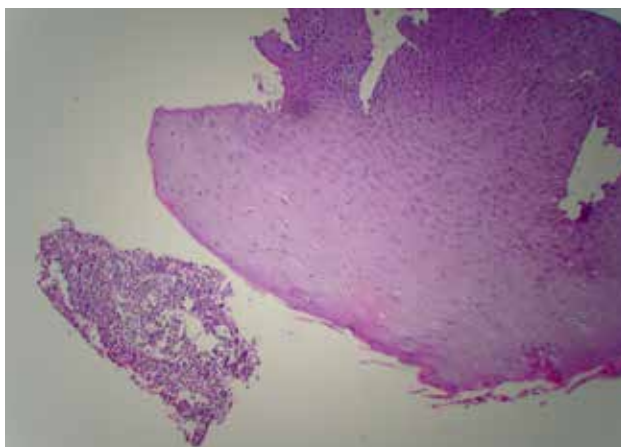


Figure 5: Light microscopic observation showing leucocytic exuda and isolated hyperplastic squamous epithelium. (original magnification x 200, haematoxylin & eosin)

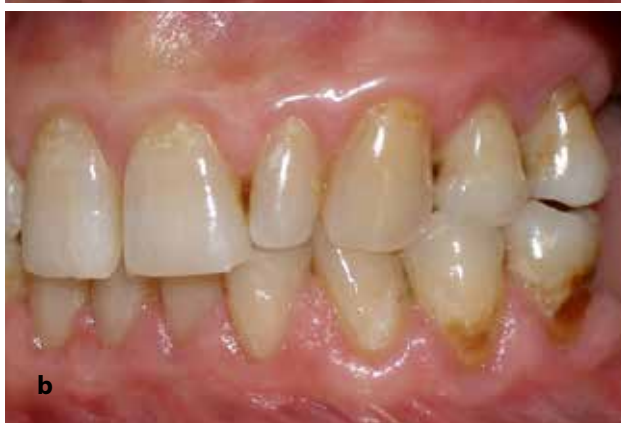
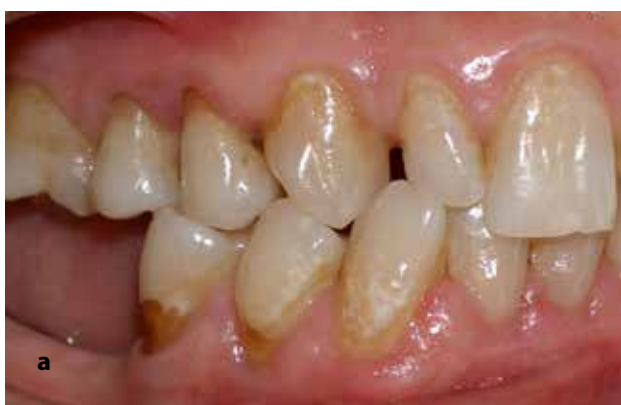
Figure 6: Clinical view from the (a) right and (b) left side after the ulcerated lesions had disappeared.

DISCUSSION

It has been reported that following the conversion from CsA to tacrolimus, a reduction or resolution of mild

to moderate GO is seen within a few months (5). Medication with both a calcium channel blocker and CsA has been shown to increase GO (2,6). Our patient was using both of the drugs; her physician agreed to change from CsA to tacrolimus but refused to change nifedipine treatment.

In the treatment of drug-induced GO, proper plaque control and subgingival instrumentation should be the first step (3,10). In the present case, the patient's high plaque score with 72% may also have had a detrimental effect, as a positive correlation between gingival inflammation and the development of GO has been suggested (11). Considering the slow maturation of soft tissues, the need for additional surgical intervention should be evaluated only after nonsurgical periodontal therapy and at least a 1-year maintenance phase (3,10). The outcome in our case was satisfactory. The patient persisted in showing very mild level of GO, possibly associated with continued nifedipine usage.

To our knowledge, this is the first case report of tacrolimus-associated ulcerations on the attached gingiva. Oral lesions associated with tacrolimus have been described (12, 13). The first reported case about tacrolimus-associated oral ulcers was a liver transplantation patient who had complaints of multiple recurrent oral ulcers, dysphagia, and severe oral pain, which did not respond to any treatment over 3 years. Remission occurred after the dose of tacrolimus was decreased (13). The lesions were in the oral mucosa while in our case the lesions were in attached gingiva. Besides, our patient did not have dysphagia and severe pain and the reduction of tacrolimus dose resulted in the remission of the ulcers in two months. The second case was a heart transplantation patient who had painful aphthoid buccal mucosa ulcerations, which revealed no particular etiology on biopsy (12). The authors mentioned about several arguments like absence of past history of apthae, anatomo-clinical aspect of the lesion differing from that of common apthae and absence of another etiology, suggesting that buccal ulcerations may result from the toxicity of tacrolimus.

The ulcerations in our case were differentiated from aphthous and herpetic lesions by their clinical appearance. Besides, both herpetic and aphthous lesions often present with prodromal symptoms such as fever, anorexia, irritability, malaise and headache (14), our patient had none of them. Therefore, we also assumed that the

ulcerations were a result of the toxicity of tacrolimus.

In conclusion, nonsurgical periodontal therapy followed by regular maintenance therapy and conversion from CsA to tacrolimus was effective in diminishing gingival inflammation and reducing the necessity of surgical intervention in our patient with CsA- and nifedipine-induced GO. In addition, gingival ulcers may be

a tacrolimus-associated side effect, as they disappeared when the dosage was reduced.

Acknowledgement: We thank Dr. Giovanni Lodi for reviewing this manuscript and Dr. Önder Peker for preparing and examining the biopsy sample. The authors report no conflicts of interest.

REFERENCES

1. Prabhu A, Mehta DS. A morphologic comparison of gingival changes influenced by cyclosporin and tacrolimus in rats. *J Periodontol.* 2006; 77: 265-270.
2. O'Valle F, Mesa F, Aneiros J, Gomez-Morales M, Lucena MA, Ramirez C. Gingival overgrowth induced by nifedipine and cyclosporin a. Clinical and morphometric study with image analysis. *J Clin Periodontol.* 1995; 22: 591-597.
3. Pernu HE, Pernu LMH, Knuuttila MLE. Effect of periodontal treatment on gingival overgrowth among cyclosporin A treated renal transplant recipients. *J Periodontol.* 1993; 64: 1098-1100.
4. Adams CKS, Famili P. A study of the effects of the drug FK506 on gingival tissues. *Transplant Proceed.* 1991; 23: 3193-3194.
5. James JA, Jamal S, Hull PS, Macfarlane TV, Campbell BA, Johnson RWG et al. Tacrolimus is not associated with gingival overgrowth in renal transplant patients. *J Clin Periodontol.* 2001; 28: 848-852.
6. Spolidorio LC, Spolidorio DM, Massucato EM, Neppelenbroek KH, Campanha NH, Sanches MH. Oral health in renal transplant recipients administered cyclosporin A or tacrolimus. *Oral Dis.* 2006; 12: 304-314.
7. Asante-Korang A, Boyle GJ, Webber SA, Miller SA, Fricker FJ. Experience of FK506 immune suppression in pediatric heart transplantation: a study of long-term adverse effects. *J Heart Lung Transplant.* 1996; 15: 415-422.
8. Silness J, Løe H. Periodontal disease in pregnancy. II-Correlation between oral hygiene and periodontal condition. *Acta Odontol Scand.* 1964; 22: 121-135.
9. Seymour RA, Smith DG, Turnbull DN. The effects of phenytoin and sodium valproate on the periodontal health of adult epileptics patients. *J Clin Periodontol.* 1985; 12: 413-419.
10. Seymour RA, Ellis JS, Thomanson JM. Risk factors for drug-induced gingival overgrowth. *J Clin Periodontol.* 2000; 27: 217-223.
11. Aimetti M, Romano F, Debernardi C. Effectiveness of periodontal therapy on the severity of cyclosporin A-induced gingival overgrowth. *J Clin Periodontol.* 2005; 32: 846-850.
12. Macario-Barrel A, Tanasescu S, Courville P, Redonnet M, Cordel N, Lauret P et al. Mouth ulcers in patients receiving tacrolimus. *Ann Dermatol Venereol.* 2001; 128: 1327-1329.
13. Hernandez G, Jimenez C, Arriba L, Moreno E, Lucas M. Resolution of oral ulcerations after decreasing the dosage of tacrolimus in a liver transplantation recipient. *Oral Surg Oral Med Oral Pathol Oral Radiol Endod.* 2001; 92: 526-531.
14. Kolokotronis A, Doumas S. Herpes simplex virus infection, with particular reference to the progression and complications of primary herpetic gingivostomatitis. *Clin Microbiol Infect.* 2006; 12: 202-211.