

Expression of BMP-4 in dentigerous cyst and ameloblastoma: Is it a differentiation measure?

Purpose

This study aimed to determine the expression of Bone Morphogenic Protein-4 (BMP-4) in dentigerous cyst (DC), unicystic-ameloblastoma (UA), and Multicystic-ameloblastoma (MA), and assess whether this marker can be a differentiation measure.

Materials and Methods

This study included 30 DC, 30 UA, and 30 MA blocks if the histopathologic diagnosis of the lesion was definitive, the clinical information and medical records were complete, and the microscopic slides and the paraffin block were available. Age, gender, and location of the lesion were recorded. The samples were analyzed after the immunohistochemical staining (Envision technique). BMP-4 marker was evaluated and reported using Intensity Score (IS), Proportional Score (PS), and Total score (TS). The data were analyzed using SPSS version 21.0. Kruskal-Wallis and Mann-Whitney U tests were applied at the significance level of 0.05.

Results

In this study, DCs, UA, and MA had a significant tendency to occur in males compared to females ($p < 0.001$, $p < 0.001$, and $p < 0.001$ respectively), and in the mandible compared to the maxilla ($p = 0.02$, $p = 0.024$, and $p = 0.02$ respectively). The epithelial IS was significantly different among three lesions ($p < 0.001$). IS was higher in MA than UA and DC ($p < 0.001$ and $p = 0.006$, respectively). The IS was not significantly different among the three lesions in connective tissue and around micro-vessels ($p = 0.3$ and $p = 0.26$ respectively). The PS in the epithelium and connective tissue of DC, UA, and MA had no statistical difference ($p = 0.549$ and $p = 0.540$ respectively). The epithelial TS was statistically different among DC, UA, and MA ($p < 0.001$). The TS was higher in UA than MA and DC ($p = 0.004$ and $p < 0.001$ respectively).



Conclusion

The expression of BMP-4 in the epithelium was higher in ameloblastoma compared to DCs. BMP-4 is a potential measure to differentiate different types of ameloblastoma and dentigerous cyst. The differentiation of these lesions is important as the right treatment plan changes according to the diagnosis.

Keywords: Ameloblastoma, dentigerous cyst, BMP4, Histopathological assessment, staining

Introduction

With a prevalence of 14 to 24%, DC is the second most common odontogenic cyst, assumed to originate from the dental follicle, however, its pathogenesis is still unclear (1–3). This cyst is frequently associated with the crown of an impacted, embedded, or an unerupted permanent tooth and is rarely associated with an odontoma, a developing tooth, or a deciduous tooth (2,3). DC mostly involve third molars followed by maxillary canines, mandibular premolars, and mandibular canines (3). DCs may lead to displacement and root resorption of associated or adjacent teeth if larger than

Soudabeh Sargolzaei¹ ,
Dina Maleki² ,
Maryam Zohary³ 

ORCID IDs of the authors: S.S. 0000-0002-6452-4909;
D.M. 0000-0002-8492-618X; M.Z. 0000-0002-4287-2806

¹Department of Pathology, School of Dentistry, Shahid Beheshti University of Medical Sciences, Tehran, Iran

²Student Research Committee, School of Dentistry, Guilan University of Medical Sciences, Rasht, Iran

³Department of Periodontics, School of Dentistry, Guilan University of Medical Sciences, Rasht, Iran

Corresponding Author: Maryam Zohary

E-mail: maryamzohary@yahoo.com

Received: 27 March 2021

Revised: 30 May 2021

Accepted: 13 June 2021

DOI: 10.26650/eor.2022903844

2 cm or getting infectious (1). Generally, DCs are asymptomatic and are detected during routine radiographic examination with the appearance of a well-defined unilocular lesion (2, 3).

Ameloblastoma represents 19% of all odontogenic tumors (4). Ameloblastoma is a locally invasive benign odontogenic tumor derived from remaining tooth-forming components and the epithelial lining of dentigerous cysts (3, 4). The tumor presents as desmoplastic, peripheral, uni-cystic, or multi-cystic forms (4). UA with a prevalence of 5 - 15% of all reported cases, occurs in the young population in their 2nd or 3rd decade and may appear as a unilocular radiolucency with scalloped or lobulated border in radiographic images (4, 5). MA is more common in a wider age range compared to UA and is more aggressive (4).

The histopathological confusion between DC and UA is possible and has long been known. However, the diagnosis is important because of different treatment plans. DCs and UAs can be treated with enucleation or curettage, while other types of ameloblastoma require resection with an adequate margin of normal tissue (6, 7).

Bone Morphogenic Protein (BMP) is a growth factor and participates in cellular proliferation, extracellular matrix production, and differentiation of neoplastic tissues (8, 9). This study aimed to determine if BMP-4 can be used as a factor to differentiate odontogenic cysts such as DC from odontogenic tumors like UA and MA. The null hypothesis was that there are no differences in the BMP-4 expressions of DC, UA and MA.

Materials and Methods

This was a retrospective cross-sectional descriptive-analytic study.

Ethical statement

This project has been reviewed and approved by the Ethical Committee of Shahid Beheshti University of Medical Sciences, Tehran, Iran. (IR.SBMU.REC.1395.330)

Specimen selection

The microscopic slides were included in the study if the histopathologic diagnosis of the lesion was definitive, the clinical information and medical records were complete, and the microscopic slides and the paraffin block were available. The samples were excluded if the diagnosis after re-examination did not confirm the previous diagnosis and if the tissue sample was not sufficient for immunohistochemical (IHC) analysis.

The biopsies of DC and ameloblastoma from 2010 to 2020 were obtained from the archive of the oral pathology department of the dentistry faculty of Shahid Beheshti University of Medical Sciences. 30 DC, 30 UA, and 30 MA blocks were selected. The samples were re-evaluated by an expert pathologist and the diagnoses were confirmed. Information such as age, gender, and location of the lesion were extracted from the medical records.

Sample size estimation

To calculate the sample size, information about MP4 marker expression by immunohistochemistry was used in the

two groups of dentigerous cyst and odontogenic keratocyst related to the article by Kim *et al.* To do this, a formula suitable for comparing ratios in two independent societies and generalizing it to three groups has been used. Considering the statistical power of 0.975%, the error level of 0.05 and the expression ratio of 30.3 in the Dentigerous group and 97.1 in the Odontogenic keratocyst group, the minimum sample size of 23 was obtained. Which was considered for each group of 30 to achieve higher power (20) Formula is presented in Figure 1.

$$n_0 = \frac{\left[z_{1-\frac{\alpha}{2}} \cdot \sqrt{2\bar{p}(1-\bar{p})} + z_{1-\beta} \cdot \sqrt{p_1(1-p_1) + p_2(1-p_2)} \right]^2}{(p_1 - p_2)^2} = 15.08 \cong 16$$

$$\bar{p} = \frac{p_1 + p_2}{2}$$

$$n = n_0 \times \sqrt{g-1} = 16 \times \sqrt{2} = 22.63 \cong 23$$

Figure 1. Formula used for sample size calculation.

Specimen preparation and IHC staining

Following these steps, the samples were prepared for the IHC analysis of the BMP-4 marker. 5-micrometer-thick sections were cut from paraffin-embedded tissue blocks and IHC staining of BMP-4 was performed using the Envision technique. To deparaffinize the samples, the tissues were respectively placed in 100% Xylen, 99% alcohol, 96% alcohol, and 25% alcohol for 2-3 minutes. The samples were rinsed with distilled water for 2-3 minutes to remove the alcohol. To deactivate endogen peroxidase, the tissue was covered with a drop of Peroxidase Blocking Reagent (USA thermo TA-262-H222Q) for 10 minutes at room temperature. Then the tissue was immersed in a solution with a PH of 7.6 for 5 minutes. The remaining peroxidase blocking reagent was rinsed twice with distilled water for 2-3 minutes each time. Antigen retrieval was carried out by placing the tissue sample in a plastic Coplin jar containing retrieval solution at PH 6. The jars were then macro-waved for 7 minutes (power of 450 W), and cooled down for 5 minutes, and macro-waved for 15 minutes again (Power of 800 W). The samples were kept at room temperature and were rinsed with Tris Buffered Saline (TBS) solution with a PH of 7.6. Later, the samples were incubated by the primary antibodies for 1-hour and were then rinsed with TBS solution with a PH of 7.6 for 5 minutes. Afterward, the samples were incubated by Primary Antibody Amplifier Quanto (USA Thermo TL-060-QPB) for 10 minutes and rinsed again for 5 minutes with the same solution as the previous step. The samples were incubated with HRP Polymer Quanto (USA Thermo TL-060-QPH) for 10 minutes and rinsed with TBS solution (PH=7.6) for 5 minutes. The samples were immersed in diaminobenzidine (DAB USA Termo TA-222-QH-CX) for 5 minutes until a brownish reaction was observed. The samples were washed with tap water for 5 minutes and placed in distilled water for 5 minutes. Finally, the sections were counterstained with hematoxylin for 30 seconds, and with lithium carbonate for 5 minutes, then rinsed with tap water. The samples were mounted afterward.

Specimens assessment

Squamous Cell Carcinoma (SCC) sections were used as a positive control and tumoral sections which were incubated with Tris-buffered saline (TBS) instead of primary antibodies were used as a negative control.

The immune-expression of BMP-4 in microscopic slides were evaluated under a light microscope at x100 magnification. The staining was considered positive if the cytoplasm of tumoral cells were brown stained (Figure 1-3).

Intensity score (IS) was recorded as score 0 (No staining or <10% staining), score 1 (incomplete membranous staining of weak to moderate intensity in 10%< of the cells), score 2 (complete membranous staining of moderate intensity in 10%< of the cells), and score 3 (complete membranous staining of strong intensity in 10%< of the cells) for the assessment of BMP-4 marker in the epithelium, connective tissue, and around micro-vessels. Proportional Score (PS) of BMP-4 marker was measured as score 0 (no stained cell), score 1 (<20% stained cells), score 2 (20-80% stained cells), and score 3 (80%< stained cells) in the epithelium and connective tissue. Total score (TS) was reported for epithelium and connective tissue by summing the IS and PS of the BMP-4 marker.

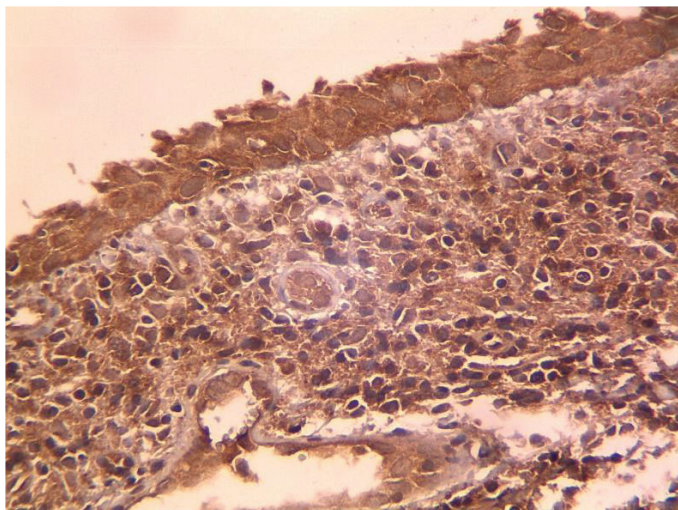


Figure 1. The microscopic view of dentigerous cyst after immunohistochemical staining indicate BMP-4 marker. (×400).

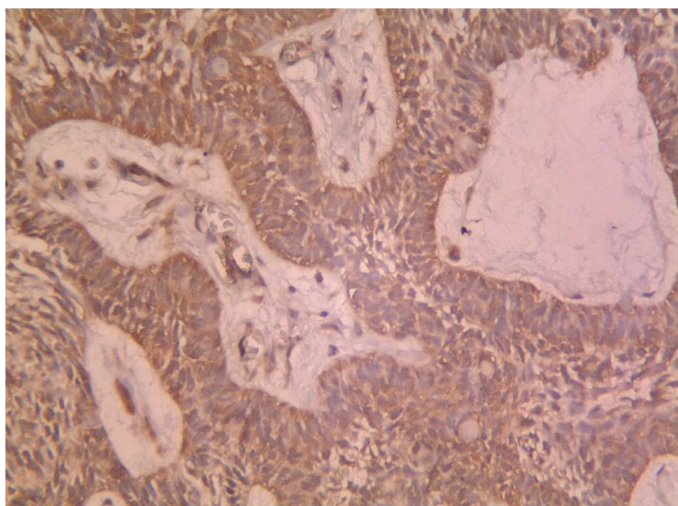


Figure 2. The microscopic view of Unicystic-ameloblastoma after immunohistochemical staining indicate BMP-4 marker. (×400).

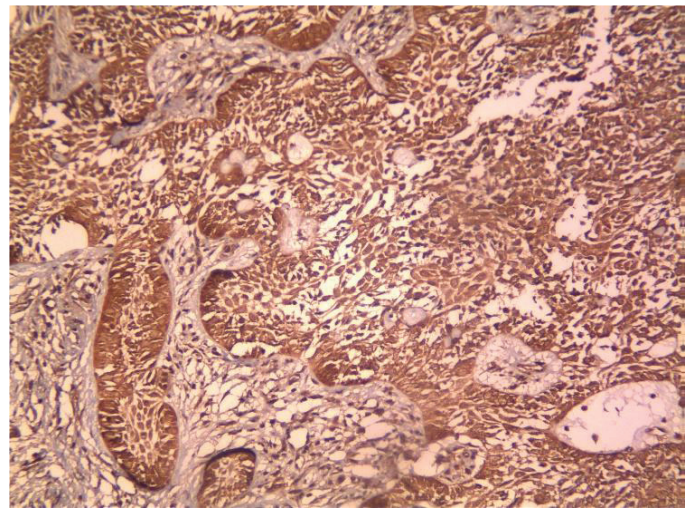


Figure 3. The microscopic view of Multicystic-ameloblastoma after immunohistochemical staining to indicate BMP-4 marker. (×200).

Statistical analysis

The data were imported to Statistical Package for Social Sciences (SPSS) for Windows software, version 21.0 (IBM Corp, Armonk, NY, USA). Frequency was applied to determine the characteristics of the sample. The chi-square test was used to compare the demographic distribution among DC, UA, and MA. Since the data distribution was not normal, the nonparametric Kruskal-Wallis one-way analysis of variance by ranks and Mann-Whitney U tests were used for the multiple and pairwise comparisons, respectively. The confidence interval was set to 95% and the significance level was set at 0.05.

Results

In this study, the expression of BMP-4 was assessed in 30 DC, 30 UA, and 30 MA microscopic slides using IHC analysis. The data distribution is presented in table1. According to intra-group comparison, no statistical difference was found among the three study groups in terms of age, gender, and the location of the lesions ($P=0.1$, $P=0.1$ and $P=0.1$ respectively). The mean age of patients was 31.9 ± 17.8 , 30.7 ± 17.9 , and 39.6 ± 16.9 in DC, UA, and MA groups, respectively.

The prevalence of the pathology was higher in males than females in DC, UA, and MA study groups ($P<0.001$, $P<0.001$, and $P<0.001$ respectively), and higher in the mandible than the maxilla ($P=0.02$, $P=0.024$, and $P=0.02$ respectively). The IHC analysis of BMP-4 markers in the epithelium, connective tissue, and micro-vessels of 3 lesions is reported in Table2-4.

The IS of BMP-4 marker in the epithelium was significantly different among the three lesions ($P<0.001$, $df=2$, $\chi^2=40.947$). The Mean of IS was 26.72 in DC, 42.18 in UA, and 67.6 in MA. MA had a significantly higher IS compared to UA and DC ($P<0.001$ and $P=0.006$, respectively). Also, the IS in UA lesions was significantly higher than in DC lesions ($P<0.001$). The differences of IS in the connective tissue and the micro-vessels of DC, UA, and MA lesions were not statistically significant ($P=0.389$ and $P=0.26$, respectively).

The PS of the BMP-4 marker in the epithelium and connective tissue was not statistically different among the three lesions ($P=0.549$ and $P=0.540$, respectively).

The TS of BMP-4 marker in the epithelium was statistically different in DC, UA, and MA lesions ($P < 0.001$, $df = 2$, $\chi^2 = 23.857$). The results showed that UA had a significantly higher TS compared to MA and DC ($P = 0.004$ and $P < 0.001$ respectively), and MA had a significant higher TS compared to DC ($P < 0.001$). The difference of TS was not significant between DC, UA, and MA lesions in connective tissue ($P = 0.424$).

ber of odontogenic and non-odontogenic cysts in a 9-year study. In their study, out of 122 patients with DCs, 56 were women (45.6%) and 66 (54.1%) were men. Similarly, Ramachandra *et al.* (11) studied the prevalence of odontogenic cysts over 5 years in India. In their study, 24 of the 45 DCs samples were male (53.33%) and 21 were female (46.67%). In agreement, Meningaud *et al.* (12) reported that among

Table 1. The data distribution of patients with Dentigerous Cyst, Unicystic Ameloblastoma and Multicystic Ameloblastoma according to gender and the location of the lesion in percent (number).

The type of the lesions	Gender		The location of the lesions	
	Female	Male	Maxilla	Mandible
Dentigerous cyst	36.7% (11)	63.3% (19)	30% (9)	70% (21)
Unicystic Ameloblastoma	23.3% (7)	76.7% (23)	16.7% (5)	83.3% (25)
Multicystic Ameloblastoma	13.3% (4)	87.6% (26)	3.3% (1)	96.7% (29)
Total	24.4% (22)	75.6% (68)	16.7% (15)	83.3% (75)

Table 2. The IS, PS and TS of BMP-4 marker in the epithelium of Dentigerous Cyst, Unicystic Ameloblastoma and Multicystic Ameloblastoma.

The type of the lesions	Intensity Score				Proportional Score			Total Score
	Score 0	Score 1	Score 2	Score 3	Score 1	Score 2	Score 3	
Dentigerous cyst	63.3% (19)	33.3% (10)	0 (0)	3.3% (1)	33.3% (10)	20% (6)	46.7% (14)	30.6
Unicystic Ameloblastoma	0 (0)	20% (6)	60% (18)	20% (6)	16.7% (5)	46.7% (14)	36.7% (11)	62.45
Multicystic Ameloblastoma	23.3% (10)	36.7% (11)	26.7% (8)	3.3% (1)	43.3% (13)	13.3% (4)	43.3% (13)	43.5

Table 3. The IS, PS and TS of BMP-4 marker in the connective tissue of Dentigerous Cyst, Unicystic Ameloblastoma and Multicystic Ameloblastoma.

The type of the lesions	Intensity Score				Proportional Score			Total Score
	Score 0	Score 1	Score 2	Score 3	Score 1	Score 2	Score 3	
Dentigerous cyst	66.7% (20)	23% (7)	10% (3)	0 (0)	80% (24)	20% (6)	0 (0)	43.06
Unicystic Ameloblastoma	53.6% (16)	23% (7)	20% (6)	3.3% (1)	70% (21)	30% (9)	0 (0)	49.92
Multicystic Ameloblastoma	66.7% (20)	20% (6)	10% (3)	3.3% (1)	76.7% (23)	23.3% (7)	0 (0)	43.52

Table 4. The IS of BMP-4 marker around the micro-vessels of Dentigerous Cyst, Unicystic Ameloblastoma and Multicystic Ameloblastoma.

The type of the lesions	Intensity Score			
	Score 0	Score 1	Score 2	Score 3
Dentigerous cyst	70% (21)	16.7% (5)	13.3% (4)	3.3% (1)
Unicystic Ameloblastoma	56.7% (17)	23% (7)	13.3% (4)	6.7% (2)
Multicystic Ameloblastoma	73.3% (22)	20% (6)	6.7% (10)	0 (0)

Discussion

This study assessed the expression of BMP-4 in DC, UA, and MA microscopic slides. In this study, the occurrence of DC, UA, and MA was significantly higher in males and was more common in the mandible. In terms of gender, Açıkgöz *et al.* (10) found the same results in the Turkish population. Açıkgöz *et al.* (10) investigated the distribution and num-

ber of odontogenic and non-odontogenic tumors in the Brazilian population and reported that 30 of 57 patients were male and 27 were female. Sah *et al.* (14) reported that 5 and 13 of 18 subjects diagnosed with UA were respectively female and male. In contrary to the results of the above-mentioned studies, Olgac *et al.* (15) carried out a study to examine odontogenic tumors over 32 years in Turkey in 2006 and their results showed that out of 133 sam-

ples of ameloblastoma tumors, 58 samples were men and 75 were women. This difference may be associated with the different study populations.

The results of the current study showed that the prevalence of DC, UA, and MA was higher in the mandible compared to the maxilla. Açıkgöz *et al.* (10) also found that 34 samples of DCs were in the maxilla while 88 samples were observed in the mandible. Ramachandra *et al.* (11) reported that 20 of the 45 DCs were located in the maxilla and 25 of them were found in the mandible. Núñez-Urrutia *et al.* (16) evaluated the prevalence of odontogenic cysts in Spain over 10 years and found that among 91 subjects, 63 cysts were located in the mandible and 28 cysts were in the maxilla. Alvelar *et al.* (13) showed that 48 lesions were located in the mandible and 9 lesions were found in the maxilla. Sah *et al.* (14) claimed that 17 samples of 18 UA were located in the mandible and one sample was found in the maxilla. Olgac *et al.* (15) reported that 15 samples of odontogenic tumors were seen in the upper jaw and 118 samples in the lower jaw. Considering the above-mentioned studies, DC and Ameloblastoma are located preferably in the mandible which is confirmed in this study.

BMP-4 is a bone morphogenetic protein belonging to the TGF-B family (17). The absence of BMP-4 leads to severe defects in osteogenesis (17). BMP-4 affects normal epithelial cell differentiation and odontogenic epithelium malignancies through epithelial-mesenchymal reaction, also, results in cytodifferentiation of ameloblastoma histologic subtypes (18). Some studies have evaluated the expression of BMP-4 markers in odontogenic cysts and tumors but no study, up to the authors' knowledge, has compared the expression of BMP-4 marker in DCs and ameloblastoma as a possible measure to differentiate these lesions (19–22).

The study of Kumamoto *et al.* (19) was performed to assess the role of BMPs in the differentiation of odontogenic tumors. 37 samples of ameloblastoma, 6 samples of Adenomatoid odontogenic tumor (AOT), and 5 samples of malignant ameloblastoma were compared to 10 third mandibular molar follicles using RT-PCR, IHC to determine BMP-2, BMP-4, BMP-7 markers, and Osterix, CBFAl, BMPRII, and BMPRI receptors. The results showed that mRNA expression resulting from BMPs and other related molecules are found in all odontogenic tumors.

Kim *et al.* (20) conducted a study to compare the expression of BMP-4 in Odontogenic kerato-cyst (OKC) and DC using IHC and in situ hybridization. The results indicated that BMP-4 had higher expression in OKC compared to DC especially in the recurrent form of OKC. In the current study, also, BMP-4 had higher expression in UA and MA compared to DC.

Ruhin-Poncet *et al.* (21) evaluated the expression of BMPs, Dlx, and Msx in odontogenic epithelial tumors (recurrent ameloblastoma and central calcifying odontogenic cyst (CCOC)) They stated that Dlx, and Msx were found in ameloblastoma unlike CCOC. In contrast, BMP-2 was only found in CCOC while BMP-4 was expressed in both tumors. The findings of Ruhin-Poncet study were in agreement with the current study reporting the expression of BMP-4 in ameloblastoma.

Also, Nascimento *et al.* (9) studied the expression of BMP-2, BMP-4, and their receptors in AOT and ameloblastoma using IHC. In MA, positive correlations were observed between the stromal and parenchymal expression of BMP-2 and between the stromal expression of BMP-2 and BMP-4, as well

as between the stromal expression of BMP-4 and BMP-4 and the stromal and parenchymal expression of BMP-4. In UAs, a correlation was detected between the stromal and parenchymal expression of BMP-4 and between the stromal expression of BMP-4 and BMP-4. In AOTs, analysis of immune-expression in the parenchyma revealed positive correlations between all proteins. BMPs and their receptors play an important role in the differentiation and development of ameloblastoma and AOTs, but may not explain the different biological behaviors of these lesions. The positive correlation observed in AOTs might be related to the formation of mineralized material in this tumor.

Not assessing the relation of clinical behaviors of the lesions and the expressions of BMP-4 is one of the limitations of this study. Also, the expression of BMP-4 was not compared among different types of ameloblastoma.

Conclusion

Considering the limitation of this study, it was found that the expression of BMP-4 in the epithelium was significantly higher in ameloblastoma compared to DCs. However, the difference was not significant in the connective tissue and around the micro-vessels. The IS of the BMP-4 marker was higher in MA compared to UA, while the TS of the BMP-4 marker was higher in the UA compared to MA. According to the findings of this study, it can be concluded that BMP-4 is a potential measure to differentiate different types of ameloblastoma and dentigerous cyst. The differentiation of these lesions is of importance as the right treatment plan changes according to the diagnosis.

Türkçe Özet: Dentigeröz kist ve ameloblastomada bmp-4 ekspresyonu ayrı bir yöntem midir?. Giriş: Bu çalışmanın amacı dentigeröz kist (DK), unistik ameloblastoma (UA) ve Multi-kistik ameloblastoma (MA) olgularında kemik morfolojik protein 4 ekspresyonunu belirlemek ve bu değerlerin lezyonların ayrılmasında yardımcı olup olmayacağını incelemesidir. Gereç ve yöntem: Bu çalışma, lezyonun histopatolojik tanısı kesinleşmiş, klinik bilgileri ve tıbbi kayıtları tam olan ve mikroskopik slaytları ve parafin blokları bulunan 30 DK, 30 UA ve 30 MK bloklarını içeriyordu. Lezyonun yaşı, cinsiyeti ve yeri kaydedildi. Örnekler immünohistokimyasal boyamadan (Envision tekniği) sonra analiz edildi. BMP-4 belirteci Yoğunluk Skoru (IS), Orantılı Skor (PS) ve Toplam Skor (TS) kullanılarak değerlendirildi ve rapor edildi. Veriler SPSS 21.0 versiyonu kullanılarak analiz edildi. Kruskal-Wallis ve Mann-Whitney U testleri 0.05 anlamlılık düzeyinde uygulandı. Bulgular: Bu çalışmada DK'ler, UA ve MA, erkeklerde kadınlara göre (sırasıyla $P<0,001$, $P<0,001$ ve $P<0,001$) ve maksillaya kıyasla mandibulada ($P=0,02$, $P=0,024$ ve $P=0,02$ sırasıyla) daha fazlaydı. Epitelyal IS, üç lezyon arasında önemli ölçüde farklıydı ($P<0,001$). IS, MA'da UA ve DK'den daha yüksekti (sırasıyla $P<0,001$ ve $P=0,006$). Bağ dokusunda ve mikrodamarların çevresindeki üç lezyon arasında IS anlamlı şekilde farklı değildi (sırasıyla $P=0,3$ ve $P=0,26$). DC, UA ve MA'nın epitelindeki ve bağ dokusundaki PS'de istatistiksel bir fark yoktu (sırasıyla $P=0,549$ ve $P=0,540$). Epitelyal TS, DK, UA ve MA arasında istatistiksel olarak farklıydı ($P<0,001$). TS, UA'da MA ve DKden daha yüksekti (sırasıyla $P=0,004$ ve $P<0,001$). Sonuç: Epitelde BMP-4 ekspresyonu DK'lere kıyasla ameloblastomda daha yüksekti. BMP-4, farklı ameloblastom ve dentigeröz kist türlerini ayırt etmek için potansiyel bir ölçüttü. Taniya göre doğru tedavi planı değiştiği için bu lezyonların ayırımı önemlidir. Anahtar Kelimeler: Ameloblastoma, dentigeröz kist, BMP4, Histopatolojik Değerlendirme, Boyama

Ethics Committee Approval: This project has been reviewed and approved by the Ethical Committee of Shahid Beheshti University of Medical Sciences, Tehran, Iran. (IR.SBMU.REC.1395.330)

Informed Consent: Participants provided informed consent.

Peer-review: Externally peer-reviewed.

Author contributions: SS, MZ participated in designing the study. SS, MZ participated in generating the data for the study. SS, MZ participated in gathering the data for the study. DM, MZ participated in the analysis of the data. DM wrote the majority of the original draft of the paper. SS, DM, MZ participated in writing the paper. SS, DM, MZ have had access to all of the raw data of the study. SS, DM, MZ have reviewed the pertinent raw data on which the results and conclusions of this study are based. SS, DM, MZ have approved the final version of this paper. SS, DM, MZ guarantee that all individuals who meet the Journal's authorship criteria are included as authors of this paper.

Conflict of Interest: The authors declared no conflict of interest.

Financial Disclosure: The authors declared that they have received no financial support.

References

- Huang G, Moore L, Logan RM, Gue S. Histological analysis of 41 dentigerous cysts in a paediatric population. *J Oral Pathol Med* 2019;48:74–8. [\[CrossRef\]](#)
- Terauchi M, Akiya S, Kumagai J, Ohya Y, Yamaguchi S. An analysis of dentigerous cysts developed around a mandibular third molar by panoramic radiographs. *Dent J* 2019;7:1–9. [\[CrossRef\]](#)
- Tsironi K, Inglezos E, Vardas E, Mitsea A. Uprighting an impacted permanent mandibular first molar associated with a dentigerous cyst and a missing second mandibular molar — A case report. *Dent J* 2019;7:63–73. [\[CrossRef\]](#)
- Hendra FN, Van Cann EM, Helder MN, Ruslin M, de Visscher JG, Forouzanfar T, et al. Global incidence and profile of ameloblastoma: A systematic review and meta-analysis. *Oral Dis* 2020;26:12–21. [\[CrossRef\]](#)
- Rad FO, Mousavi E, Musapoor N, Maleki D, Khatibi N. Prevalence of C-Shaped Canals in Anterior and Posterior Teeth of Iranian Population Using Cone Beam Computed Tomography. *Avicenna J Dent Res* 2020;12:58–62. [\[CrossRef\]](#)
- Barrett AW, Sneddon KJ, Tighe J V., Gulati A, Newman L, Collyer J, et al. Dentigerous Cyst and Ameloblastoma of the Jaws: Correlating the Histopathological and Clinicoradiological Features Avoids a Diagnostic Pitfall. *Int J Surg Pathol* 2017;25:141–7. [\[CrossRef\]](#)
- Hendra FN, Natsir Kalla DS, Van Cann EM, de Vet HCW, Helder MN, Forouzanfar T. Radical vs conservative treatment of intraosseous ameloblastoma: Systematic review and meta-analysis. *Oral Dis* 2019;25:1683–96. [\[CrossRef\]](#)
- Swarup N, Nayak MT, Chowdhary Z, Mehendiratta M, Khatana S, Choi SJ, et al. Evaluation and immunolocalization of BMP4 and FGF8 in odontogenic cyst and tumors. *Anal Cell Pathol* 2018;2018:1–9. [\[CrossRef\]](#)
- Nascimento MAB, Nonaka CFW, Barboza CAG, Freitas R de A, Pereira Pinto L, Souza LB de. Immunoeexpression of BMP-2 and BMP-4 and their receptors, BMPR-IA and BMPR-II, in ameloblastomas and adenomatoid odontogenic tumors. *Arch Oral Biol* 2017;73:223–9. [\[CrossRef\]](#)
- Açikgöz A, Uzun-Bulut E, Özden B, Gündüz K. Prevalence and distribution of odontogenic and nonodontogenic cysts in a Turkish population. *Med Oral Patol Oral Cir Bucal* 2012;17:1–7. [\[CrossRef\]](#)
- Prashanth Ramachandra, Prathima Maligi and HR. A cumulative analysis of odontogenic cysts from major dental institutions of Bangalore city: A study of 252 cases. *J Oral Maxillofac Pathol* 2011;15:1–5. [\[CrossRef\]](#)
- Meningaud JP, Oprean N, Pitak-Arnop P, Bertrand JC. Odontogenic cysts: a clinical study of 695 cases. *J Oral Sci* 2006;48:59–62. [\[CrossRef\]](#)
- Avelar RL, Antunes AA, de Santana Santos T, de Souza Andrade ES DE. Odontogenic tumors: clinical and pathology study of 238 cases. *Brazilian J Otorhinolaryngol* 2008;74:668–73. [\[CrossRef\]](#)
- Sah P, Menon A, Kamath A, Chandrashekar C, Carnelio S, Radhakrishnan R. Role of immunomarkers in the clinicopathological analysis of unicystic ameloblastoma. *Dis Markers* 2013;35:481–8. [\[CrossRef\]](#)
- Olgac V, Koseoglu BG, Aksakalli N. Odontogenic tumours in Istanbul: 527 cases. *Br J Oral Maxillofac Surg* 2006;44:386–8. [\[CrossRef\]](#)
- Núñez-Urrutia S, Figueiredo R, Gay-Escoda C. Retrospective clinicopathological study of 418 odontogenic cysts. *Med Oral Patol Oral Cir Bucal* 2010;15:767–73. [\[CrossRef\]](#)
- An L, Shi Q, Zhu Y, Wang H, Peng Q, Wu J, Cheng Y, Zhang W, Yi Y, Bao Z, Zhang H. Bone Morphogenetic Protein 4 (BMP4) promotes hepatic glycogen accumulation and reduces glucose level in hepatocytes through mTORC2 signaling pathway. *Genes & Diseases* 2020;8:531–44. [\[CrossRef\]](#)
- Galeone A, Adams JM, Matsuda S, Presa MF, Pandey A, Han SY, et al. Regulation of BMP4/Dpp retrotranslocation and signaling by deglycosylation. *Elife* 2020;9:1–32. [\[CrossRef\]](#)
- Kumamoto H OK. . Expression of bone morphogenetic proteins and their associated molecules in ameloblastomas and adenomatoid odontogenic tumors. *Oral Dis* 2006;12:163–70. [\[CrossRef\]](#)
- Kim SG, Yang BE, Oh SH, Min SK, Hong SP CJ. The differential expression pattern of BMP-4 between the dentigerous cyst and the odontogenic keratocyst. *J Oral Pathol Med* 2005;34:178–83. [\[CrossRef\]](#)
- Ruhin-Poncet B, Ghoul-Mazgar S, Hotton D, Capron F, Jaafoura MH, Goubin G, et al. Msx and Dlx homeogene expression in epithelial odontogenic tumors. *J Histochem Cytochem* 2009;57:69–78. [\[CrossRef\]](#)
- Nascimento MA, Nonaka CF, Barboza CA, de Almeida Freitas R, Pinto LP de SL. Immunoeexpression of BMP-2 and BMP-4 and their receptors, BMPR-IA and BMPR-II, in ameloblastomas and adenomatoid odontogenic tumors. *Arch Oral Biol* 2017;73:223–9. [\[CrossRef\]](#)