

## Management of the so called isolated ACL rupture

G. Schippinger<sup>(1)</sup>, M. Fellinger<sup>(2)</sup>, J. Passler<sup>(2)</sup>, G. Peicha<sup>(1)</sup>

### Sözde izole ön çapraz bağ rüptürünün tedavisi

Diz yaralanmalarının tedavisinden amaç menisküslerin korunması, rotasyonel stabilite ve erken posttravmatik osteoartritin önlenmesidir. ÖÇB'in izole rüptürü çoğu vakada sadece orta derecede instabiliteye yol açar, ek yaralanmalar instabiliteyi sıklıkla artırır. Dolayısıyla kesin teşhise çok önem vermekteyiz.

Özellikle posteromedial köşenin rekonstrüksiyonu çok önemlidir. Retrospektif çalışmalarımızda 104 akut ÖÇB rüptürlü vakayı gözden geçirdik ve rutin olarak yaptığımız artroskopik tetkiklerde % 74'ünde ek lezyon saptadık. Ek yaralanmaların sebep olduğu instabilite sonucu gelişebilecek posttravmatik osteoartriti azaltmak için tüm ek yaralanmaları operatif tedavi ettik. Sayılar ve klinik sonuçlar bu yazımızda sunulmuştur.

**Anahtar kelimeler:** Ön çapraz bağ yırtıkları, ilave yaralanmalar, cerrahi tedavi, serbest patellar tendon grefti

The purpose of treating knee injuries is to maintain menisci protection, rotational stability and to avoid premature posttraumatic osteoarthritis. The isolated ruptured of the ACL in most cases leads only to a moderate instability, additional injuries are frequently increasing the instability. Therefore we attach great importance to the exact diagnosis.

In particular the reconstruction of the posterior medial corner as a breakstop is of utmost importance. In our retrospective study we reviewed 104 acute ACL ruptures and during routinely performed arthroscopic examination we discovered additional lesions in 74 %. In order to minimize the posttravmatik osteoarthritis which is due to the instability caused by additional injuries we treated almost all the committant injuries operatively. The figures and the clinical outcome are presented in this paper.

**Key words:** ACL ruptures, additional injuries, operative treatment, free patellar tendon graft

The indication for reconstruction of ACL arisis through the degree of instability and on the other hand through the personal needs of the patient. Isolated ruptures of the ACL normally show only a slight degree of instability. The exploration is burdened by the reflectory muscle defense. In addition the exact clinical diagnosis of the additional injuries of the articular space is extremely difficult. Even the examination under general anaesthesia only supply information of ligamentous instabilites, they however do not dedect meniscal injuries.

The diagnosis of additional injuries are of substantial importance because they increase the degree of instability, and determine the overall outcome.

### Material and method

During the years 1989 / 90 a 104 fresh ACL ruptures were treated at our university clinic. A comprehensive clinical evaluation as well as arthroscopy was performed. Primarily suspected isolated ACL showed in a high incidence additional injuries: Partial ruptures of the ACL in 3 patients, injuries of the dorsomedial corner in 9 patients, an additional lesions of the medi-

al meniscus in 32 patients and the consecutive impairment of the popliteal corner in 9 patients, an additional lesion of the medial meniscus in 32 patients and the consecutive impairment of the popliteal corner as well as lateral meniscus lesion in 6 patients (Table I). In our overall statistics 2, 9 % of the ACL injuries were partial tears, we treated them with a brace or they required no treatment at all.

Severity of so called isolated ACL- Ruptures	
1.) partial ruptures	3
2.) ACL + POL	9
3.) ACL + POL and / or med. men	32
4.) ACL + POL + med. men and lat. men or lat. corner	6

Table I: Severity of the so called isolated ACL ruptures

In a few number of patients the stumps of the ACL were arthroscopically resected in order to prohibit incarceration. There are normally several methods of surgical ACL reconstruction. Artificial materials were hardly ever in our clinic. Either the middle third of the patellar tendon or the free semitendinosus transplant were used. Ideal proximal as well as distal rupture forms were treated with a transosseal technique

(1) Registrar Trauma Surgen University Clinic of Surgery Graz, Austria

(2) Consultant Trauma Surgen University Clinic of Surgery Graz, Austria

of reinsertion (1). Intraligamentary lesions were treated with a primary graft of the ACL (8).

In a majority of the cases the patellar tendon graft was dominant. Usually interference screws were applied to fix the bone blocks in the femoral and tibial tunnel (6, 8). In extreme cases there is the possibility of resorting to homologous transplants. Meniscal tears were either refixed or in most of the cases partially resected. Restoration of the POL was also performed very often in our series. Under arthroscopic view we checked whether it was necessary to suture the medial corner or not. If the medial compartment presented with a suffusion or haematoma in the capsule we did an additional medial incision and reconstructed the ligamentous structures with two or three properly placed mattress or transosseous sutures. The same procedure was carried out in the lateral compartment. Commitant chondral lesions were either treated with a fibrin glue and or attached with resorbable pins. Substantial defects were arthroscopically fixed with screws the head of the screw lying in the plane of the chondral surface. With large defects a Pridie drilling was performed for reasons of resurfacing. Two years of follow up showed the following figures. In 71,4% an isolated rupture of the ACL was found the other major ligaments remaining intact. A rotational instability was discovered in 20,1%. Complex instabilities were found in 8,7% (Dia. I).

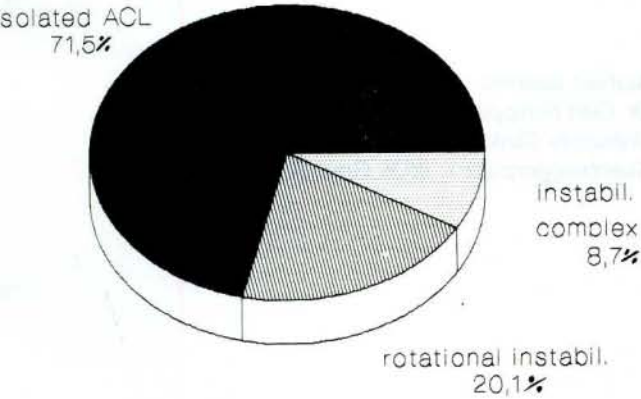


Diagram I: Fresh ACL ruptures

In addition 9,8% of the cases osteochondral fractures were discovered, primarily not seen in the X-ray. The so called isolated ACL showed additional injuries in 63,5% after an arthroscopy was performed, requiring additional surgery (Table II). Furthermore we listed the rupture forms of the ACL and found only in 32, 7% proximal, in 10, 6% distal ruptures with partial osseal detachment of the intercondylar eminence and in 54, 8% intraligamentary ruptures (Dia. II).

In 67% additional injuries were treated operatively. In 30 cases a partial meniscectomy was done and in 8 patients the meniscus was refixed (4, 7).

So called isolated ACL ruptures  
n = 74

36, 4 % patients with only ACL ruptures  
(including partial ruptures)  
63, 5 % patients with additional injuries

Table II: So called isolated ACL ruptures

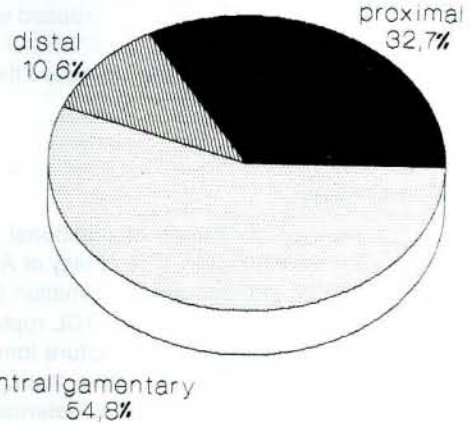


Diagram II: ACL ruptures

### Results

The accompanying hidden injuries in our study showed poor long term results if they were not treated properly because of the consecutive instability and the osteoarthritis.

Restoration of the POL was most often the key to a successful stable repair of ligament and capsular tears in the medial compartment (5).

Also patients who underwent partial meniscectomy showed in our series on a long term follow up a significant higher rate of knee swelling as well as more pain and lower reliability of the knee joint compared to the patients who underwent refixation procedures of the menisci (4, 7).

### Discussion

The role of the ACL as one of the main structures to stabilize the knee joint is undisputable. The question fixation, augmentation, artificial or autologous substitution is still controversial. In our series the free patellar tendon graft was dominant, because it guarantees a primary stable fixation together with a spectacular degree of ingrowth. In addition it offers a bone to bone healing which cannot be found with the semitendinosus graft. The cons of the patellar tendon are seen in a bony defect possibly resulting in consecutive wasting of the quadriceps muscle or in retropatellar problems. Artificial material present with a high risk of complications like chronic synovitis or defect healing. In extreme circumstances there is the possibility of resorting to homologous transplants. These however are only marginally available and present

the distinct possibility of infection (viral transmitted diseases). The capsular structures such as POL or ligaments of the lateral corner also play a major role for the stability and we think like other authors (10, 11) reconstruction of these subtle structures are most often the key for regaining knee stability. Also the important part of the menisci was described earlier by other authors, the Lysholm score decreased with partial meniscectomy (1). Commitant chondral lesions and their operative treatment also increase the likelihood of knee stability (3).

### Conclusion

Due to the high incidence of additional injuries every patient presenting with a possibility of ACL rupture undergoes an arthroscopic examination (9). The arthroscopic exploration of suspect ACL ruptures allows for precise judgement of the rupture form which is paramount for the further operative management. The indication for repair of the ACL is determined largely by the degree of the accompanying injuries. The reconstruction of the ACL is always adapted to the personal profile of the patient and is only performed with the personal compliance requiring a 6-12 month period of rehabilitation.

The accompanying hidden injuries for example the menisci or capsular ligaments were reasons for substantially impaired prognoses as compared with the results primarily expected.

### References

1. Boszotta, H. R., Wendlinsky, Sauer, G., Hhelpersdorfer, W.: Zwei jahresergebnisse nach arthroskopischer versorgung der vorderen kreuzbandruptur. Arthroskopie Band 4 Heft 2 1991

2. Gillquist, J., Hagberg, G. (1978) Findings in arthroscopy and arthrography in knee injuries. Acta Orthop. Scand. 949: 398.  
3. Glinz, W. (1979) Arthroskopische Diagnostik der traumatischen Knorpellasionen am Kniegelenk. Springer, Berlin Heidelberg, New York (Hefte zur Unfallheilkunde) Bd. 129, S 301.  
4. Hughston, J. C., Barrett, R. G. (1983) Acute anteromedial rotatory instability (long term results of surgical repair) J. Bone Joint Surg. (AM) 65 145-153.  
5. Hughston, J. C., Eilers, A. F.: The role of the posterior oblique ligament in repairs of acute medial (collateral) ligament tears in the knee. J. Bone Joint Surg. (AM) 55 A (1973) 923-940.  
6. Kurosaka, M., Yoshiya, S., Andrish, J. T.: A biomechanical comparison of different surgical techniques of graft fixation in anterior cruciate ligament reconstruction. Am J. Sports Med. 1987; 15 (3): 225-229.  
7. Noyes, FR., Mooar, PA., Mathews, DS., Butler, DL. (1983): The symptomatic anterior cruciate deficient knee. Part 1: The long term functional disability in athletically active individuals. J. Bone Joint Surg. (AM) 65 154-162.  
8. Noyes, FR., Butler, DL., Grood, ES., et al: Biomechanical analysis of human ligament grafts used in knee ligament repairs and reconstruction. J. Bone Surg. 1984: 66 A, 344-352.  
9. Paulos, R. E., Noyes, F. R., Malek, M.: A practical guide to the initial evaluation and treatment of knee ligament injuries. J. Trauma 20 (1980), 498.  
10. Sydnor, R. W., Andrews, J. R. (1985) Combined arthroscopy and mini-reconstruction techniques in the acutely torn anterior cruciate ligament. Orthop Clin. North Am 16: 171-179.  
11. Warren, RF., Levy, M. (1983) Meniscal lesion associated with anterior cruciate ligament injury. Clin. Orthop. 172: 32-36.

### Authors address

Dr. Gert Schippinger  
University Clinic of Surgery  
Auenbruggerplatz 1, 8036 Graz, Austria