

## Optimal correction in high tibial osteotomy

Hitashi Inaba<sup>(1)</sup>

### Yüksek tibial osteomide optimal korreksiyon

"High tibial osteotomi"nin sonuçları diz ekleminin post-operatif doğrultusuyla (alignment) yakın derecede ilişkilidir. Önceden düzeltilmesi planlanan açıdaki sapmalar düşünüldüğünde fibulaya uygulanan metodun belirleyici etkenlerden biri olduğu görülmüştür. Buna göre dizler iki gruba ayrılmışlardır. Birincisi tibio fibular eklemin serbesleştirilmesi ve fibula başı enükleasyonu ile birlikte yapılan kama osteostomisi, diğeryse fibula osteotomisiyle birlikte yapılan kama osteotomisidir. Fibulaya uygulanan metodlardaki farklılığın sapma sebeplerinden biri olduğu varsayılarak bu metodların düzeltme açısına etkileri değerlendirilmiş ve high tibial osteotomi'de düzeltim açısı analiz edilmiştir. Sağlanan düzeltim açısı fibula osteotom grubunda niyetlenilmiş düzeltim açısından daha büyüktü. Diğer gruptaysa daha küçük olduğu görülmüştür.

**Anahtar kelimeler:** Yüksek tibial osteotomi

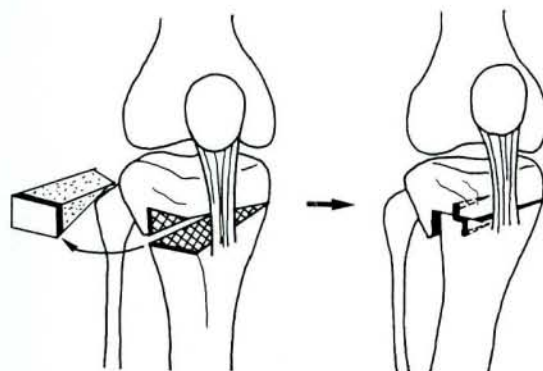
The results of high tibial osteotomy are closely related to post-operative alignment of the knee joint. When deviations from the predicted correcting angle in some cases are considered difference of fibula management is found to be one of the determinants. According to fibula management the knees were divided to two groups. One was wedge osteotomy with release of the tibio fibular joint and enucleation of the fibula head and the other was wedge osteotomy with the fibula osteotomy. Supposing that difference of fibula management are of the causes of the deviation, the influence of the fibula management on the correction angle was evaluated and the correction angle in high tibial osteotomy was analyzed. The achieved correcting angle was larger than the intended correcting angle in fibula osteotomy group and smaller in fibula lead group

**Key words:** High tibial osteotomy

It is well known that the results of high tibial osteotomy are closely related to postoperative alignment of the knee joint (3). However, there are deviations from the predicted correction angle in some cases. Supposing that difference of fibula management is one of the causes of the deviation, the influence of the fibula management on the correction angle was evaluated and the correction angle in high tibial osteotomy was analyzed.

### Materials and method

Seventy-one high tibial valgus osteotomies in sixty patients were performed between 1975 and 1990. The operation by interlocking wedge osteotomy with ventralization (1) was performed for painful medial tibio-femoral osteoarthritis with varus deformity, followed by routine fixation by long-leg cast for one month (Figur I). Our aim at the osteotomy was to achieve a slight valgus over-correction, namely the mechanical axis to pass through middle one-third of the lateral tibia plateau. Fiftyeight knees in forty-seven patients (female 33, male 14) could be followed for at least one year. The patients at operation were from 52 to 71 years of age (average 61 years 11



Figur I: Interlocking wedge osteotomy with ventralization

months). According to fibula management, the knees were divided to two groups. One was wedge osteotomy with release of the tibio-fibular joint and enucleation of the fibula head (fibula head group, 31 knees in 27 patients). The other was wedge osteotomy with the fibula osteotomy (fibula osteotomy group, 27 knees in 24 patients).

The preoperative varus deformity was measured on weightbearing radiographs of the whole limb. The

(1) Department of Orthopaedic Surgery, Akita University, School of Medicine Hondo, Akita, Japan

mechanical FTA (MFTA) was defined by lines drawn from the mid-point of the tibia plateau to the center of the femoral head and to the center of the talo-crural joint, and anatomical FTA (AFTA) was as usual. Therefore in the presence of the varus deformity, the angle is more than 180 degrees. The preoperative MFTA for fifty-eight knees while the patients bearing weight ranged from 185 to 203 degrees (average 193.2 degrees). To verify the correction that had been achieved, MFTA was measured one month after osteotomy without weight bearing and one year with weight bearing.

The reason why I evaluated the results of one year after osteotomy is founded by the report of Hernigou et al (4). They showed that alignment, namely the results of high tibial osteotomy, depends closely on the alignment of the knee joint one year after osteotomy.

**Results**

As shown in Table 1, it's mean achieved correcting angle in fibula head group was smaller than the mean intended one by 0.9 degree. One year after osteotomy, it changed much smaller by 1.4 degrees. In fibula osteotomy group, it's mean achieved correcting angle was larger than the mean intended one by 2.0 degrees, one year after operation, 3.3 degrees, namely 1.3 degrees gain for about one year.

S.D.)	Fibula head group	(mean± Fibula osteotomy group
AFTA (pre-ope)	183.8 ± 4.7	184.7 ± 4.9
MFTA (pre-ope)	192.5 ± 4.4	194.3 ± 4.8
Intended correcting angle	14.7 ± 3.2	17.0 ± 4.0
MFTA (one-month)	178.7 ± 3.8	175.3 ± 3.2
Deviation from I.C. angle (one month)	-0.9 ± 4.1	2.0 ± 3.2
Achieved correcting angle	13.8 ± 5.8	19.0 ± 5.1
MFTA (one year)	179.2 ± 5.0	174.0 ± 4.5
Deviation from I.C. angle (one year)	-1.4 ± 6.5	3.3 ± 4.8

Table 1: Cange of alignment pre and postoperatively

Figur II shows the results of regression analysis of the relationship between MFTA and deviation from intended correcting angle one year after osteotomy. In the knees of bellow 180 degrees of MFTA, deviation was less than 4 degrees. Critical MFTA corresponding to the deviation from intended correcting angle 0 degree in the fibula osteotomy group was lar-

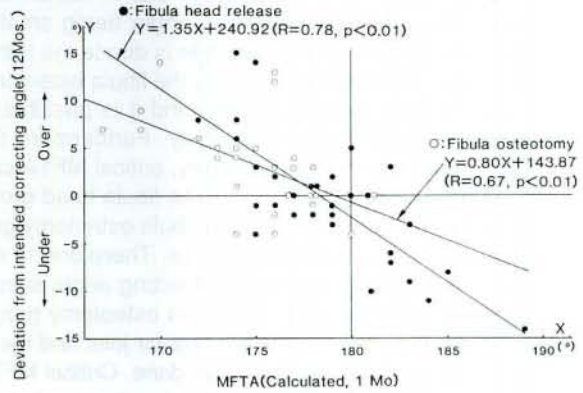


Figure II: The relationship between the deviation from the intended correcting angle one year and MFTA one month after operation

ger than that in the fibula head group both one month and one year after osteotomy. There was strong relationship between MFTA and change of correcting angle between one month to one year. However, there was no significant difference in linear regression equation between fibula head group and fibula osteotomy group. There was gain in correcting angle trend in the knees of below 180 degrees of MFTA. Critical MFTA corresponding to no change of correcting angle between one month and one year postoperatively was 178 degrees of MFTA. Critical MFTA corresponding to no change of correcting angle between one month and one year postoperatively was 178 degrees in both groups. Also the knees which had MFTA below 172 degrees never lost correcting angle during follow up, one year.

**Discussion**

There are many causes to occur deviation from intended correcting angle in high tibial osteotomy.

1. Wrong desigy of correcting angle.
2. Poor osteotomy technique.
3. Insufficient release of the proximal tibio-fibular joint and the fibula head enucleation.
4. Sinking of the distal tibia to the proximal tibia in osteoporotic cases.
5. Mis-estimation of the tilting angle of the joint space after osteotomy.

Wrong desing and poor technique are out of question. The results of present investigation are coincident with those by Jackson et al (5). They have reported that in fibula head group, insufficient correction caused in high incidence. Insufficient release of the tibio-fibular joint and fibula head enucleation probably causes tethering effect of the fibula on the proximal tibia, leading to disturbance of union and recurrence

of varus deformity. It is supposed that in fibula head group, the achieved correcting angle being smaller than the intended correcting angle is due to the tethering effect. On the other hand, in the fibula osteotomy group there is no such anxiety and it is possible to control alignment after osteotomy. Furthermore the fact that one year after osteotomy, critical MFTA corresponding to deviation zero in the fibula head group was smaller than the one in the fibula osteotomy group supports that mentioned above. Therefore, in the fibula head group, desing of correcting angle should be larger than the one in the fibula osteotomy group, and sufficient release of the tibio-fibular joint and the fibula head enucleation should be done. Critical MFTA corresponding to no change of correcting angle between one month and one year postoperatively was 178 degrees, and also the knees which had MFTA below 172 degrees never lost correcting angle during follow up, one year. While Tjornstrand (8) has shown osteoarthrotic changes on the lateral compartment in over-corrected valgus knee, these facts show that in considering the studies of Hernigou et al (4), Coventry (2) and Kettelkamp et al (6), to control the knee on the valgus alignment at least one year is important to keep good result for long period. In osteoporotic cases, while Mynert et al (7) attributed sinking to too early weight bearing, sinking of the distal tibia into the proximal one at the osteotomy region is occasionally a cause of unexpected deviation from intended correcting angle. However it is not difficult to recorrect the alignment at an early stage of sinking.

### Conclusion

In fibula osteotomy group, the achieved correcting angle was larger than the intended correcting angle

and in fibula head group, the achieved correcting angle was smaller than the intended correcting angle. In a case of the fibula head group, sufficient release of the tibio-fibular joint and the fibula head enucleation should be done. To keep good results of high tibial osteotomy, it is important to control the knee joint on the valgus alignment at least one year after osteotomy.

### References

1. Coventry, M. B.: Osteotomy about the knee for degenerative and rheumatoid arthritis. *J. Bone Joint Surg.*, 55-A : 23-48, 1973.
2. Coventry, M. B.: Current concepts review; upper tibial osteotomy for osteoarthritis. *J. Bone Joint Surg.*, 67-A: 1136-1140, 1985.
3. Harris, W. R. and Kostuik, J. P.: High tibial osteotomy for osteoarthritis of the knee. *J. Bone Joint Surg.*, 52-A : 330-336, 1970.
4. Hernigou, P. H., Medevielle, D., Debeyre, J. and Goutallier, D.: Proximal tibial osteotomy for osteoarthritis with varus deformity. 69-A: 332-354, 1987.
5. Jackson, J. P. and Waugh, W.: The technique and complication of upper tibial osteotomy. *J. Bone Joint Surg.*, 56-B, 236-245, 1974.
6. Kettelkamp, D. B. and Wenger, D. R.: Results of proximal tibial osteotomy. The effects of tibiofemoral angle, stance-phase flexion-extension, and medial plateau force. *J. Bone Joint Surg.*, 58-A : 952-960, 1976.
7. Mynert, R.: Failure of the correction of varus deformity obtained by high tibial osteotomy. *Acta Orthop. Scand.* 51: 569-573, 1980.
8. Tjornstrand, B. A. and Egund, N.: High tibial osteotomy; A seven year clinical and radiographic follow-up. *Clin. Orthop.* 160: 124-136, 1981.

Hitoshi Inaba, M. D.

Department of Orthopaedic Surgery  
Akita University School of Medicine  
1-1-1, Hondo, Akita, Japan