



Single-stage flexor tendoplasty in the treatment of flexor tendon injuries

Fleksör tendon yaralanmalarında tek seanslı fleksör tendoplasti

Atakan AYDIN, ¹ Murat TOPALAN, ¹ Ali MEZDEĞİ, ¹ İlker SEZER, ²
Türker ÖZKAN, ¹ Metin ERER, ¹ Safiye ÖZKAN ^{1,3}

¹Istanbul University Istanbul Medical Faculty Department of Plastic and Reconstructive Surgery, Hand Surgery Division; ²Private Practice; ^{1,3}Physiotherapist

Amaç: Primer onarımın mümkün olmadığı gecikmiş olgularda veya yara ve hastanın genel durumu açısından primer onarımın uygun olmadığı fleksör tendon yaralanmalarında uyguladığımız tendon greftiyle onarım değerlendirildi.

Çalışma planı: Otuz yedi hastada (29 erkek, 8 kadın; ort. yaş 20.5; dağılım 4-52) serbest tendon greftiyle tek seanslı fleksör tendoplasti (n=41) uygulandı. Yirmi sekiz hastada yaralanma zone II'deydi. Yaralanma ile cerrahi arasında geçen süre ortalama bir ay (dağılım 3-6 hafta) idi. Onarımların 26'sında palmaris longus; 14'ünde yüzeysel fleksör tendon, birinde fleksör karpi radialis tendon grefti kullanıldı. Ameliyattan sonra erken pasif hareket programı uygulandı. Kazanılan fleksiyon hareketi Strickland formülü kullanılarak hesaplandı. Sonuçlar, kullanılan tendon greftinin cinsi, sinir onarımı yapıp yapılmaması ve yaş grupları (10 yaş ve altı / 10 yaş üzeri) açısından karşılaştırıldı (ANOVA). Ortalama izlem süresi 35 ay (dağılım 4-83 ay) idi.

Sonuçlar: Fonksiyonel olarak, 12 parmakta mükemmel (%29.3), 13 parmakta iyi (%31.7), 14 parmakta orta (%34.2), iki parmakta kötü (%4.9) sonuç alındı. Tüm olgularda aktif hareket ortalaması %57 (dağılım %22-88) bulundu. Kullanılan tendon grefti cinsinin, tendon yaralanması ile birlikte sinir yaralanması olmasının veya yaşın sonuçları anlamlı derecede etkilemediği görüldü (p>0.05).

Çıkanmlar: Lokal yara şartlarının primer onarıma izin vermediği olgularda, tendonların primer onarıma müsaade etmeyecek kadar kısaldığı durumlarda, pulley sistemi yeterli ise, tek seanslı tendon greftiyle onarımın iyi bir seçenek olduğu sonucuna varıldı.

Anahtar sözcükler: Parmak eklemi/cerrahi; dikiş teknikleri; tendon yaralanmaları/cerrahi/rehabilitasyon; tendon/transplantasyon; tendon, para-artiküler/cerrahi/transplantasyon; tendon transferi; zaman faktörü.

Objectives: We evaluated tendon reconstruction with one-stage tendon grafting in flexor tendon injuries in which primary repair was not considered because of delay in treatment or of inappropriate circumstances on the part of the wound and the patient.

Methods: Thirty-seven patients (29 males, 8 females; mean age 20.5 years; range 4 to 52 years) underwent single-stage flexor tendoplasty involving 41 fingers. Twenty-eight patients had zone II injuries. The mean duration from trauma to surgery was one month (range 3 to 6 weeks). Tendon grafts were obtained from the palmaris longus in 26 repairs, flexor digitorum superficialis in 14 repairs, and flexor carpi radialis in one repair. Early passive rehabilitation was administered after surgery. Improvement in the flexion motion was calculated using the Strickland formula. The results were compared with respect to the tendon graft used, associated nerve injuries, and the age of the patients (equal to or below 10 years/above 10 years). The mean follow-up was 35 months (range 4 to 83 months).

Results: Functional results were excellent in 12 fingers (29.3%), good in 13 fingers (31.7%), moderate in 14 fingers (34.2%), and poor in two fingers (4.9%). Overall, the mean total active movement was 57% (range 22 to 88%). No significant differences were found between the functional results with respect to the tendon graft used, associated nerve injuries, and the age of the patients (ANOVA, p>0.05).

Conclusion: Single-stage flexor tendoplasty seems to be an appropriate choice of treatment for flexor tendon injuries where local wound conditions and decreased tendon length prevent primary repair, provided that the pulley system remains intact.

Key words: Finger joint/surgery; suture techniques; tendon injuries/surgery/rehabilitation; tendons/transplantation; tendons, para-articular/surgery/transplantation; tendon transfer; time factors.

Corresponding Author: Dr. Atakan Aydın, Istanbul University Istanbul Medical Faculty Department of Plastic and Reconstructive Surgery, 34093 Sehremeni, Istanbul. Phone: + 90-212-635 11 84 Fax:+ 90-212-534 68 71 e-mail: atakanaydin@yahoo.com

Application Date: 21.04.2003 **Acceptance Date:** 12.01.2004

Current treatment of flexor tendon injuries including zone II flexor injuries is primary repair. Due to the developments in tendon repair techniques, usage of better suture materials and increase in number of the physicians; zone II flexor tendon region is no longer “No man’s land!” any more as Bunnel has defined (1). Early primary tendon repair has now become a routine procedure in this region’s injuries when available. But in delayed cases where primary repair is impossible or if the wound condition or the patient general health is not available for primary tenoraphy, single stage repair of the flexor tendon with tendon graft is a good surgical option.

Patients and methods

In this study, a total of 37 patients (29 male,8 female) aged between 4-52 years whom were operated as single stage flexor tendoplasty with 41 free tendon grafts, between years 1996-2002 are presented. In 28 patients out of 37 the injury was in Zone II. The cause of the injury was sharp materials like glass, knife etc.in 24 cases, work accidents in 9 cases, rheumatoid arthritis in one case, gun shot wound in 2 cases and traffic accident in one case. In 20 finger injuries, digital nerve injury was also present along with tendon injury. Average time between the injury and the repair was nearly 1 month (3-6 weeks). The cases were assessed by the Boyes’ pre-operative tendon injury classification (Table 1)(2). Pneumatic tourniquet and standard Brunner’s zig-

zag incisions (3) were used to dissect tendons. Flexor tendon sheath were minimally resected and preserved if not already injured. Deep flexor tendon, nearly one cm length, was protected distally, the rest of the flexor tendon was excised until the origin of the lumbrical muscles. Superficial or deep flexor tendons were used as a motor power. If deep flexor tendons were used as motor tendon, superficial flexor tendons are pulled distally and cut. Distal superficial flexor tendon was cut out, but 1-2 cm of tendon was preserved to avoid hyperextantion deformity in PIP joint. Tendon grafts were palmaris longus in 26 cases, superficial flexor tendons in 14 cases, flexor carpi radialis tendon in one case. Although there are studies favoring preservation of paratenons, we excised the paratenon of the tendon graft carefully to avoid the stiffness. The tendon grafts are transferred through the flexor tendon sheath with help of sutures, nelaton catheters, silicon tendon prothesis atraumatically (Figure1) (4). Generally, distal tendon repair was performed first. Proximal tenoraphy was performed with deep flexor tendon at the level of the origin of lumbrical muscle (Zone III).

Entire tendon grafts were interposed between zone I and III; distal insertions were performed by such techniques: distal phalanx perforation (Bunnel), transposing the graft through pulp (Pulvertaft), end to end tenoraphy to the distal end of the flexor tendon (tendon-tendon); and proximal insertions were performed by: Kessler and Pulvertaft methods (Figure 2) (2,4,5). Insertions were performed by Bunnel type distally and Pulvertaft type proximally in 11 cases, tendon-tendon type distally and Pulvertaft type proximally in 9 cases, Bunnel type distally and Kessler type proximally in 2 cases, Pulvertaft type distally and Kessler type proximally in 8 cases, Pulvertaft type both distally and proximally in 7 cases, tendon-tendon distally and Kessler type proximally in 3 cases, Mytec rigid fixation at distal and Pulvertaft at proximal in 1 case.

Tension (length) of the tendon graft is important. Bunnel believed that the graft is shortened by time and he used to insert the tendon graft under minimal tension, on the contrary Pulvertaft believed that the tendon graft is elongated by time and insert-

Table 1: Boyes Classification before operation in flexor tendon injury(2)

Grade	Manner	
1	Good	Moderate scar with mobile joint, no trophic change
2	Scar	Severe skin scar due to injury or previous surgical procedure
3	Joint injury	Joint injury with limited motion
4	Nerve damage	Digital nerve injury causing trophic change at finger
5	Multiple	Severe scar in more than one finger

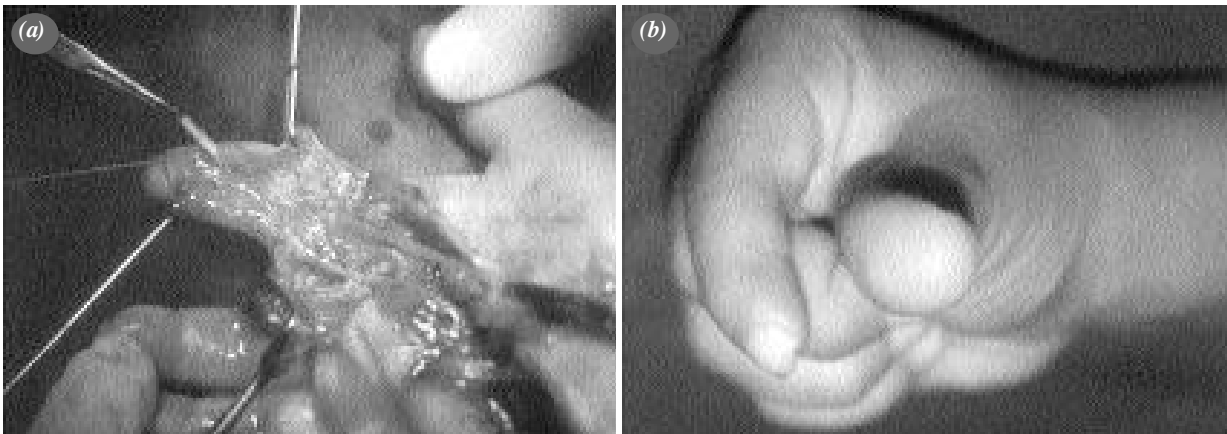


Figure 1. (a) Passing the tendon graft through the intact flexor tendon pulley. (b) Flexion motion of the same patient after flexor tendoplasty.

ed the graft under maximal tension (1,2,6). Some authors adjust the tension by peroperative electrical stimulations of the motor muscle (7). Under general or axillar anesthesia and the wrist at neutral position, each finger stands at a little bit flexed position comparing the finger at its radial. The wrist is flexed and extended and finger movements are observed and tension of tendon grafts are adjusted.

Rehabilitation program was began postoperative first day if neuroraphy was not done. If neuroraphy was performed with the tendoplasty, rehabilitation was started after 10 days of immobilization. Early passive movement program was used. 10 set of passive flexion and extension exercises were per-

formed for DIP and PIP joints while the hand is maintained in the splint. The splint holds the wrist joint at 30° flexion, metacarpophalangeal joint at 70° flexion and DIP/PIP joint at 0° extension. Active movement was started at 4th week. Splint was used until 6th week. Isolated active joint movement started at 6th week. At 8th week, the hand was allowed for daily activities. Flexion movement was evaluated by Strickland formulation (Table 2) (8).

Repair of flexor pollicis longus tendon injuries were evaluated by Buck-Gramcko method (9).

Results were assessed by comparing the tendon graft choice (FDS/PL), whether neuroraphy was performed or not and according to age groups (10 years and younger versus older patients) . ANOVA test was used for statistical analysis and $p < 0.05$ value was assumed as significant. Average follow-up time was 35 months (4-83 m).

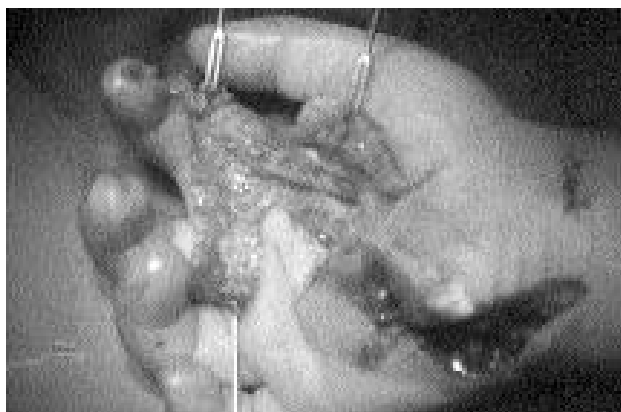


Figure 2. Repair by passing the tendon graft through the sheath and by fixing the proximal and to the flexor tendon and the distal end to the distal phalanx by Pulvertaft method.

Table 2: Strickland Formula and Classification in flexor tendon repair (8)

Range of Result (%)	Functional Healing
75-100	Very good
50-74	Good
25-49	Moderate
0-24	Worse

Strickland formulation:

Total Active Movement / Total Passive Movement x 100

Total Active Movement: (PIP+DIP)-limitation of extension

Total Passive Movement: (PIP+DIP)-limitation of extension

Results

In 12 fingers perfect results (Strickland %75-100), 13 fingers good results (Strickland %50-74), in 14 fingers average results (Strickland % 25-49), in 2 fingers bad results (Strickland % 0-24) were achieved. Mean active movement was % 57 (%22-88) (Figure 3). Mean active movement in cases; which FDS tendon was used as a tendon graft (n=15 finger) was %51.6 +/- 15.3 and which PL was used (n=25 finger) was %57.7 +/- 20 and there was no significant difference between two groups.

Mean active movement of 20 fingers which digital nerve injury was present with tendon injuries was %54.1 +/- 19.2; while of 21 fingers with only tendon injury was %60.9 +/- 19.1 and there was no significant difference between two groups.

Mean active movement of the patients who were 10 years old and younger (n=11 fingers) was %59.4 +/- 16.6 ; of the patients who were older (n=30 fingers) was %56.7 +/- 20.3 and there was no significant difference between two groups.

Infection at the incision site has been occurred in 3 cases and regressed with antibiotherapy. Shortness of tendon in one case was corrected with rehabilitation. Tenolysis was performed in 2 cases which tendon adhesion occurred and pulley reconstruction was performed in one case which pulley insufficiency was observed.

Discussion

According to the developments in tendon repair techniques, utilisation of better suture materials and the increase in number of the physicians dealing with hand surgery, primary repair became preferred treatment for zone II flexor tendon injuries. However in some cases free tendon grafts should be performed. This method is favored when the primary repair was delayed or end to end tenoraphy could not be performed. We need to delay the treatment, when general situation of the patient or local conditions of the wound is not suitable for primary repair. In secondary repair of zone II flexor tendon injuries, tendon graft application has the advantage of settling the tendon repair out of the flexor pulley system which is located between the base of distal phalanx distally and in palm proximally. By-passing the “no

man’s land” zone aims to resolve the problems in this zone’s injuries (1,2,4,6,8,10).

Flexor tendoplasties with free tendon grafts are usually performed in cases which two flexor tendons (deep and superficial) are injured at zone II . Wound must be in good condition and passive joint motions must be supplied (Boyes Grade 1,2) (2). When joint injuries are present that limit the motions, digital nerve injuries coexist that may cause trophic finger changes and multiple soft tissue

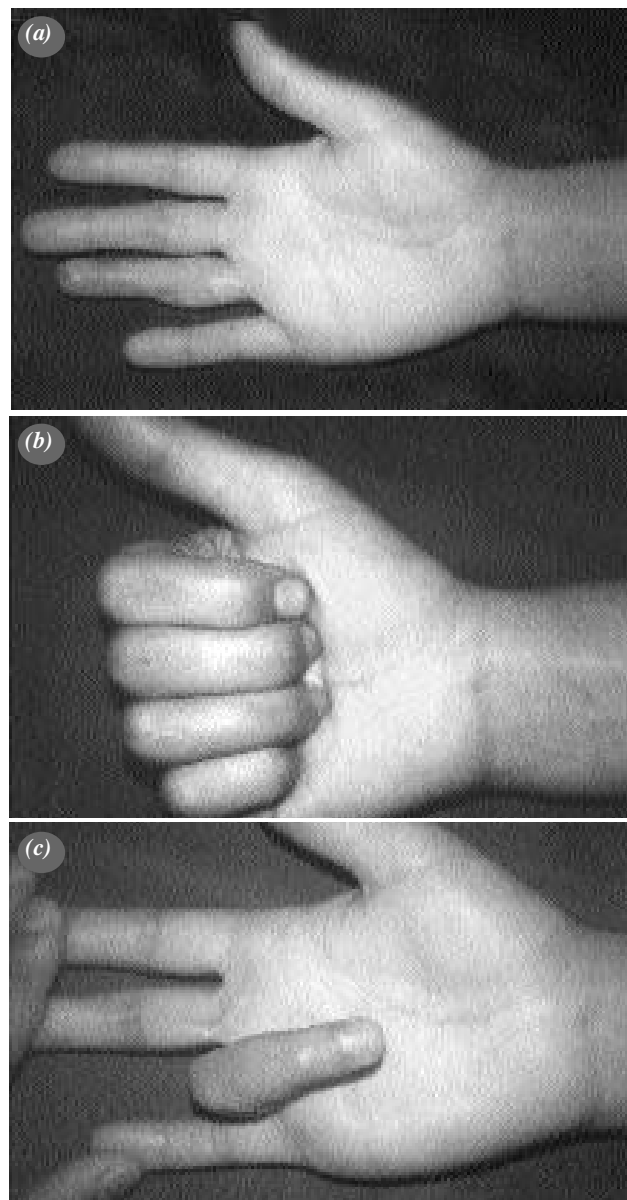


Figure 3. (a) Bruner incision scar in the right ring finger after flexor tendoplasty (b, c) Flexion motion of the same patient’s finger after surgery.

injuries are observed, two stage flexor tendon repair with tendon prosthesis must be preferred instead of single stage repairs (Table 1).

Wound healing and preparation of hand for operation takes 3-4 weeks. During this period, wound healing and skin softening take place along with beginning of the passive joint motions again. In our cases average time of this period between injury and operation was 1 month (3-6 weeks).

In our cases are palmaris longus was used as free tendon graft for 26 fingers. In 15 cases which palmaris longus was absent as an anatomic variation or multiple finger repairs were needed, flexor digitorum superficialis tendon of repaired finger was used. Tendoplasty with FDS tendon sounds to be worse because of the thickness of the tendon comparing PL tendon; but there was no significant difference between the results of this two repairs. As a result, utilisation of flexor digitorum superficialis tendon which can easily be dissected at the operation area does not effect negatively to the results. Utilisation of tendons from the different areas as plantar or foot finger extensor tendons does not make sence. We think that resection of paratenon of the tendon graft may decrease the adhesions (4,6,9).

Generally in tendon injuries, if the type of injury is "crash", causing bone fractures, joint, vessel and nerve injuries, skin defects or infections , the results of repair is worse than the clean cut injuries with minimal tissue damage. In 20 cases (%48) digital nerve injury accompanying to tendon injuries, neurography is also performed with flexor tendoplasty. Rehabilitation is started after 10 days of immobilization period to protect the neurography. In our study there was no significant difference between this group and the group without nerve injury. Some articles notify that digital nerve injuries has no effect to tendoplasty results but some of them notify that nerve injury effects the results negatively (6,10,11). In our study we observed that digital nerve injuries has no negative effect on functional results.

Relationship between patient's age and repair result is controversial, in some studies no correlation was found (9), however in an other study tendon rupture was more commonly seen at age between 0-5 (11). In our patients whose ages are 10 or younger

results seem to be better (%59.4 & % 56.7) but this difference was not significant and we decided that age does not effect the functional result.

There are two popular rehabilitation method after tendon repairs : early controlled active rehabilitation Kleinert's method and Duran's method that allow passive motion in the splint. There are also many different modifications (9-12). We preferred the early passive motion method in our cases. There was no tendon rupture as a complication. In 25 cases excellent and good (% 61 of all cases) results were obtained. Bunnell (6) presented the results of 138 flexor tendon repairs at 118 patients , quarter of the patients had the excellent results as the pulp of the patient could touch distal palmar crease, half of the patients had good results as they could barely touch the palmar surface, Chow et al. (10) presented the results of 78 flexor tendon repairs at 66 patients: % 94 of all cases had excellent or good results by the formulation of Strickland. In our study the excellent and good results were (% 61) less than we expected. We thought that the insufficient adaptation of the patients to rehabilitation programme and their reluctance for tenolysis operation when adhesions occurred, caused this situation.

As a conclusion when the local woud conditions is not suitable for primary tenoraphy and tendons are to short to be repaired primarily, if the flexor pulley system is sufficient, we think that single stage tendoplasty with tendon graft is a good option. Tendon prosthesis can be only used in cases which is reoperated or sheat and pulley system is badly injured.

References

1. Hagberg L. Flexor tendon repairs in zone II. In: Blair WF, editor. Techniques in hand surgery. 1st ed. Maryland: Williams & Wilkins; 1996. p. 137-46.
2. Schneider LH, Hunter JM. Flexor tendons-late reconstruction. In: Green DP, editor. Operative hand surgery. Vol. 3, 2nd ed. New York: Churchill Livingstone; 1988. p. 1669-2044.
3. Bruner JM. The zig-zag volar-digital incision for flexor-tendon surgery. *Plast Reconstr Surg* 1967;40:571-4.
4. Schneider LH. Flexor tendons-late reconstruction. In: Green DP, editor. Operative hand surgery. Vol. 2, 4th ed. New York: Churchill Livingstone; 1998. p. 1898-949.
5. Kessler I. The "grasping" technique for tendon repair. *Hand* 1973;5:253-5.
6. Boyes JH. Free tendon grafts. In: Bunnell's surgery of the hand. 4th ed. London: J. B. Lippincott; 1964. p. 432-41.
7. Williams SB. New dynamic concepts in the grafting of flexor tendons. *Plast Reconstr Surg* 1965;36:377-419.

8. Strickland JW. Results of flexor tendon surgery in zone II. *Hand Clin* 1985;1:167-79.
9. Schneider LH. Flexor tendon injuries. In: Manske PR, editor. *Hand surgery update*. 2nd ed. Rosemont: American Academy of Orthopaedic Surgeons; 1996. p. 141-7.
10. Chow JA, Thomes LJ, Dovel S, Monsivais J, Milnor WH, Jackson JP. Controlled motion rehabilitation after flexor tendon repair and grafting. A multi-centre study. *J Bone Joint Surg [Br]* 1988;70:591-5.
11. Kayali C, Eren A, Agus H, Arslantas M, Ozcalabi IT. The results of primary repair and early passive rehabilitation in zone II flexor tendon injuries in children. [Article in Turkish] *Acta Orthop Traumatol Turc* 2003;37:249-53.
12. Aydin H, Keskin N, Kuran İ, Kuran B, Bulus H. Active range of motion evaluation after flexor tendon repairments. *Acta Orthop Traumatol Turc* 1992;26:270-5.