



The treatment of comminuted midfoot fractures with distraction osteogenesis (report of 4 cases)

Orta ayak bölgesi çok parçalı kırıklarının distraksiyon osteogenezi ile tedavisi

Bahtiyar DEMİRALP, Mustafa KÜRKLÜ, Doğan BEK, Yüksel YURTTAŞ, A. Sabri ATEŞALP

Gülhane Military Medical Academy Orthopaedic and Traumatology Department

Amaç: Orta ayak kırıklarında Ilizarov sirküler eksternal fiksator cihazı ile gerçekleştirilen distraksiyon osteogenezi ile tedavi sonuçları değerlendirildi.

Çalışma planı: Dört hastada yüksek enerjili travmaya bağlı meydana gelen orta ayak çok parçalı kırığı sirküler eksternal fiksator cihazı ile distraksiyon osteogenezi uygulanarak tedavi edildi. Üçü erkek, biri kadın olan hastaların yaş ortalaması 24 (dağılım 19-37) idi. Yaralanma nedenleri bir olguda trafik kazası, üç olguda mayın patlamasının neden olduğu araç içi yaralanma idi. Sirküler eksternal fiksator cihazı ile ortalama üç ay (dağılım 2.5-4 ay) süreyle kırık bölgesine ortalama 10.5 mm (dağılım 9-13 mm) distraksiyon uygulandı. Değerlendirmelerde topallama, ağrı varlığı, radyografik ölçümler ve AOFAS (the American Orthopaedic Foot and Ankle Society) skorları dikkate alındı. Ortalama izlem süresi 58 ay (dağılım 33-81 ay) idi.

Sonuçlar: Sirküler eksternal fiksator cihazının çıkarılması sonrası birinci ayda tüm hastalarda topallama vardı. Altıncı ayın sonunda dört hastanın birinde topallama ve ağrı tamamen geçti; ikisinde azalarak devam ederken, bir hastada sekel olarak kaldı. Cihazın çıkarılmasının ardından yürüme sırasında oluşan ağrı şikayeti üç hastada 3-6 ay içinde azalarak geçti; bir hastada sekel olarak kaldı. Radyografik takipler ayağın ön-arka ve yan stres grafilerine göre yapıldı. AOFAS orta ayak değerlendirme skoru ortalaması 70.5 (50-89) bulundu.

Çıkanmlar: Sirküler eksternal fiksator cihazı ile distraksiyon osteogenezi, yüksek enerjili travma ile oluşan, başka yöntemlerle anatomik reduksiyon sağlanamayacak durumdaki orta ayak kırıklarının tedavisinde alternatif bir tedavi yöntemi olabilir.

Anahtar sözcükler: Eksternal fiksator; ayak yaralanmaları; kırık, parçalı/etiyoloji; Ilizarov tekniği; osteogenez, distraksiyon; tarsal kemikler/yaralanma/radyografi; tarsal eklem/yaralanma.

Objectives: We evaluated the results of distraction osteogenesis with the Ilizarov circular external fixator in the treatment of comminuted fractures of the midfoot.

Methods: Four patients (1 female, 3 males) with comminuted midfoot fractures due to high energy trauma were treated with distraction osteogenesis performed by the Ilizarov circular external fixator. The mean age was 24 years (range 19 to 37 years). Fractures resulted from a traffic accident in one case, and from vehicle blast due to landmine explosion in three cases. The circular external fixator was applied for a mean of three months (range 2.5 to 4 months), during which the mean distraction was 10.5 mm (range 9 to 13 mm) at the fracture zone. The results were assessed according to the presence of pain and limping, radiographic measurements, and to the AOFAS (the American Orthopaedic Foot and Ankle Society) scoring system. The mean follow-up period was 58 months (range 33 to 81 months).

Results: All the patients had limping for a month following the removal of the fixator. At the end of six months, limping disappeared in one patient, decreased in two patients, and remained as a sequela in one patient. Pain which occurred during walking after the removal of the fixator decreased and finally disappeared within 3 to 6 months in three patients, but remained in one patient. Radiographic assessments were made using the antero-posterior and lateral X-rays of the foot. The mean AOFAS score was 70.5 (range 50 to 89).

Conclusion: Distraction osteogenesis performed with the use of the Ilizarov circular external fixator may be an alternative in the treatment of comminuted foot fractures due to high energy traumas, where no other modality is likely to provide an anatomical reduction.

Key words: External fixators; foot injuries; fractures, comminuted/etiology; Ilizarov technique; osteogenesis, distraction; tarsal bones/injuries/radiography; tarsal joints/injuries.

Anatomic reduction and stable internal fixation (ORIF) are among the basic principles of the surgical therapy of mid – foot dislocations with breaks (1,2,3). However, there are authors expressing that closed reduction and percutaneous fixation (CRPF) methods can also be used (1,4,5,6,7,8). Anatomic reduction must be provided with one of ORIF or CRPF methods, whatever the degree of the break displacement at the beginning is, and fixation must be continued until the recovery of the bone is completed (2).

In case of multi – part breaks of the mid – foot that occur as the result of high – energy traumas, it is difficult to perform anatomic reduction with ORIF. In such cases, distraction osteogenesis performed with circular external fixator (CEF) device is an alternative surgical therapy method in order to obtain a plantigrade foot with normal length, where the longitudinal arc is reformed.

In this study, the therapy results obtained with distraction osteogenesis for four cases having mid foot break that has so many parts that it cannot be cured with ORIF method have been assessed.

Patients and method

Distraction osteogenesis with CEF has been applied to four patients (average age 24, distribution 19 – 37) with high – energy mid – foot multipart breaks between December 1996 – December 2000. One of the cases was a woman the three were men. Wounding was on the right foot in two of the cases

and on the left foot of the other two cases. The reasons of wounding were crushing wound as the result of a traffic accident for one case, and in – vehicle wounding caused by mine explosion for other three cases. In two of the cases wounded as the result of mine explosion, proximal basis break was also existent in the 1st, 2nd and 4th metatarsus.

All of the patients have been brought to our hospital in the first 24 hours following the wounding. Circular external fixator devices have been prepared so as to have two full rings at 1/3 distal cruris region, 5/8 ring at calcaneus region and one half ring at the fore foot region. With the distraction rods placed between the calcaneus ring and fore foot ring, distraction of the break region and re – provision of the foot length has been targeted and with the hinges placed in the same region, reconstruction of the longitudinal arc of the foot has been planned. Two 1.8 mm K – wires with appropriate angles to each of the two full rings at cruris region, two 1.8 mm stop K – wire to the calcaneal ring and two 1.8 K wires to the fore foot ring with appropriate angles have been applied (Figure 1a, b).

After the operation, for a period of five days, cefasoline sodium 1 gram flacon has been applied daily and intravenously to the cases at a dose of 2x 1 g being prophylactic. On the first day following the operation, mid – foot distraction has been started with 0.25 x 4 mm / day rate and the patients has been made mobile without loading the side extremity. After the completion of the distraction that has been




Figure 1: (a) front and (b) side appearance of the device used for mid foot breaks

performed through comparison with the healthy foot radiographically, the reconstruction of the longitudinal arc has been provided with hinges (Figure 2,3).

After distraction and reconstruction, walking orthosis appropriate for the patients have been prepared on the 20th day as an average (19th – 21st

days). Giving 50% weight to the side extremity has been permitted using two crutches. One month after the operation, all patients are made to stand on their foot without using supports, with 100% weight.

The circular external fixator devices are taken off in 3.3 months in average (distribution 2.5 – 4

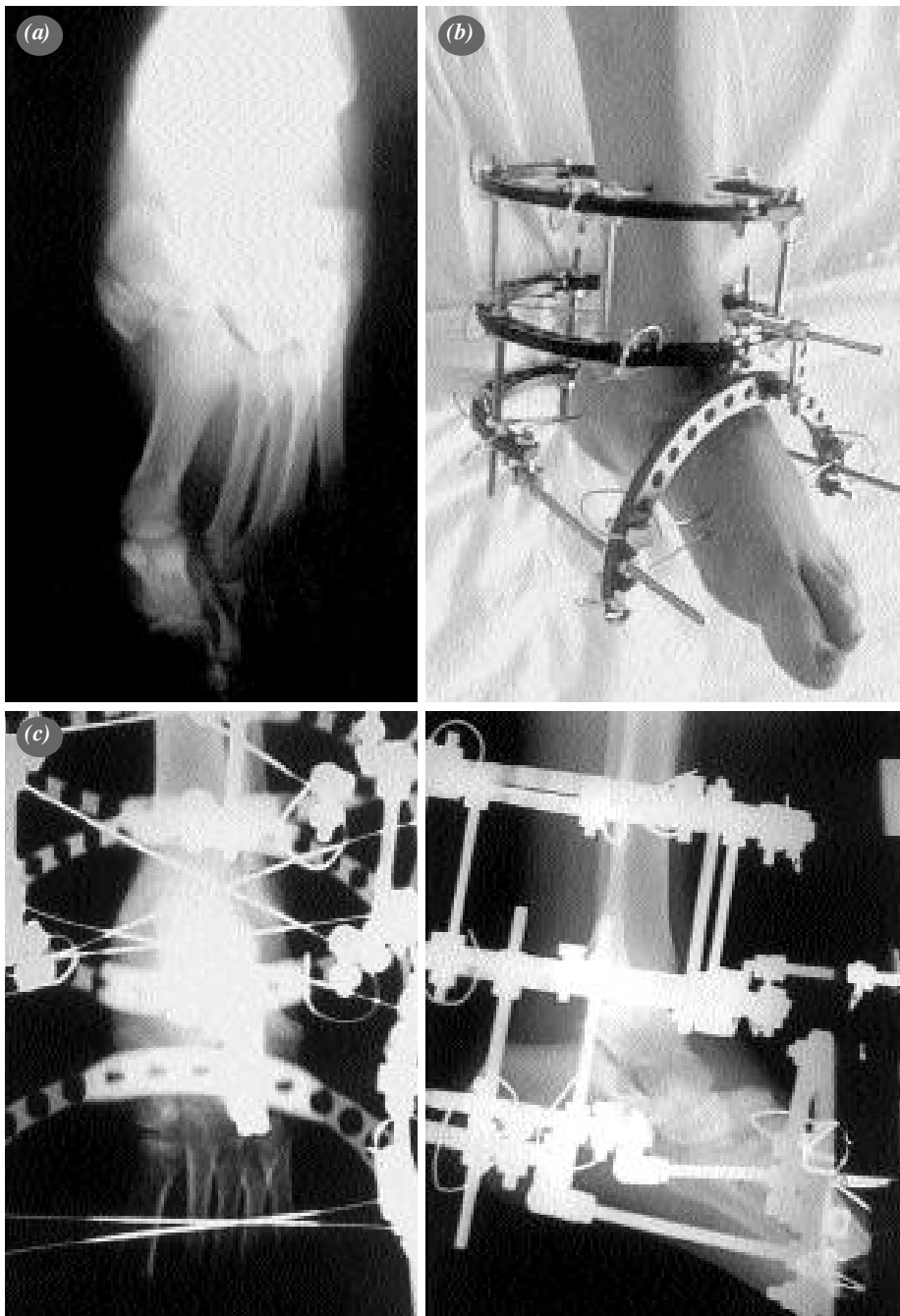


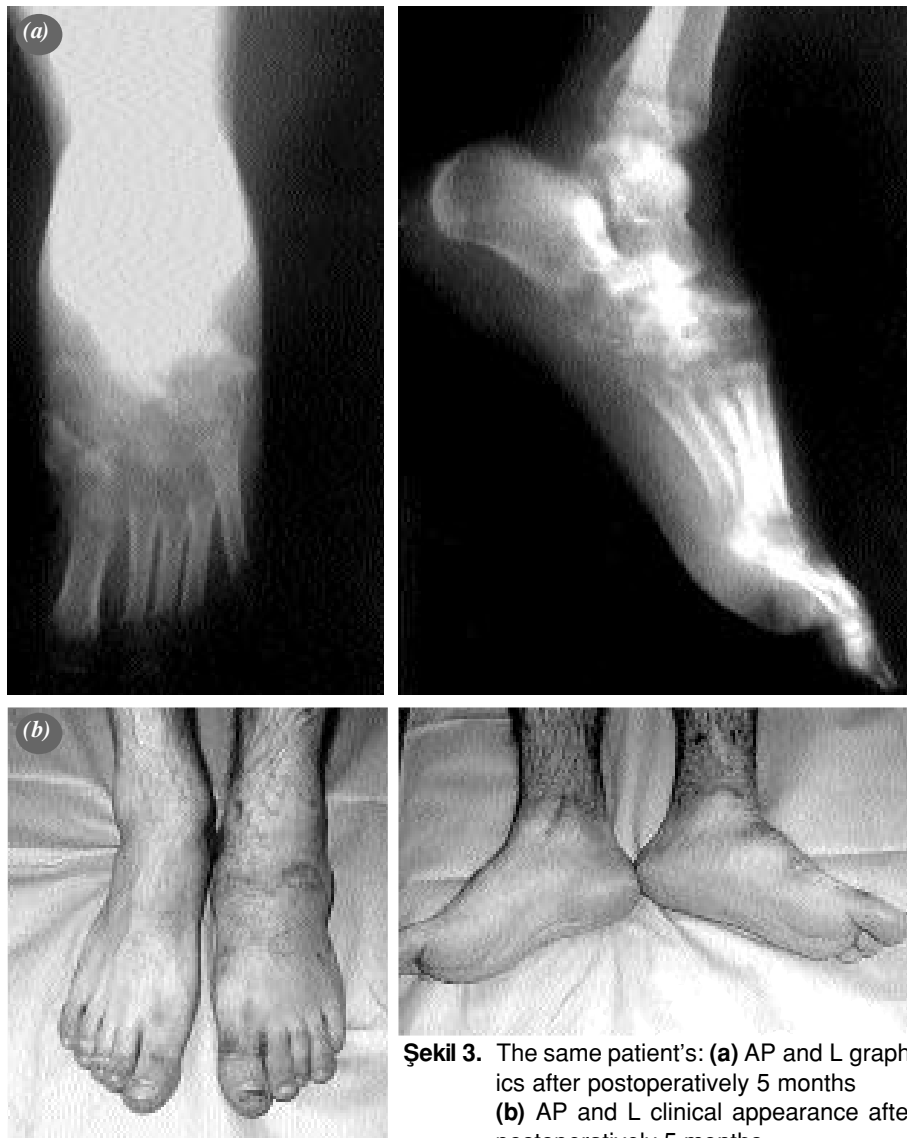Figure 2: (a) AP graphics of the patient, who has been subject to in – vehicle wounding with the explosion effect (b) appearance after the application of external fixator (c) AP and L graphics taken when the device was on.

months). The decision to take the device off has been given in accordance with the osseous adherence result that has been radiographically determined. After the device is taken off, pedogram has been applied to the patients and appropriate bases have been prepared to be put in their shoes. In terms of repetition and degenerative changes, radiographic controls have been carried out first, 6 months later and then once a year. The patients have been followed up for an average period of 58 months (distribution 33- 81 months).

Results:

The assessment has been carried out in accordance with limping, presence of ache, radiographic measurements and AOFAS (American Orthopaedic

Foot and Ankle Society) scoring system. In the first month after the circular external fixator device, all patients limped. At the end of the sixth month, limping has disappeared completely in one patient; it continued in a smaller amount in two of them but remained permanently in one patient. After the device is taken off, the ache occurring while walking disappeared getting smaller in 3-6 months; it remained permanently in one patient. For all patients, after the CEF devices are taken off, the decreased ankle movements recovered completely at the end of the first month. In the physical inspection, advanced decrease has been determined in comparison with the healthy foot in the rear foot and tarsometatarsal joint movements. When compared with the healthy foot, valgus increase has been seen in



Şekil 3. The same patient's: (a) AP and L graphics after postoperatively 5 months
(b) AP and L clinical appearance after postoperatively 5 months.

Table-1: AP graphics of the cases

Case	AP X Ray						Lateral X Ray		Valgus of the hind foot
	Talo- first metatarsal angle		Talocalcaneal angle		Talonavicular grasping angle		Talo- first metatarsal angle		
	Pre. Op	Post. Op	Pre. Op	Post. Op	Pre. Op	Post. Op	Pre. Op	Post. Op	
1	32	11	40	29	42	15	38	4	9
2	30	8	37	30	38	15	36	2	5
3	19	5	35	25	31	12	28	3	3
4	17	7	30	30	27	11	24	3	2

calcaneal order of one patient and deformation has been seen in the foot dorsum of one patient (humping).

The radiographic follow up has been performed in accordance with the AP and L stress graphics of the foot. Existence of degenerative arthritis, the quality of reduction after the therapy and whether the reconstruction of the foot longitudinal arcs is performed or not are examined.

In the AP direct graphics of the patients shot before and after the operation, the talus – first metatarsal angle has been measured as 24.50 (170-320) and 7.80 (50- 110); talocalcaneal angle has been measured as 35.50 (300- 400) and 28.50 (250-300); talonavicular grasping angle has been measured as 34.50 (270- 420) and 13.30 (110- 150). In the L graphics, talus – first metatarsi angle, which was 31.50 (240- 380) before the operation has been measured as 30 (20- 40) (Table 1).

The longitudinal arcs of all feet, which have settled due to the break, have been provided again through distraction osteogenesis and reconstruction method (9).

The rear foot physiologic valgus that increased before the operation has been corrected in three of the four feet by giving full load neutrally or so as to be less than 5 degrees after the operation. In one patient, the physiologic valgus has been found to be 90 by applying full load. Osseous bonding and fusion development have been observed in all patients between partial tarsal bones in the direct graphics within the period of taking off the circular external fixator device. Degenerative arthritis has developed on Lisfrank joint of two patients with breaks on 1st, 2nd and 4th metatarsus basis during observation. In one patient, degenerative changes

have been determined on the talonavicular joint. While the circular external fixator device was on, the nail way infection that developed in three cases has been completely recovered with dressing. At the end of the observation period, AOFAS mid foot assessment score average has been found to be 70.5 (distribution 50 – 89).

Discussion:

One of the functions of mid foot is to regulate forces while giving weight on the foot and to distribute these forces. In case of dislocations of the tarsal bones and tarsometatarsal joint's dislocations with breaks, anatomic repair is necessary. Even a slight deformation in this joint complex causes bad clinical and radiographic results (2,6,10,11,12). The studies performed have shown that the surgical method used in the therapy of mid – foot breaks (ORIF or CRPF), type of wounding (traffic accident or others), age (<35 or > 35) and gender did not have any important effect on AOFAS score and that reduction degree (anatomic, approximately anatomic or non – anatomic) was important (4,6,7,8,11,12,13,14). Teng, Pinzur et al has found the walking analysis measurements normal at the end of the therapy they applied by providing full anatomic reduction in case of tarsal – metatarsal joint dislocation with breaks. But, in spite of perfect radiographic results and normal dynamic walking types, they could not obtain a satisfactory result from the patients subjectively (in terms of ache)(2,6,10,15).

In our cases, there were multi – part and displaced breaks on the mid foot bones due to high – energy trauma. In these cases, where anatomic repair will not be possible through internal fixation, we targeted to provide reduction through distraction on the mid foot with the aid of CEF and to reform the longitudinal arc through correction. In this way, we planned to obtain

a foot having the same length with the healthy foot, which is plantigrade and close to the dynamics of the healthy foot. In one case, we encountered a continuous ache complaint. We thought this ache was related with the degenerative arthritis that occurred on Lisfranc joint and the deformed mid – foot dynamics.

Myerson et al has obtained a better result with open reduction in cases where tarsometatarsal displacement greater than 2 mm and over talus – first metatarsal angulation greater than 15 degrees are determined after closed reduction (2). In all cases that we cured by applying distraction osteogenesis with circular external fixator device, we carried the tarsometatarsal displacement and talus – first metatarsal angle to normal limits without need for ORIF method and we provided its continuity.

After the repair of mid – foot breaks, anatomic, approximately anatomic (2 mm displacement) and non – anatomic (displacement greater than 2mm) reductions are obtained in accordance with the tarsometatarsal joint displacement degree radiographically (2,4,11,13). Clinical studies have shown that in cases for which anatomic reduction is not performed, post – traumatic arthritis is seen at a higher rate in comparison with the cases for which anatomic and approximately anatomic reduction have been made (4,11).

Kuo et al has reported that more post – traumatic osteoarthritis developed in cases where ligamentosis and bone wounding are seen together in comparison with the cases with only ligamentosis wounding (4). Perugia et al has obtained a better AOFAS score in case of only dislocation of the mid foot in comparison with its dislocation with breaks (11). These studies show that the ratio of development of post – traumatic osteoarthritis increases as the severity of the trauma increases. In the light of these approaches, we accept post – traumatic osteoarthritis as an indispensable result in three of the four cases with mid foot multi – part break as the result of high – energy trauma, in spite of performance of approximately anatomic reduction.

As a result, for multi – part mid foot breaks that occur with high – energy trauma, for which the application of ORIF and anatomic reduction is not possible, distraction osteogenesis performed with CEF device can be an alternative therapy method.

References

1. Buzzard BM, Briggs PJ. Surgical management of acute tarsometatarsal fracture dislocation in the adult. *Clin Orthop* 1998;(353):125-33.
2. Myerson MS, Fisher RT, Burgess AR, Kenzora JE. Fracture dislocations of the tarsometatarsal joints: end results correlated with pathology and treatment. *Foot Ankle* 1986;6:225-42.
3. Wilson DW. Injuries of the tarso-metatarsal joints. Etiology, classification and results of treatment. *J Bone Joint Surg [Br]* 1972;54:677-86.
4. Kuo RS, Tejwani NC, Digiovanni CW, Holt SK, Benirschke SK, Hansen ST Jr, et al. Outcome after open reduction and internal fixation of Lisfranc joint injuries. *J Bone Joint Surg [Am]* 2000;82:1609-18.
5. Arntz CT, Veith RG, Hansen ST Jr. Fractures and fracture-dislocations of the tarsometatarsal joint. *J Bone Joint Surg [Am]* 1988;70:173-81.
6. Blanco RP, Merchan CR, Sevillano RC, Martinez LM. Tarsometatarsal fractures and dislocations. *J Orthop Trauma* 1988;2:188-94.
7. Goossens M, De Stoop N. Lisfranc's fracture-dislocations: etiology, radiology, and results of treatment. A review of 20 cases. *Clin Orthop* 1983;(176):154-62.
8. Hardcastle PH, Reschauer R, Kutscha-Lissberg E, Schoffmann W. Injuries to the tarsometatarsal joint. Incidence, classification and treatment. *J Bone Joint Surg [Br]* 1982;64:349-56.
9. Ilizarov GA. *Transosseous osteosynthesis: Treatment of disorders of the foot*. New York: Springer-Verlag; 1992.
10. Rosenberg GA, Patterson BM. Tarsometatarsal (Lisfranc's) fracture-dislocation. *Am J Orthop* 1995;Suppl:7-16.
11. Perugia D, Basile A, Battaglia A, Stopponi M, De Simeonibus AU. Fracture dislocations of Lisfranc's joint treated with closed reduction and percutaneous fixation. *Int Orthop* 2003;27:30-5.
12. Schenck RC Jr, Heckman JD. Fractures and dislocations of the forefoot: Operative and nonoperative treatment. *J Am Acad Orthop Surg* 1995;3:70-8.
13. Myerson M. The diagnosis and treatment of injuries to the Lisfranc joint complex. *Orthop Clin North Am* 1989;20:655-64.
14. Wilppula E. Tarsometatarsal fracture-dislocation. Late results in 26 patients. *Acta Orthop Scand* 1973;44:335-45.
15. Teng AL, Pinzur MS, Lomasney L, Mahoney L, Havey R. Functional outcome following anatomic restoration of tarsal-metatarsal fracture dislocation. *Foot Ankle Int* 2002;23:922-6.