



The use of local anesthesia in endoscopic release of the carpal tunnel

Endoskopik karpal tünel cerrahisinde lokal anestezi tekniği

Tolga TÜZÜNER,¹ Kutay Engin ÖZTURAN,¹ Mehmet SUBAŞI,² Erkut KARACA¹

¹Abant İzzet Baysal University Duzce Medical School, Department of Orthopaedics

²Dicle University Medical School, Department of Orthopaedics

Amaç: Lokal anestezi tekniğiyle yapılan endoskopik karpal tünel cerrahisinin erken dönem sonuçları değerlendirildi.

Çalışma planı: On hastanın (8 kadın, 2 erkek; ort. yaş 43; dağılım 35-58) 14 eline Wood ve Logan tarafından tanımlanan lokal anestezi uygulamasını takiben, Chow'un iki girişli tekniği ile endoskopik karpal tünel gevşetme ameliyatı uygulandı. Beş hastada sağ, üçünde sol, ikisinde iki taraflı tutulum vardı. Ameliyat öncesinde, elektromiyografi sonuçları tüm hastalarda karpal tünelde orta ve ağır düzeyde median sinir basısı ile uyumluydu ve Tinel ve Phalen testleri pozitif bulundu. Olgularda diabetes mellitus, gut, hipotiroidi gibi metabolik rahatsızlıklar ve gebelik yoktu ve bir aylık konservatif tedaviye yanıt alınmaması üzerine cerrahiye karar verildi. Ameliyat sonrasında hastalar ortalama 16 ay (dağılım 10-24 ay) süreyle izlendi.

Sonuçlar: İki bilekte (%14.3) kesi bölgesine lokal anestezi desteği ve sedasyon gerekti. Enjeksiyon sırasında parestezi şikayeti olmadı. Lokal anesteziye bağlı sinovyal tabaka kalınlığında artma görülmedi veya serbest sıvı artışına bağlı görüntüde bozulma meydana gelmedi. Olgularda tendon yaralanması, hematoma, sempatik distrofi ve sinir yaralanması görülmedi. Ameliyattan sonra bir olguda üçüncü ve dördüncü parmakta nöropaksi görüldü. Ameliyattan sonra erken dönemde iki bilekte ağrı görüldü. Bu süre birinde 10 gün, diğerinde iki ay idi. Tüm olgularda ameliyat öncesindeki şikayetlerin geçtiği gözlemlendi. İzlem süresi içinde hiçbir hastada nüks görülmedi.

Çıkarımlar: Karpal tünel cerrahisinde lokal anestezi tekniği, hızlı, güvenilir ve gününbirlik uygulamalara olanak sağlayan bir tekniktir.

Anahtar sözcükler: Anestezi, lokal; karpal tünel sendromu/cerrahi; endoskopi; enjeksiyon; median sinir/yaralanma/cerrahi.

Objectives: We evaluated the early results of endoscopic carpal tunnel release with the use of local anesthesia.

Methods: Endoscopic carpal tunnel release was performed in 14 hands of 10 patients (8 females, 2 males; mean age 43 years; range 35 to 58 years) using the two-portal Chow technique following local anesthesia described by Wood and Logan. Involvement was in the right hand in five patients, in the left in three, and in both hands in two patients. Electromyography showed moderate or severe compression of the median nerve in the carpal tunnel and the Tinel's and Phalen's signs were positive in all the patients. There was no previous history of metabolic diseases such as diabetes mellitus, gout, or hypothyroidism, nor a coexisting pregnancy. The decision for surgery was given at the end of an unsuccessful conservative treatment for a month. The mean follow-up period was 16 months (range 10 to 24 months).

Results: Two patients (14.3%) required further anesthesia with local anesthetic agents and sedation in the incision area. No complaints of paresthesia were seen during injections. Injection-associated problems such as increased thickness of the synovial layer or decreased endoscopic view did not occur. No instances of tendon or nerve injury, hematoma, or sympathetic dystrophy were seen. One patient developed neuropraxia in the third and fourth fingers postoperatively. Early postoperative pain was observed in two wrists, appearing 10 days and two months after surgery, respectively. During the follow-up period, all the patients were free of preoperative complaints and no recurrences were encountered.

Conclusion: Local anesthesia is a rapid and reliable technique in carpal tunnel surgery, enabling hospitalization confined to the same day.

Key words: Anesthesia, local; carpal tunnel syndrome/ surgery; endoscopy; injections; median nerve/injuries/surgery.

Endoscopic carpal tunnel release (ECTR) surgery is one of the commonest surgeries performed in hand surgery.⁽¹⁾ General or local anesthesia, methods of bier block (intravenous regional anesthesia), axillary or brachial plexus block can be used. The technique of local anesthesia is widely used in ECTR surgery like the other methods applied to hands.⁽²⁻⁴⁾ In the endoscopic carpal tunnel release injection of local anesthetic into the surgery area increases the volume and free fluid amount of synovial membrane.⁽²⁾ and this is not welcome in endoscopic surgery. Application of bier block or brachial plexus, other local anesthesia techniques require much more time. In outpatient cases the technique of local anesthesia which is a rapid and reliable technique and does not cause an increase in fluid during the operation and was reported by Wood and Logan⁽⁵⁾ has been used in endoscopic carpal tunnel surgery.⁽²⁾

In this study, surgical results of local anesthesia technique used in cases of ECTR are assessed.

Patients and method

Between June 2000 and July 2002, endo-CTR was applied to 14 hands of 10 patients (8 women, 2 men; average of ages 43; range between 35 and 58) because of carpal tunnel syndrome. Five of the patients had cricks in the right, three of them had in the left and two had bilateral cricks. The two patients having bilateral cricks in two of the wrists had their surgery in different sessions.

Before the operation the outcomes of electromyography complied with the median nerve compressed in the carpal tunnel at medium and high levels in all the patients, and the Tinel's and Phalen's test results were positive. Any bone pathology was not found in the patients' wrist graphics. During the period before the surgery a one-month treatment covering wrist splint and non-steroid anti-inflammatory medicine was applied to all the phenomena. The surgery was agreed to be applied to those who did not respond to conservative treatment. There was not any physiological reason potential to induce a carpal tunnel syndrome in the patients who had operation such as diabetes mellitus, gut, hypothyroid.

After the surgery the patients were monitored for averagely 16 months (range 10-24 months).

Surgical technique

The patients lied in the supine position on the

operating table. Tourniquet was tied. A hand table was used. Two-portal technique described by Chow was used for endoscopic surgery.⁽⁶⁾ The proximal point of pisiform bone at the wrist was found in order to define the location of incision place for the application of anesthesia. A transverse line of 1 cm drew beginning from 0.5 cm proximal of the radial point of 1-1.5 cm line towards the radial side constituted the cut line. The local anesthetic of 2 ml lidocaine 2 % (1/200000 adrenalin) was injected under the skin in the area between palmaris longus and flexor carpi ulnaris tendons, the incision area at proximal wrist fold. Approximately 1-1.5 cm of transverse skin and under skin cut was made. A deep fascia was observed and phleb was removed from distal. Carpal tunnel was retracted until the porta was seen (Figure 1a). At that time from a hole in the fascia, ulnar nerve which

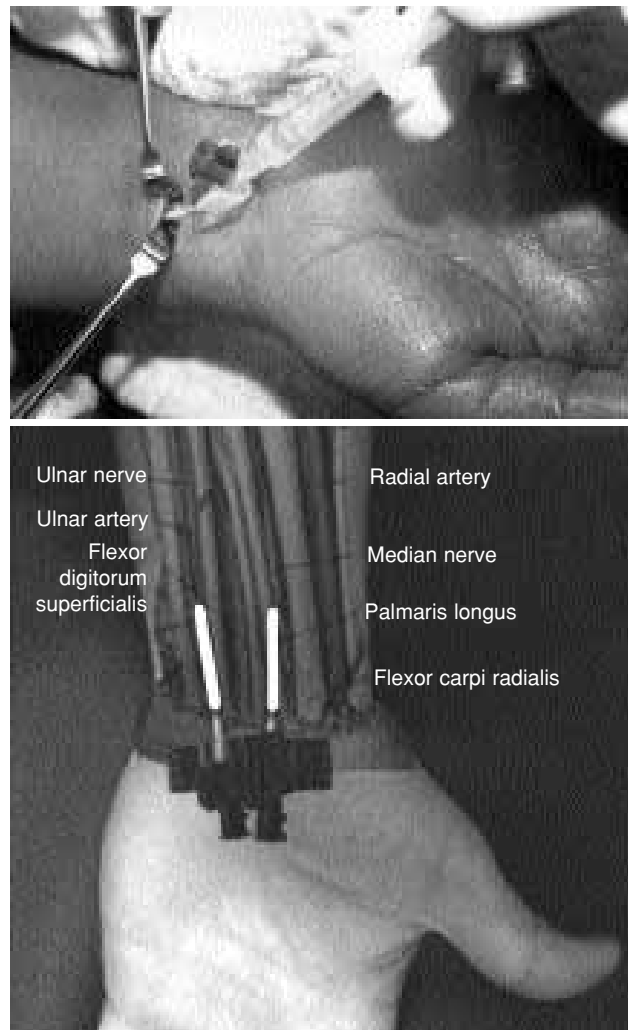


Figure 1. (a) Local anesthesia application during the surgery. (b) View of the application on a figure.

was located in the radial of flexor carpi ulnaris tendon and median nerve, and between palmaris longus (if not available the 4th metacarpus line) and flexor carpi radialis tendons was seen. In order to avoid injuring the nerves a number 20 plastic catheter with a cuneiform point was used as a trocar and so passed at least 4 cm proximal of the operation area. 5-7 ml lidocaine 2 % (1/200000 adrenalin) was injected around both nerves in such a way that it could not return to the operation area (Figure 1b). In the meantime the direct application of the local anesthetic at the nerve was avoided. And after a few minutes synovial dissection began. After the operation antibiotal prophylaxis was applied for 24 hours.

Conclusions

There were not any paresthesia complaints during the injection. Local anesthesia support and sedation for the cut area were required for the two wrists (14.3 %).

Complaints of all the phenomena before the operation were relieved. And any relapse during the monitoring was not seen in any of the patients. Pain in two wrists occurred in the early period after the operation. The period lasted 10 days in one, and two months in the other one.

Wounds in tendons, hematoma, sympathetic dystrophy and wounds in nerves did not occur in any of the phenomena. Neuropraxis in the third and the fourth fingers of a phenomenon was observed after the operation. Infection was not observed in any of the patients.

Discussion

The most common and well-known neuropathy of the upper extremities is that the median nerve is compressed at the wrist. Successful treatments can be applied through conservative methods; however, surgical treatment can be required for many patients.^(5,7) Different anesthesia techniques such as general anesthesia, Bier block, axillary or brachial block and local anesthesia were used for the mentioned surgery.^(2,6,8,9)

Altissimi and Mancini⁽¹⁰⁾ injected local anesthetic around the median nerve under flexor retinaculum for the open CTR. Paresthesia developed in half of the patients because of the said method which decreases the visual quality for the endoscopic method. Local anesthesia infiltration to the surface of flexor retinac-

ulum in open CTR surgery was reported to be adequate.^(11,12) Gibson⁽¹²⁾ reported that division of flexor retinaculum caused pains in some of the patients (4 %).

Wilson¹³ defined regional block anesthesia technique in distal forearm for the CTR surgery. The first entry point was just the radial of palmaris longus tendon (if not available, the median line of the forearm) with 45 degree, and lateral anti brachial cutaneous, median and median palmar cutaneous nerves block were obtained. The second entry for the ulnar block was radial of flexor carpi ulnaris tendon, 4-5 cm above of flexor fold complying with ring finger line. By this way medial antibrachial cutaneous, ulnar and ulnar palmar cutaneous nerves block were obtained. Both of the entries included subcutaneous and deep infiltration stages.

The most important advantages of endoscopic carpal tunnel surgery are the low rate of scar sensitivity and incision pain after the operation, and early return to the business life, and little deterioration of aesthetic view due to surgical scar. From this aspect, local methods seem to be more advantageous especially for the day's patients.^(7,13)

When compared to axillary and general anesthesia, local anesthesia infiltration time and operation time are shorter in this technique. Local anesthesia infiltration time is shorter. General anesthesia is quicker when compared to bier or axillary block.^(2,8)

There are many other advantages of this technique. Complications and side effects that can be seen in general anesthesia cannot be observed in this technique. It can safely be used for the patients with high risk of anesthesia. The patients can easily go on finger and hand movements; only the stroke in intrinsic muscles may be an advantage. Pain controlling after the operation is easier with the local anesthesia effect lasting six to eight hours.^(2,8)

Tourniquet can be used in this technique. Duration of tourniquet can vary according to miscellaneous factors depending on the patient, but pain caused by tourniquet generally occur between the 20th and 30th minutes of the application.⁽⁸⁾ This period may be inadequate for tenosynovectomy or external neurolysis; however, it is adequate for ECTR performed by an experienced surgeon. It can be chosen for patients with functional hemodialysis or blood dyscrasia

against general anesthesia.^(14,15) There were not any patients with those complaints in our study.

The method does not bear the risks of intravascular injection; infiltration can be performed 4 cm away from the surgery area with cuneiform point plastic cannula by seeing the median and ulnar nerves.⁽²⁾

Using tourniquet in intravenous regional anesthesia (bier block) is a must. However, this application is contraindicated especially for the patients with functional fistula and blood dyscrasia. And also when the tourniquet loosened it enters into systemic circulation as anesthetic medicine in large amounts. The level of local anesthetic in blood rises very much in one minute, and drops rapidly. This rise for a short period may lead to systemic toxic reactions including convulsion and cardiac disorders. Inadequate loosening of muscles has some drawbacks such that anesthesia may lose its effect in a short time just after the loosening of the tourniquet (as for pain control after the surgery), and it requires a follow-up (as for the loosening of the tourniquet), and it may be contraindicated for the infected patients and patients with tumors.⁽⁸⁾

One disadvantage of ECTR surgery is that the view is limited, and it is difficult to separate synovia and nerve tissue, and natal anomalies or pathologies may be missed because of the limited view.⁽¹³⁾ Because of the limited view superficial palmar arch, flexor tendon, digital median or ulnar nerve bear the risk to be injured. These problems may be overcome to some extent through experience; however, injection of local anesthesia into the surgery area increases the volume of synovial membrane and free fluid amount, and may impede clear view between endoscope and retinaculum.⁽²⁾ But these drawbacks are eliminated with the technique defined by Wood and

Logan.⁽⁵⁾ This technique is an applicable anesthesia technique since it enables quicker, more reliable and for the day applications.

References

1. Wilson KM. Distal forearm regional block anesthesia for carpal tunnel release. *J Hand Surg [Am]* 1993;18:438-40.
2. Abadir A. Anesthesia for hand surgery. *Orthop Clin North Am* 1970;1:205-12.
3. Ramamurthy S. Anesthesia. In: Green DP, editor. *Operative hand surgery*. 2nd ed. New York: Churchill Livingstone; 1988. p. 27-60.
4. Winnie AP. Regional anesthesia. *Surg Clin North Am* 1975; 55:861-92.
5. Wood SH, Logan AM. A local anaesthetic technique for endoscopic carpal tunnel release. *J Hand Surg [Br]* 1999;24:298-9.
6. Chow JC. Carpal tunnel release with the Chow endoscope. In: Blair WF, editor. *Techniques in hand surgery*. Philadelphia: Williams & Wilkins; 1996. p. 719-29.
7. Tzarnas CD. Carpal tunnel release without a tourniquet. *J Hand Surg [Am]* 1993;18:1041-3.
8. Weiss AP, Sachar K, Gendreau M. Conservative management of carpal tunnel syndrome: a reexamination of steroid injection and splinting. *J Hand Surg [Am]* 1994;19:410-5.
9. Atroshi I, Johnsson R, Ornstein E. Endoscopic carpal tunnel release: prospective assessment of 255 consecutive cases. *J Hand Surg [Br]* 1997;22:42-7.
10. Altissimi M, Mancini GB. Surgical release of the median nerve under local anaesthesia for carpal tunnel syndrome. *J Hand Surg [Br]* 1988;13:395-6.
11. Gale DW. Surgical decompression of the carpal tunnel using infiltrative anaesthesia: description of technique. *J R Coll Surg Edinb* 1991;36:341.
12. Gibson M. Outpatient carpal tunnel decompression without tourniquet: a simple local anaesthetic technique. *Ann R Coll Surg Engl* 1990;72:408-9.
13. Agee JM, McCarroll HR Jr, Tortosa RD, Berry DA, Szabo RM, Peimer CA. Endoscopic release of the carpal tunnel: a randomized prospective multicenter study. *J Hand Surg [Am]* 1992;17:987-95.
14. Minami A, Ogino T. Carpal tunnel syndrome in patients undergoing hemodialysis. *J Hand Surg [Am]* 1987;12:93-7.
15. Corradi M, Paganelli E, Pavesi G. Carpal tunnel syndrome in long-term hemodialyzed patients. *J Reconstr Microsurg* 1989; 5:103-10.