



# Management of fibular hemimelia with the Ilizarov circular external fixator

## *Fibular hemimelia: Ilizarov sirküler eksternal fiksatorü ile tedavi sonuçları*

**Mustafa BASBOZKURT, Cemil YILDIZ, Mahmut KOMURCU, Bahtiyar DEMIRALP, Mustafa KURKLU, A. Sabri ATESALP**

*Gulhane Military Medical Academy, Department of Orthopedics and Traumatology, Ankara*

**Amaç:** Bu çalışmada, tip IA, IB ve tip II fibular hemimelia saptanan olgularda ekstremitte eşitsizliği ve deformitelerin Ilizarov sirküler eksternal fiksatorü ile tedavi sonuçları değerlendirildi.

**Çalışma planı:** Fibular hemimelia tanısı konan beş erkek hastaya (ort. yaş 11.4; dağılım 4-20) Ilizarov tekniği ile tibiofibular osteotomi ve distraksiyon osteogenezisi uygulandı. Achterman ve Kalamchi sınıflandırmasına göre, üç hastada tip IA, birinde tip IB, birinde de tip II fibular hemimelia vardı. Üç olguda sağ, iki olguda sol fibula tutulumu saptandı. İki olguda ekin deformitesi, bir olguda da valgus deformitesi vardı. Ayak bileği ve diz ekleminde instabilite gözlenmedi. Olgularda ortalama kısalık 8.7 cm (dağılım 3-16.5 cm), uzatma indeksi ise ayda ortalama 1.6 cm (dağılım 1.4-2 cm) idi. Ortalama izlem süresi 33 ay (dağılım 15-68 ay) idi.

**Sonuçlar:** Son takiplerde tüm hastalarda diz hareketlerinin tam olduğu görüldü. Ayaklardan üçü plantgrad idi; birinde 17, diğerinde ise 15 derece ekin deformitesi kaldı. Komplikasyon olarak, dört olguda çivi dibi enfeksiyonu gözlemlendi ve oral antibiyotiklerle tedavi edildi. Üç olguda distraksiyon sırasında ağrı, ikisinde ayak bileği ekleminde hareket kısıtlılığı gözlemlendi. Fakat diz ve ayak bileğinde instabilite ve subluksasyon yoktu. Her iki olguya ait eklem sorunu da fizik egzersizlerle normale döndü.

**Çıkarımlar:** Tip I ve tip II fibular hemimelialı hastalarda açısal ve rotasyonel düzeltme ve uzatma tedavisinde Ilizarov tekniğinin seçkin bir yöntem olduğu görüldü.

**Anahtar sözcükler:** Anormallik, multipl/tanı/rehabilitasyon; kemik uzatma/yöntem; eksternal fiksator; fibula/anormallik/cerrahi/radyografi; Ilizarov tekniği; osteogenesis, distraksiyon.

**Objectives:** We evaluated the results of treatment with the Ilizarov circular external fixator for limb length inequality and deformities in patients with type IA, IB, and type II fibular hemimelia.

**Methods:** Tibial corticotomy and distraction osteogenesis with the Ilizarov technique were performed in five male patients (mean age 11.4 years; range 4 to 20 years). According to the classification of Achterman and Kalamchi, fibular hemimelia was type IA, IB, and II in three patients, one patient, and one patient, respectively. Involvement was on the right in three patients, and on the left in two patients. Two patients had equinus and one patient had valgus deformities. No instability existed in the ankle and knee joints. The mean leg discrepancy was 8.7 cm (range 3 to 16.5 cm), and the mean lengthening index was 1.6 cm/month (range 1.4 to 2 cm). The mean follow-up was 33 months (range 15 to 68 months).

**Results:** On final examinations, full range of motion of the knee was obtained. A plantigrade foot was achieved in three feet, while two sustained an equinus deformity of 17 and 15 degrees, respectively. Pin tract infections were observed in four patients, all of which were treated with oral antibiotics and dressing. During distraction, three patients had pain. Two patients had a limited range of motion of the ankle joint, without instability or subluxation of the ankle and knee joints. These joint problems were successfully dealt with by physical exercises.

**Conclusion:** The Ilizarov technique is a convenient method in the correction of angular and rotational deformities while enabling distraction in type I and type II fibular hemimelia.

**Key words:** Abnormalities, multiple/diagnosis; bone lengthening/methods; external fixators; fibula/abnormalities/surgery/radiography; Ilizarov technique; osteogenesis, distraction.

Fibular hemimelia is a congenital condition characterized with the partial or complete absence of the fibula. It may occur only from fibular shortness or it may be accompanied by absences of the femur, tibia, ankle and foot as well.<sup>[1,2]</sup> Achterman and Kalamchi<sup>[3]</sup> classified this condition according to the radiographic findings. Its clinical presentation frequently includes limb-length discrepancy, anteromedial bending in tibia, valgus deformity of the knee, hypoplasia of the lateral femoral condyle, equinovalgus deformity of the foot, and instability of the ankle.

The objective of the treatment for such cases is to gain a normal limb length, weight bearing, walking and gait pattern. Treatment for type I mild cases includes lengthening by shoe (lift), walking prosthesis, epiphysiodesis or limb lengthening procedures and correction of foot deformities. However, treatment for advanced deformities is controversial. Many researchers support early amputation and rehabilitation by prosthesis of the foot.<sup>[4,5]</sup> The advantages of the amputation treatment are single operation, shorter hospital stay, quick walking, limb-length equalization, faster return to daily activities because of better compliance while the disadvantages include irreversibility, necessity to replace the prosthesis periodically, and lack of normal sense and proprioceptive stimulation.

Limb lengthening by the Ilizarov technique is an alternative to the treatment by amputation. By this method, extremity is retained, and the foot and ankle deformities are managed by correction surgery combined with lengthening.<sup>[6-9]</sup> However, the disadvantages include necessity for multi-operations, achievement of lengthening in 2-3 phases, longer hospital stay and psychosocial pressure imposed on the family and the patient during the rehabilitation. Furthermore, sometimes, desired

functional and cosmetic outcomes cannot be achieved by this method, and amputation may be required.

The present study evaluated the results of treatment for limb length discrepancy and deformities by the Ilizarov circular external fixator in cases with type IA, IB and type II fibular hemimelia.

## Patients and method

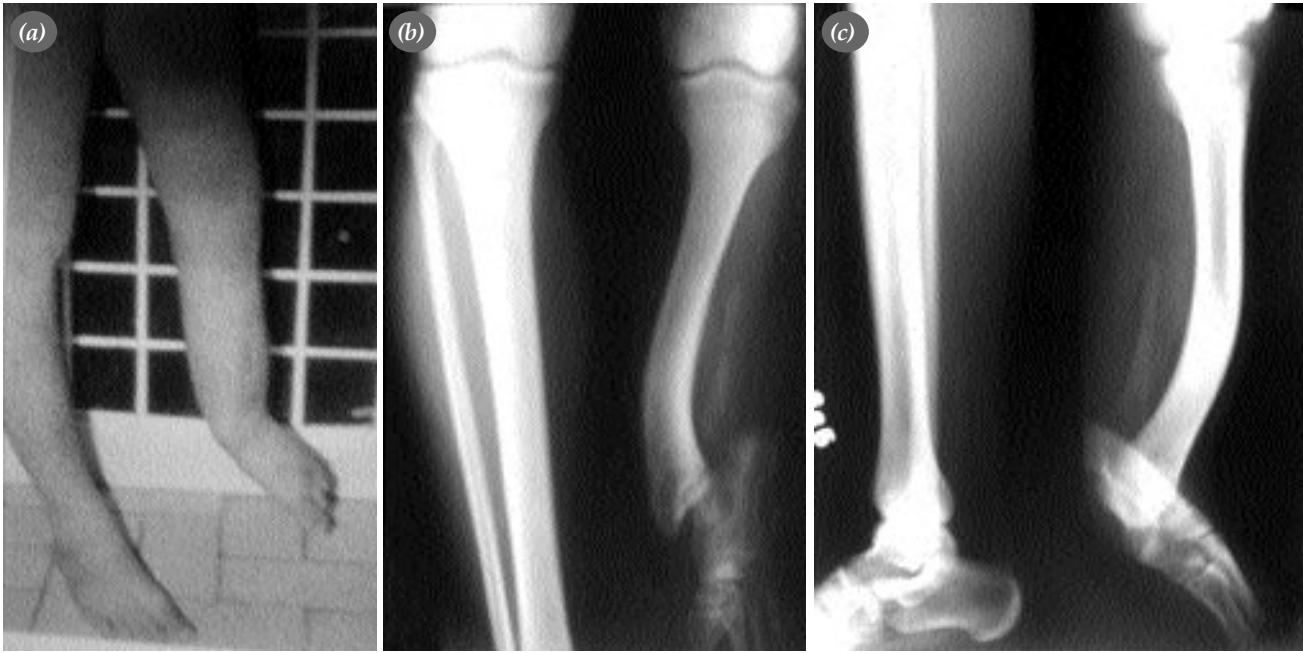Five male patients (mean age 11.4 years; range 4 to 20 years), who had radiographic diagnosis for fibular hemimelia, underwent tibiofibular osteotomy and distraction osteogenesis by the Ilizarov technique between August 1995 and July 2002. Types of fibular hemimelia were as follows; IA in three patients, type IB and type II in remaining patients according to the Achterman and Kalamchi classification. The involvement was in the right in three cases, and in the left fibula in two cases. Mean shortness was 8.7 cm (range 3 to 16.5 cm), and mean lengthening index was 1.6 cm (range 1.4 to 2 cm) per month (Table 1).

Previously prepared apparatus was applied onto the leg by 1.5 mm K-wires in accordance with the Ilizarov technique. The lengthening was carried out using corticomy and monofocal Ilizarov apparatus and system in all patients. Standard system was modified for angular and rotational corrections. A foot ring was used in two patients to prevent contracture and correct the foot deformities.

Distraction was initiated at a speed of 3x1/4mm from the motor unity four times a day, five days after the operation in all patients. It was changed to \_ mm four times a day by mounting the distraction rods following the correction of the deformity. Distraction was temporarily discontinued if knee contracture and paresthesia developed (3-5

**Table 1.** Evaluation of cases

No	Age	Sex	Type	Region/side with / deformity	Deformity plane(°)			Shortness (cm)
					Sagittal	Frontal	Oblique	
1	23	E	II	1/3 Distal tibia/left	35	20	41	16
2	16	E	IB	1/3 Proximal tibia/right	35	31	47	16.5
3	4	E	IA	1/3 Distal tibia/left	–	15	–	3
4	4	E	IA	1/3 Proximal tibia/left	36	–	–	3.5
5	13	E	IA	1/3 Proximal tibia/right	–	–	–	4.5

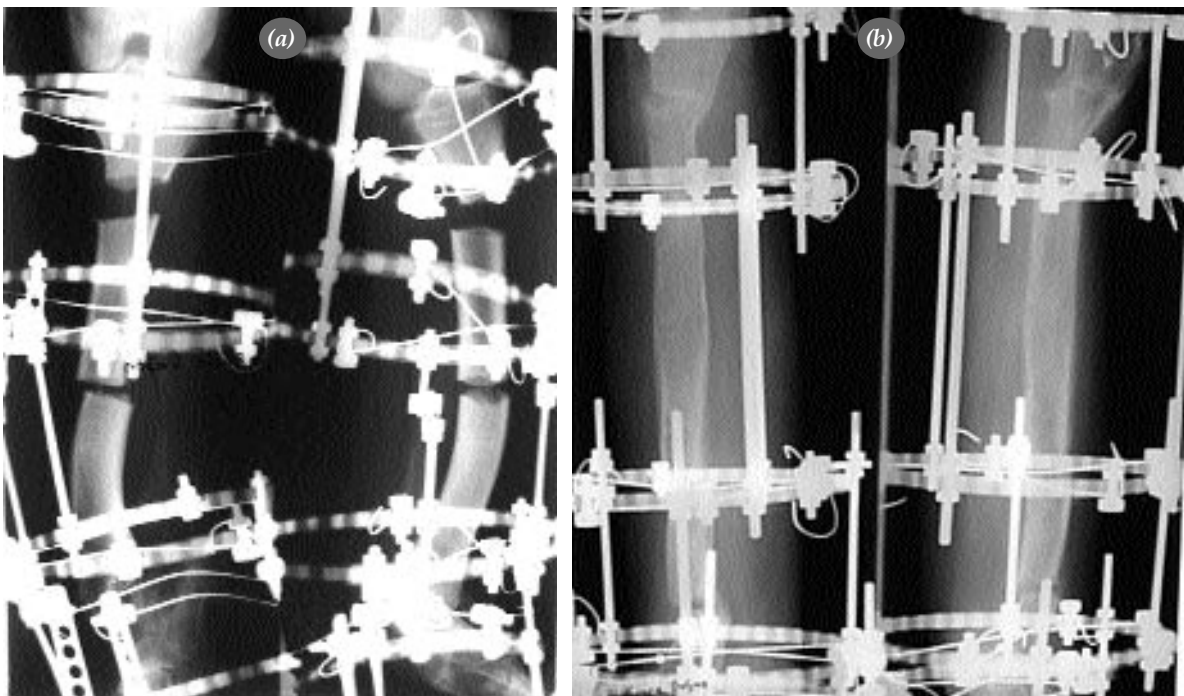


**Figure 1.** Preoperative (a) clinical presentation, (b) anteroposterior and (c) lateral graphs of the patient with a shortness of 16 cm in his foot.

days/month). Patients received psychological support from the psychologists throughout the treatment.

In cases with foot rings, foot component of the apparatus was removed after the lengthening in order to make the ankle move. In one case, the

extremity was immobilized by long-leg circular casting for a period of three weeks after the removal of the apparatus. And two patients were allowed to walk by a protective bracket for a period of two weeks upon removing the apparatus. Mean follow-up period was 33 months (range 15 to 68 months).



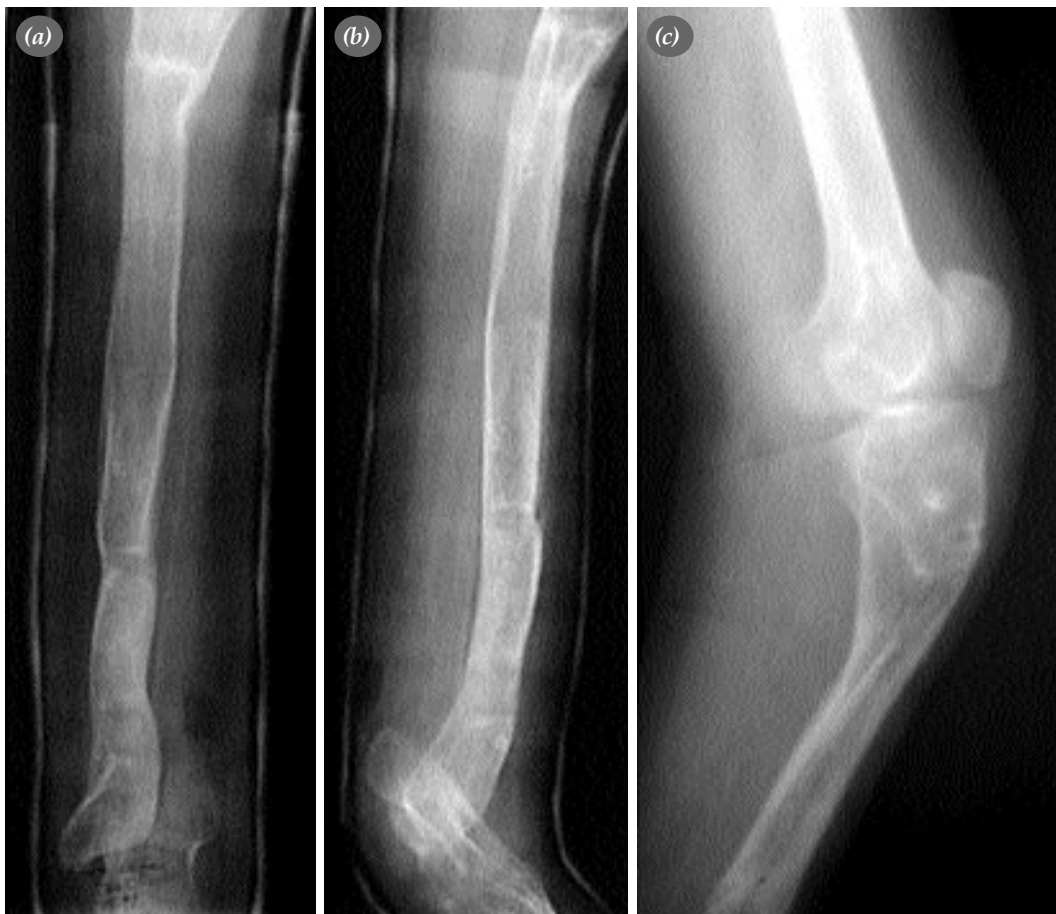**Figure 2.** Correction and distraction of the deformity by fixator. Clinical presentations at the (a) month first and (b) month 4 by anteroposterior and lateral views.

**Case sample:** Upper extremity radiograph taken at the first presentation (when he was 17 years old) of a twenty-year old male patient revealed a shortness of 16 cm in the left tibia and equinovalgus deformity in the foot (Figure 1ac). And oblique plane deformity was demonstrated in the 1/3 distal region of the tibia by upper extremity orthoroentgenography.

Radiographs of the left tibia were taken from 110 cm to define the angular values and true value of the deformity. As a result, it was found that there were 20, 35, and 41 degrees of deformity in the frontal, sagittal and oblique planes, respectively. During the preoperative planning, a circular external fixator was prepared for simultaneous removal of the shortness and deformity of the tibia and foot. For lengthening, the osteotomy was performed through the proximal metaphyseal region of the tibia while it was performed through deformity apex of the

oblique plane to correct the deformity. The tibial component of the circular external fixator apparatus was so prepared that there would be a full ring each at the proximal and distal of both osteotomy lines. For deformity of the foot, a foot component was prepared forming a calcaneal level by a semicircular ring and two posts attached to the ring in the forefoot.

The foot component was combined with the tibial component as to perform deformity correction without restriction (without hinges). Four Kirschner wires were properly inserted from the proximal ring of the tibia while two Kirschner wires from each medial and distal rings and calcaneus and forefoot. Two of the K wires inserted from the proximal ring were fixed to the ring by means of one-hole posts, providing two levels at the proximal of the osteotomy line. The operation plan included lengthening by proximal osteotomy; deformity correction and



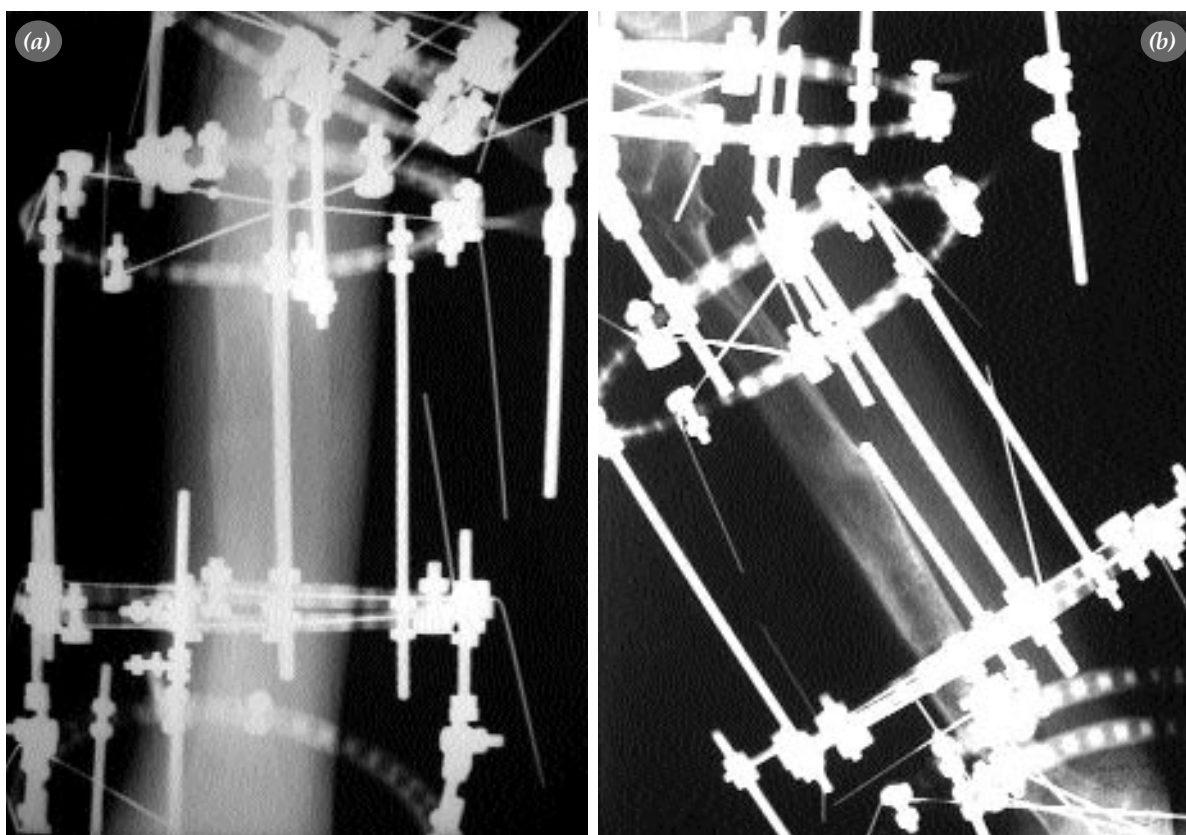
**Figure 3.** (a) Plain anteroposterior and (b) lateral graphs at postoperative month 15. (c) Lateral graph at month eight (first operation).

lengthening by distal osteotomy; and deformity correction (without any osteotomy and restriction) for foot deformity. By this apparatus, complete correction of 12 cm lengthening and tibial deformity was achieved (Figure 2a, b). For foot deformity, correction was achieved, foot being fixed 15 degrees to the equinus. Following the lengthening and correction, callus formation was followed up at the distraction site by plain radiographs every month. The apparatus was removed five months later as the callus formation seemed efficient (Figure 3a, b). Three months later, angulation (27 degrees sagittal plane) was observed in the distraction site of the tibial proximal since efficient and qualified formation of the callus couldn't be qualitatively assessed by plain radiography (Figure 3c). Twelve months later, a second operation was planned to correct the deformity of the sagittal plane and lengthen the 4 cm shortness. The tibial component consisting of one in the proximal and two full rings in the distal of the tibial deformity was properly combined with the foot component consisting of a calcaneal ring and forefoot ring (semicircular ring). We retained the foot in order to

maintain the foot corrections achieved during the first operation. Four K-wires were inserted from the proximal ring of the tibia to provide two levels while two from each level were inserted. Osteotomy was applied from the deformity apex, and connected to the deformity correction and distraction (Figure 4a, b) After the evidence of efficient callus formation in the distraction site by plain radiographs, computed tomography was taken for qualitative assessment. The apparatus was removed at month 9 following the evidence of efficient and qualified callus formation (Figure 5). Extremity equalization was achieved in the patient, and a plantigrade foot was produced by means of orthosis.

## Results

During follow-up examinations, formation of a usable leg, pre- and post-operative motion ranges of the knee and ankles, pre- and post-operative positions of the foot were evaluated. Tibial and femoral length discrepancies and degrees of the angular deformity were followed by the anteroposterior and lateral radiographs of the leg and



**Figure 4.** (a) Anteroposterior and (b) lateral views of the second fixator application.

**Table 2.** Treatment outcomes

No	Type	Follow-up period(month)	Amount of lengthening (cm)	Index of lengthening(cm/ay)	Complications
1	II	68	16	1.5	Pain during distraction, Limited motion of ankle 15 degrees of equinus deformity
2	IB	40	16.5	2.0	Pain during distraction, Limited motion of ankle 17 degrees of equinus deformity
3	IA	22	3	1.4	Broken K-wire Pin tract infection
4	IB	15	3.5	1.5	Pin tract infection
5	IA	20	4.5	1.5	Pain during distraction Mild pin tract infection

orthoroentgenogram of both lower extremities. Radiographs were taken at a two-week interval throughout the lengthening while it was monthly during the consolidation period. The lengthening and angular correction rates were followed.

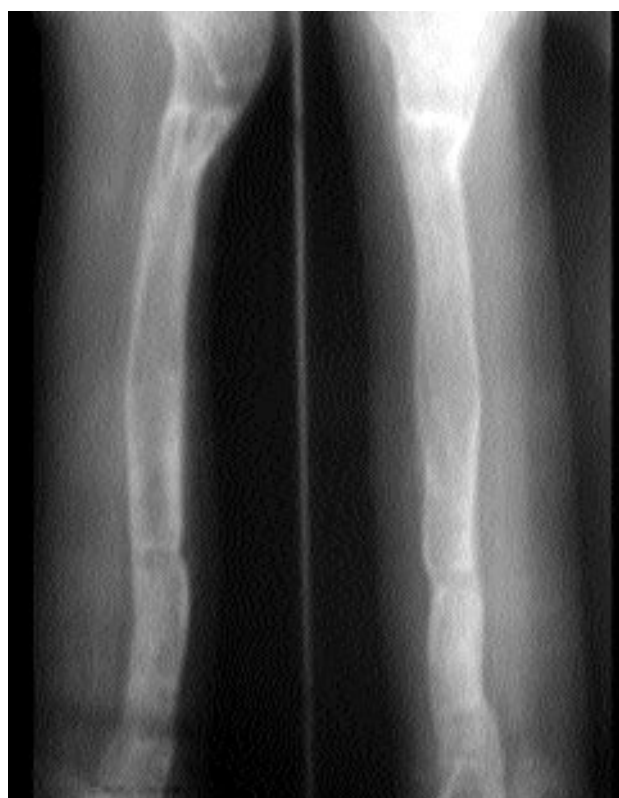Preoperative motions of the ankle were normal in three patients, and restricted in two patients. Three of the feet were plantigrade and two were equinus. One patient had radiographic abnormal talar configuration and tibio-talar contact area and ankle pain. Final examination showed full motion range of the knee in all patients. Three of the feet were plantigrade; one retained with 17 and the other with 15 degrees of equinus deformity.

Four cases had pin tract infection as complication, which was treated by oral antibiotics. During distraction, pain was observed in three, and restricted motion of the ankle joint in two patients. However, no instability and subluxation was found in the knee and ankle joint. The joint problem in two cases returned to normal by physical exercises. In one case (case 3), two broken K-wires were replaced (Table 2).

## Discussion

Shortness of the extremity, deformity and malformations of the foot are common as a result of congenital defect of the fibula. Expected outcomes of the treatment are as follow; managing shortness, correcting angulations and achieving a plantigrade foot. For patients who has shortness over 7.5 cm and malformed foot, and who are nonplantigrade, pros-

thesis is applied at first using Syme or Boyd amputations. Although this method has positive aspects like achieving outcome in a shorter period of time, shorter hospital stay and easy patient compliance, it is irreversible.<sup>[10]</sup> Numerous studies used Syme or other amputations for treatment.<sup>[10-12]</sup> Even tough we recommended amputation to the patients with type



**Figure 5.** After the removal of the apparatus, anteroposterior and lateral graphs at month three (second operation).

IB and type II fibular hemimelia due to their excessive shortness and foot malformations, they rejected amputation and preferred to undergo treatment by reconstruction and distraction using the Ilizarov circular external fixator.

Although lengthening by the Ilizarov technique accompanied with correction is considered an alternative to the amputation, it should be preferred in shortness less than 5 cm, and in patients with normal or relatively normal plantigrade foot (than can be passively plantigrade). It should be kept in mind that this technique has a higher morbidity, and it requires repeated surgeries.<sup>[13-15]</sup>

Choi et al.<sup>[13]</sup> indicated that in patients with 7 cm or less shortness or who requires lengthening less than 15%, lengthening can be performed by the Wagner technique, otherwise the outcome could be poor. We achieved extremity equalization in two cases with shortness of 16 and 16.5 cm by repeated lengthening and deformity correction operations. However, temporary psychological problems such as anxiety, unhappiness and desperation were observed in patients and their relatives. Those patients received psychological support from the psychologists.

Some researchers suggested implementation of lengthening only in carefully selected cases.<sup>[5,15-17]</sup> Dutoit et al.<sup>[11]</sup> reported that they had various problems in 22 of 26 patients who underwent lengthening due to fibular hemimelia; 20 patients had late period problems of shoe wearing and weight bearing. However, several studies reported good outcome with repeated lengthening.<sup>[8,9,18,19]</sup> Miller et al.<sup>[18]</sup> reported no serious complication and late period amputation in 12 cases who underwent lengthening by the Ilizarov technique. Jawish and Carliz stated foot correction in 60% of patients by lengthening.<sup>[8]</sup> McCarthy et al.<sup>[19]</sup> achieved normal limb length and gait in most of their patients by lengthening using the Ilizarov technique, and reported minimal pain and good activity. Unfortunately, in all of the above mentioned studies good outcomes were achieved accompanied with potential problems and complications to some extent.

In the treatment for fibular hemimelia by the Ilizarov technique, extreme shortness is managed, and angular, rotational and foot deformities are cor-

rected. In the present study, we achieved lengthening and angular correction in two patients; lengthening, angular and foot deformity correction in two patients; and only lengthening in one patient. A plantigrade foot was achieved in one patient.

However, in addition to the above-mentioned problems, some other complications may occur by the Ilizarov technique. Knee flexion contracture requiring aggressive physiotherapy may develop. Pin tract infections, although manageable by oral antibiotics, have a risk for osteomyelitis. One significant complication is the premature consolidation and frequently appearance of angulation in the new (regenerated) bone area resulting from the early removal of the apparatus. The radiographic image of the new bone should be carefully evaluated. If necessary, computed tomography should be used for assessing the maturation and density of the newly generated bone.<sup>[17]</sup>

Concomitant presence of congenital fibular shortness with crucial ligament defects is a relative contraindication in the Ilizarov technique.<sup>[4]</sup> No post-operative subluxation was observed in one of our cases in spite of the presence of preoperative knee instability.

In conclusion, angular and rotational corrections are also done while performing lengthening by the Ilizarov technique for the treatment of fibular hemimelia. Even extreme shortness can be managed by this technique, repeated surgery and distractions. However, patients and their relatives should be sufficiently informed about the potential problems, complications and requirement for repeated surgery and longer duration of the treatment period. Even tough new studies are required in order to minimize the potential complications; the Ilizarov technique is a convenient method for lengthening and correction in the treatment for fibular hemimelia.

## References

1. Bohne WH, Root L. Hypoplasia of the fibula. *Clin Orthop Relat Res* 1977;(125):107-12.
2. Berenter R, Morris J, Yee B. Bilateral congenital absence of the fibula. *J Am Podiatr Med Assoc* 1990;80:325-8.
3. Achterman C, Kalamchi A. Congenital deficiency of the fibula. *J Bone Joint Surg [Br]* 1979;61:133-7.
4. Epps CH Jr, Schneider PL. Treatment of hemimelias of the lower extremity. Long-term results. *J Bone Joint Surg [Am]* 1989;71:273-7.
5. Herring JA. Symes amputation for fibular hemimelia: a second

- look in the Ilizarov era. *Instr Course Lect* 1992;41:435-6.
6. Dal Monte A, Donzelli O. Tibial lengthening according to Ilizarov in congenital hypoplasia of the leg. *J Pediatr Orthop* 1987;7:135-8.
  7. Villa A, Catagni M. Hemimelia of the lower limb. In: Maiocchi AB, Aronson J, editors. *Operative principles of Ilizarov*. Baltimore: Williams & Wilkins; 1991. p. 376-93.
  8. Jawish R, Carlioz H. Conservation of the foot in the treatment of longitudinal external ectromelia. *Rev Chir Orthop Reparatrice Appar Mot* 1991;77:115-20. [Abstract]
  9. Catagni MA. Management of fibular hemimelia using the Ilizarov method. *Instr Course Lect* 1992;41:431-4.
  10. Westin GW, Sakai DN, Wood WL. Congenital longitudinal deficiency of the fibula: follow-up of treatment by Syme amputation. *J Bone Joint Surg [Am]* 1976;58:492-6.
  11. Dutoit M, Rigault P, Padovani JP, Finidori G, Touzet P, Durand Y. The fate of children undergoing bone lengthening in congenital hypoplasia of the legs. *Rev Chir Orthop Reparatrice Appar Mot* 1990;76:1-7. [Abstract]
  12. Fergusson CM, Morrison JD, Kenwright J. Leg-length inequality in children treated by Syme's amputation. *J Bone Joint Surg [Br]* 1987;69:433-6.
  13. Choi IH, Kumar SJ, Bowen JR. Amputation or limb-lengthening for partial or total absence of the fibula. *J Bone Joint Surg [Am]* 1990;72:1391-9.
  14. Hood RW, Riseborough EJ. Lengthening of the lower extremity by the Wagner method. A review of the Boston Children's Hospital experience. *J Bone Joint Surg [Am]* 1981;63:1122-31.
  15. Oppenheim WL. Fibular deficiency and the indications for Syme's amputation. *Prosthet Orthot Int* 1991;15:131-6.
  16. Letts M, Vincent N. Congenital longitudinal deficiency of the fibula (fibular hemimelia). Parental refusal of amputation. *Clin Orthop Relat Res* 1993;(287):160-6.
  17. Naudie D, Hamdy RC, Fassier F, Morin B, Duhaime M. Management of fibular hemimelia: amputation or limb lengthening. *J Bone Joint Surg [Br]* 1997;79:58-65.
  18. Miller LS, Bell DF. Management of congenital fibular deficiency by Ilizarov technique. *J Pediatr Orthop* 1992;12:651-7.
  19. McCarthy JJ, Glancy GL, Chnag FM, Eilert RE. Fibular hemimelia: comparison of outcome measurements after amputation and lengthening. *J Bone Joint Surg [Am]* 2000;82:1732-5.