

## The evaluation of patients undergoing total knee arthroplasty with or without patellar resurfacing

### *Total diz protezi uygulamalarında patella eklem yüzeyi değiştirilen ve değiştirilmeyen olguların değerlendirilmesi*

Alpaslan OZTURK,<sup>1</sup> Sadık BILGEN,<sup>2</sup> Teoman ATICI,<sup>3</sup> Ozgur OZER,<sup>2</sup> Omer Faruk BILGEN<sup>2</sup>

<sup>1</sup>Bursa High Specialty Training and Research Hospital Clinic of Orthopaedics and Traumatology; <sup>2</sup>Uludağ University Medical Faculty Department of Orthopaedics and Traumatology; <sup>3</sup>Ministry of Health Çekirge Hospital Clinic of Orthopaedics and Traumatology

**Amaç:** Total diz protezi (TDP) uygulamalarında patella eklem yüzeyinin değiştirilmesinin ve değiştirilmemesinin klinik ve radyografik sonuçlara etkisi değerlendirildi.

**Çalışma planı:** Primer diz osteoartriti nedeniyle TDP uygulanan ve yeterli takibi olan 126 hastanın 149 dizi incelendi. Elli dokuz dizde (grup 1) patella eklem yüzeyi değiştirilirken, 90 dizde (grup 2) değiştirilmedi. Klinik değerlendirmede KSS (Knee Society Score) diz ve fonksiyon puanları ve patella puanı, radyografik değerlendirmede eklem çizgisinin yer değiştirme miktarı, Insall-Salvati oranı, lateral patellofemoral açı ve uyum açısı kullanıldı. Grup 1'de ortalama takip süresi 66.7 ay (dağılım 34-123 ay), grup 2'de ise 68.1 ay (dağılım 30-117 ay) idi.

**Sonuçlar:** Her iki grupta da, ameliyat öncesine göre ameliyat sonrası diz ve fonksiyon puanları anlamlı derecede düzelmesine ( $p<0.001$ ) rağmen, iki grup arasında diz ve fonksiyon puanları anlamlı farklılık göstermedi ( $p>0.05$ ). Patella puanlama sistemiyle yapılan değerlendirmede de iki grubun ameliyat sonrası puanları anlamlı farklılık göstermedi ( $p>0.05$ ). Ameliyat sonrası radyografik değerlendirmede, iki grup arasında dizlerin mekanik aks değerleri, patellar tilt ve lateral subluksasyon açısından anlamlı fark bulunmadı ( $p>0.05$ ). Her iki grupta da ameliyat sonrasında patellanın semptomatik subluksasyonu, dislokasyonu, kırığı ve ekstansör mekanizma yırtığına rastlanmadı; patella veya patellar protezle ilgili revizyon yapılmadı.

**Çıkarımlar:** Patella eklem yüzeyinde ileri derecede dejeneratif değişikliği olan olgular dışında, patella eklem yüzeyinin değiştirilmemesinin uygun olacağı kanısındayız.

**Anahtar sözcükler:** Artroplasti, replasman, diz; diz protezi; osteoartrit, diz/cerrahi; patella/cerrahi.

**Objectives:** We evaluated the clinical and radiographic results of total knee arthroplasty (TKA) with or without patellar resurfacing.

**Methods:** The study included 149 knees of 126 patients who underwent TKA for primary knee osteoarthritis with (59 knees, group 1) or without (90 knees, group 2) patellar resurfacing. Clinical evaluations were made with the knee and function scores of the Knee Society, and patella scoring system; radiographic evaluations included changes in the joint line, Insall-Salvati ratio, lateral patellofemoral angle, and congruency angle. The mean follow-up period was 66.7 months (range 34 to 123 months) in group 1, and 68.1 months (range 30 to 117 months) in group 2.

**Results:** Although postoperative knee and function scores showed significant improvements in both groups ( $p<0.001$ ), these did not reach significance between the two groups ( $p>0.05$ ). The mean patella scores did not differ significantly, either ( $p>0.05$ ). Postoperative radiographic assessments did not show significant differences between the two groups with respect to mechanical axis values, patellar tilt, and lateral subluxation ( $p>0.05$ ). Symptomatic patellar subluxation, dislocation, fracture or rupture of the extensor mechanism did not occur in any of the treatment groups. None of the patients required revision associated with the patella and patellar prosthesis.

**Conclusion:** Our findings suggest that patellar resurfacing is not necessary other than patients with significant degeneration of the patellar surface.

**Key words:** Arthroplasty, replacement, knee; knee prosthesis; osteoarthritis, knee/surgery; patella/surgery.

Total knee arthroplasty (TKA) is a method with good long-term results, which is indicated in the absence of any response to the medical and other surgical treatment options in patients with advanced osteoarthritis. The objective of the total knee arthroplasty is to relieve the pain, restoring the impaired mechanical axis of the lower extremity in order to bear the weight on the knee physiologically and perform the daily activities with ease.

It was reported that during the first years of knee prostheses, anterior knee pain developed due to use of the technique for tibiofemoral joints only and inefficient design of the prosthesis in approximately 50% of the cases.<sup>[1-3]</sup> Patellar surfacing has become part of the knee prosthesis procedures in designs which were developed in order to eliminate the anterior knee pain and associated functional loss resulting from the knee prosthesis.<sup>[2,4-8]</sup> However, as a result of this approach, complications such as wear of the patellar implant up to 30%, loosening, patellar fracture, patellar subluxation and dislocation, patellar ligament and tendon tears, and instability of the patellofemoral joint during motion have been reported.<sup>[4,5,9-17]</sup> Presence of complications associated with the implementation of the technique in patients with and without patellar resurfacing resulted in a controversy.<sup>[1-9]</sup> In the literature, there are several studies including clinical and radiographic results of applications with patellar resurfacing in all cases, without any resurfacing in none of the cases, and with resurfacing in some of the cases for knee prosthesis.<sup>[8,9,18-21]</sup>

The present study evaluated the effect of knee prosthesis with and without patellar resurfacing on the clinic and radiographic results.

### Patients and method

The knees of 126 patients (149 knees; 59.8%) out of 201 (249 knees) who underwent primary TKA without retaining the posterior cruciate ligament for primary knee osteoarthritis between May 1991 and October 1998 with appropriate follow-up, medical records and final check-up were retrospectively reviewed. The total knee arthroplasty was applied with patellar resurfacing in 59 knees (39.6%) (Group 1; 47 females, 5 males; mean age 61.8 years; range 44 to 73 years) and without patellar resurfacing in 90 knees (60.4%) (Group 2; 61 females, 13 males; mean age 65.5 years; range 46 to 78 years).

In Group 1, the following knee prostheses were used; Aesculap Search (Tuttlingen, Germany) in 41 knees (69.5%), Maeva (Paris, France) in seven (11.9%), LCS (Depuy, Warsaw, Indiana, USA) in five (8.5%), and Osteonics (Osteonics, Allendale, New Jersey, USA) in six knees (10.2%) while in Group 2 they were Aesculap Search in 77 (85.6%), LCS in six (6.7%) and Osteonics (7.8%) in seven knees.

During the initial TKA procedures in our clinic, the procedure was usually performed with patellar resurfacing, which was then employed only in cases with significant damage to the patellar cartilage. According to the Outerbridge<sup>[22]</sup> classification, which is used in evaluating the degenerative changes of the patellar surface, 24 (40.7%) of the knees with patellar resurfacing (Group 1) were Grade IV. The mean follow-up period was 66.7 months (range 34 to 123 months) in Group 1, and 68.1 months (range 30 to 117 months) in Group 2.

### Surgical technique

The knee joint was approached anteriorly through the medial parapatellar arthrotomy following the anterior longitudinal skin incision using a tourniquet. The patella was everted and displaced laterally. The meniscuses were removed by excising the cruciate ligaments. Appropriate release was performed in order to establish a soft tissue balance. Auxiliary tools were used for the incision of the tibial and femoral heads. Flexion and extension space balancing of the soft tissues was checked. Using the test prostheses, the lower extremity axis, motion range of the knee joint and movement of the resurfaced or non-resurfaced patella in the femoral groove were reviewed. During the assessment of the motion range of the knee joint, the patellar congruency in the femoral groove was enhanced by means of releasing of the lateral retinaculum in five patients (8.5%) in Group 1 where the patella had a tendency for lateral dislocation, and in eight patients (8.9%) in Group 2. In order to enhance the patellar congruency in non-resurfaced knees, patelloplasty was performed, including lateral patellar soft-tissue release, decompression of the subchondral bone and patellar osteophyte excision for facilitating the patellofemoral movement, and cauterization of the paternal edge for partial denervation.<sup>[9]</sup> Afterwards, the bone surfaces were debrided and the prostheses were fixed by cement. All prostheses were of anatomic type (for

right and left knees); all conyldular type and each type of patellar implants were made of polyethylene. After the bleeding control, a hemovac drain was placed into the joint cavity, draping the tissues in accordance with the anatomy.

An intravenous dose of cefuroxime axetil 3x750 mg was administered for infection prophylaxis two hours before the operation and for 48 hours after the operation. Low-molecular weight heparin as prophylaxis initiated preoperatively against thromboembolism was continued for 15 days after the operation. In-bed exercises were initiated immediately after the operation, and the patients were mobilized at the first postoperative day. Exercises for range-of-motion of the joints were started at the postoperative day 1, and achievement of a 90° flexion was targeted until the end of the first week.

### Radiographic evaluations

For radiographic evaluations, an orthoroentgenography of the lower extremity to be operated, standing anteroposterior and lateral views, and Laurin and Merchant views were obtained and evaluated.<sup>[23-26]</sup> The Knee Society Total Knee Roentgenographic Evaluation and Scoring System was used for all evaluations.<sup>[27]</sup>

For preoperative and postoperative evaluations of the joint line, the measurement was based on from the lateral femoral epicondyle-femur and distal joint surface to the fibular head-distal femoral joint surface as the reference frame.<sup>[28-30]</sup> The ratio of the length of the patellar joint surface (P) to the length of the patellar tendon (T) (P/T ratio), indicating the relationship of the patella with the joint line was measured using the Insall-Salvati method.<sup>[24]</sup> For the radiographic assessment of the knee osteoarthritis, Ahlbäck classification system was used.<sup>[31]</sup>

### Clinical evaluations

Clinical evaluations were made using the KSS (Knee Society Score) criteria during the preoperative and postoperative controls. Furthermore, patellar scoring system was used during the final clinical assessments.<sup>[32,33]</sup>

Statistical calculations were performed using the matched t-test and Mann-Whitney U-test.

## Results

### Clinical results

In the patellar resurfaced group (Group 1), the mean KSS knee and function scores were 35.7±10.1 (range 0 to 48) and 45.2±8.7 (30 to 60), respectively before the operation, and 87.1±11.3 (54 to 97) and 87.6±16.4 (30 to 100), respectively after the operation. In the non-resurfaced group (Group 2), the mean knee and function scores were 31.2±11.2 (0-47) and 49.9±6.0 (30-60), respectively before the operation, and 89.0±9.6 (63-100) and 91.3±13.6 (20-100), respectively after the operation (Table 1). There was a significant difference between the preoperative and postoperative knee and function scores in both groups ( $p<0.001$ ). Analysis of changes from the baseline in the knee and functions scores showed no significant difference ( $p>0.05$ ).

In the assessments by the patellar scoring system, the mean postoperative score was 27.3±1.2 (range 24-30) in Group 1, and 26.3±2.3 (20-30) in Group 2 (Table 1). The difference between the two groups was insignificant ( $p>0.05$ ).

During the final postoperative control, anterior knee pain was observed in eight knees (13.6%) in Group 1, and 14 knees (15.6%) in Group 2. The pain was mild in all cases except one patient with a severe pain in Group 2. None of the 22 knees with anterior knee pain underwent lateral releasing. Difficulty in

**Table 1.** Preoperative and postoperative KSS and patella scores in knees, which underwent total knee arthroplasty with and without patellar resurfacing

Patella Joint surface	Knee (n)	KSS							
		Knee score			Function score			Patella score	
		Pre-operative	Post-operative	<i>p</i>	Pre-operative	Post-operative	<i>p</i>	Post-operative	<i>p</i>
Resurfaced	59	35.7	87.1	<0.001	45.2	87.6	<0.001	27.3	<0.01
Non-resurfaced	90	31.2	89.0	<0.001	49.9	91.3	<0.001	26.3	<0.01

KSS: Knee Society Score.

**Table 2.** Preoperative and postoperative Insall-Salvati ratios, patellar tilt and patellofemoral congruency in knees, which underwent total knee arthroplasty with and without patellar resurfacing

Patella joint surface	Knee (n)	Insall-Salvati ratio (P/T)			Patellar tilt		Patellofemoral congruency	
		Pre-operative	Post-operative	<i>p</i>	Patellar tilt (n)	Ang. to lateral (n)	Normal (n)	Lateral subluxation (n)
Resurfaced	59	0.8	0.9	>0.05	5	54	48	11
Non-resurfaced	90	0.8	0.8	>0.05	6	84	73	17

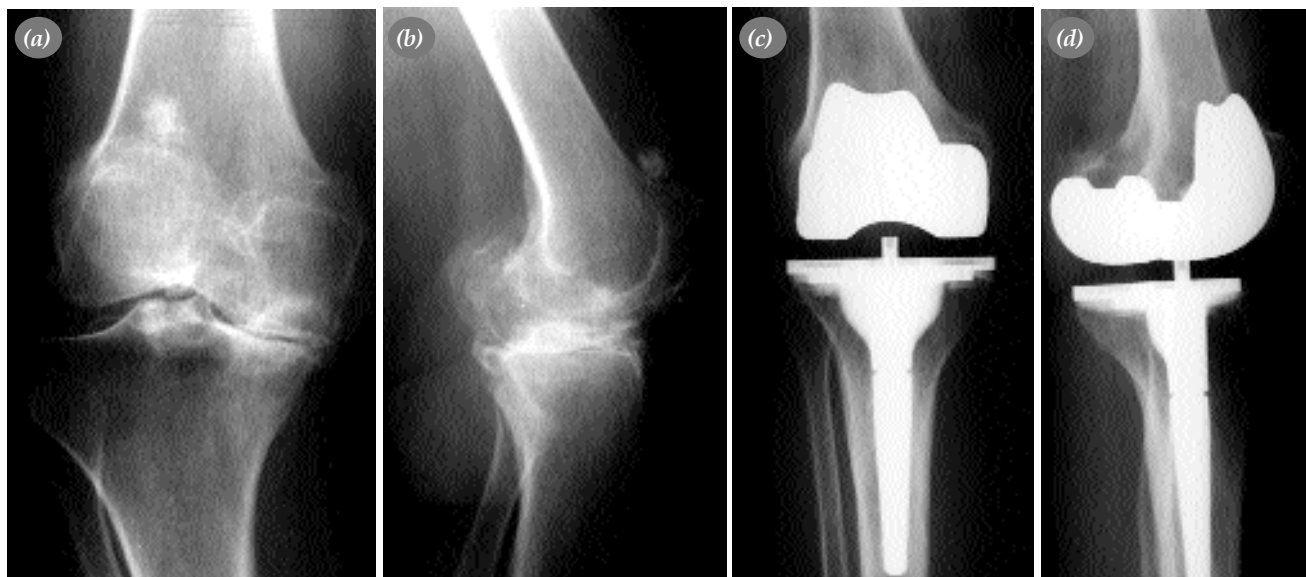stair climbing was observed in nine knees (15.3%) in Group 1, and 13 knees (14.4%) in Group 2.

### Radiographic results

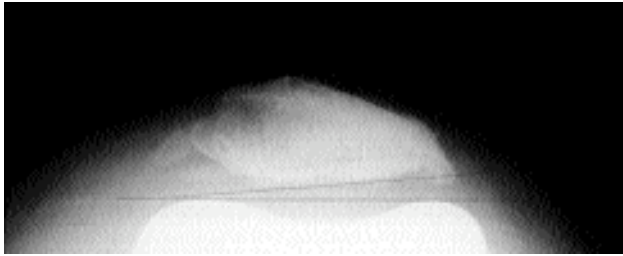
The preoperative lower extremity mechanical axis was in a mean varus of 11° (range 0°-32°) in 54 knees (91.5%), and a valgus below 10 degrees in five knees (8.5%) in Group 1, while it was neutral in 52 knees (88.1%), in 1° varus in two knees (3.4%), and in valgus below 4 degrees in five knees (8.5%) after the operation ( $p < 0.001$ ). The preoperative lower extremity mechanical axis was in a mean varus of 16° (0°-33°) in 89 knees (98.9%), 1° valgus in one knee, while it was neutral in 67 knees (74.4%), in 1° varus in eight knees (8.9%), and in valgus below 4 degrees in 15 knees (16.7%) after the operation in Group 2 ( $p < 0.001$ ) (Figure 1). Analysis of change from the baseline between both groups showed no significant difference ( $p > 0.05$ ).

The mean change in the joint line from the lateral epicondyle of the femur and distal joint surface of the femur to the fibular head and distal joint surface of the femur was 2.9 mm (-10±9) and 3.5 mm (-7±15) respectively in Group 1, and 2.4 mm (-12±11) and 3.9 mm (-10±11) to proximal, respectively in Group 2 ( $p > 0.05$ ). The preoperative and postoperative ratio of the length of the patellar joint surface (P) to the length of the patellar tendon (T) (P/T ratio), indicating the relationship of the patella with the joint line measured using the Insall-Salvati method were 0.8 (0.6-0.9) and 0.9 (0.6-1.1) respectively in Group 1 ( $p > 0.05$ ), and 0.8 (0.6-1.1) and 0.8 (0.6-0.9), respectively in Group 2 ( $p > 0.05$ ) (Table 2).

Radiolucence was observed in zone 1 in one knee (1.7%), and zones 1 and 2 in one knee in Group 1; and in zone 1 in the tibial component in two knees (2.2%) in Group 2. The radiolucence was less than 2 mm in those cases.



**Figure 1.** (a, b) Ahlbäck phase V degenerative changes are evident in the anteroposterior and lateral knee roentgenography of the sixty-two years old female patient. (c, d) The anteroposterior and lateral views 60 months after the total knee arthroplasty without patellar resurfacing.



**Figure 2.** Evaluation of the lateral patellofemoral angle of the Laring view obtained 76 months after the total knee arthroplasty without patellar resurfacing on the right knee of a sixty-three years old female patient.

The postoperative patellar tilt (lateral patellofemoral angle) was medial in five knees (8.5%) in Group 1, and six knees (6.7%) in Group 2, while it was laterally less than 5 degrees in 54 knees (91.5%) in Group 1, and 84 knees (93.3%) in Group 2 (Table 2, Figure 2). No significant difference was found between the two groups in patellar tilt ( $p>0.05$ ). And there was no significant difference between the patella scores of the knees with postoperative patellar tilt (angulation to medial) in Groups 1 and 2 ( $p>0.05$ ).

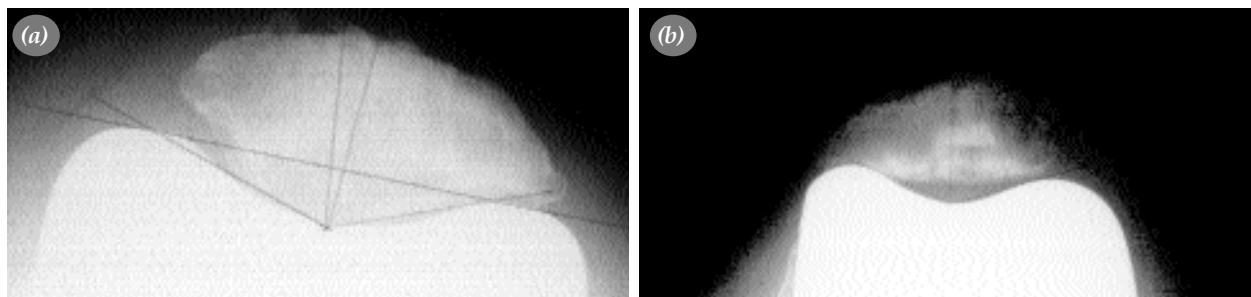
The postoperative patellofemoral congruence angle was normal in 48 knees (81.4%) in Group 1, and 73 knees (81.1%) in Group 2. Lateral subluxation was found in 11 knees (18.6%) in Group 1, and 17 knees (18.9%) in Group 2 (Table 2) (Figure 3). In the assessment of the patellofemoral congruence, there was no significant difference between the two groups ( $p>0.05$ ). And there was no significant difference between the patella scores of the knees with postoperative lateral congruence angle in Groups 1 and 2 ( $p>0.05$ ).

No symptomatic patellar subluxation, dislocation, and fracture or rupture of the extensor mechanism

were observed in both groups, and no revision of patella or patellar implant was required.

## Discussion

Patellar resurfacing has been recommended on the basis of the high incidence of pain associated with the patella during the first years of the tibiofemoral knee prosthesis.<sup>[1-3]</sup> However, with patellar resurfacing, complications such as anterior knee pain, polyethylene wearing, patellar fracture, loose component, synovial compression, patella clunk syndrome, osteonecrosis, separation of the metal back in the metal backed-patellar component may occur.<sup>[2,9,16,21,34-38]</sup> But, it has been reported that as a result of the developments in the TKA designs during recent years, patellofemoral complications as a cause of morbidity and revision are reduced in cases with or without patellar resurfacing.<sup>[9,36,39-41]</sup> The question of whether to resurface the patella or not during primary total knee arthroplasty has an effect on the outcome still remains controversial.<sup>[2,3,19,27,31,33,41-49]</sup> Ranawat<sup>[2]</sup> who performed TKA with patellar resurfacing on 100 knees of 77 cases, where 34 had osteoarthritis and 43 rheumatoid arthritis, and who followed them up for a period of 5-10 years reported that he obtained excellent results in more than 90% of his patients. In a study on 73 knees of 63 cases with a follow-up period of 16 years (range 16 to 21 years) at least, Gill et al.<sup>[41]</sup> performed TKA with patellar resurfacing and reported good-excellent results in 67 knees (93%) in accordance with the KSS assessment criteria. Feller et al.<sup>[33]</sup> reported that there was no significant difference between the two groups in terms of good-excellent results in a study where they divided 40 cases with a diagnosis of osteoarthritis into two groups, one with patellar resurfacing and other without patellar resurfacing, undergoing TKA and being followed up for a period of 3 years.



**Figure 3.** Evaluation of the patellofemoral congruency on a Merchant view. (a) view of a sixty-two years old male patient 54 months after the total knee arthroplasty without patellar resurfacing on the left knee. (b) view of a sixty-five years old female patient 84 months after the total knee arthroplasty with patellar resurfacing on the left knee.

Levitsky et al.<sup>[19]</sup> performed TKA without patellar resurfacing in 79 knees of 66 cases with a mean follow-up period of 7.5 years (range 2.4 to 15.5 years) and reported that 89.5% of the patients were satisfied with the outcome of the surgery. Sen et al.<sup>[40]</sup> followed up 68 knees of 55 patients where 31 knees (45.6%) underwent TKA with patellar resurfacing, and 37 knees (54.4%) without patellar resurfacing for a mean follow-up period of 34.8 months (range 17 to 50 years), and they found that the mean preoperative and postoperative KSS knee scores were 42 and 77.7 respectively in the group with patellar resurfacing, and 43.3 and 77.1 respectively in the group without patellar surfacing; and the function scores were 48.1 and 84.5 respectively in the first group, and 57 and 85.9 respectively in the second group, and reported that there was no statistically significant difference between the two groups. In the present study, the good-excellent results we obtained in 54 knees (91.5%) in Group 1 and 84 knees (93.3%) in Group 2 according to the KSS scoring system are consistent with the literature.

There are some researchers who perform patellar resurfacing in all or none of the total knee arthroplasty procedures as well as some other researchers who perform resurfacing in some cases, but not in the others.<sup>[19,19,21,50]</sup> In a survey carried out with 597 orthopedicians in the United Kingdom, Phillips et al.<sup>[50]</sup> found that 32% of the respondents always resurface the patella while 19% never resurface it, and 49% are selective, and the most frequent resurfacing criteria is the damage to the cartilage of the patellar joint surface during the operation. However, it is also known that the indications for the orthopedicians who are selective in patellar resurfacing are diverse in the literature. While resurfacing has been recommended in the presence of advanced patellofemoral arthritis, in cases with advanced deformity and patellofemoral incongruency, and in the presence of inflammatory osteoarthritis, it shouldn't be resurfaced in patients with small and osteopenic patella, and in active and young patients with a moderate damage to the patellar cartilage.<sup>[19,19,21]</sup> Sen et al.<sup>[40]</sup> performed TKA with patellar resurfacing in 31 knees (45.6%) and without patellar resurfacing in 37 knees (54.4%), and indicated that the decision to resurface was based on the evaluation of the damage to the patellar cartilage during surgery, and the damage was assessed using the Outerbridge<sup>[22]</sup> classification. In a study with long-

term results of 684 patients who underwent TKA, 396 knees with patellar resurfacing and 495 knees without patellar resurfacing, Boyd et al.<sup>[34]</sup> reported that they resurfaced the patella in case of significant cartilage loss, in broad irregularity of surfaces where the subchondral bone is exposed and in knees where the patellofemoral movement is incongruent. In the present study, our criterion to resurface the patella in patients treated with TKA based on the diagnosis of primary osteoarthritis was the degree of damage to the cartilage.

It has been reported that if the lower extremity mechanical axis is within the physiological limits following the total knee arthroplasty, then potential problems in the tibial, femoral components and the extensor mechanism could be reduced.<sup>[37,47,51,52]</sup> In a study by Jeffery et al.<sup>[51]</sup> with a follow-up period of at least eight years for 115 TKA cases, the mechanical axis passed through the middle 1/3 of the prosthesis, and the subsequent loosening was 3% in 68% of the cases; and in cases where the mechanical axis passed through other parts of the prosthesis, the incidence of loosening was increased to 24%, and they concluded that the difference was significant, highlighting that a mechanical axis within the normal limits is one of the major factors in preventing the loosening. Tokgözoglu<sup>[47]</sup> indicated that one of the causes of the patellar complications found 11% in 100 knees of 81 patients who underwent TKA with patellar resurfacing, is the insufficient correction of the impaired preoperative mechanical axis of the lower extremity following the surgery, and reported that the mechanical axis was in extreme valgus in three of the five knees with patellar dislocation. As a result of the TKA without patellar resurfacing, Smith et al.<sup>[37]</sup> indicated that majority of the patellofemoral complications they have as 8% is associated with impaired extensor mechanism, but not attributable to the non-resurfacing of the patella; and they suggested that this problem can be avoided by evaluating the congruency of the patellofemoral movement during the operation. In the present study, we believe that one of the causes why our clinical results in the groups with and without patellar resurfacing are consistent with the literature can be explained by the mechanical axis being within the physiological limits.

The joint line retained within the physiological limits following the total knee arthroplasty has an



impact on the successful postoperative outcome.<sup>[9,38]</sup> In a study where the effect of patellofemoral joint in 116 knees of 101 cases who underwent TKA without retaining the posterior cruciate ligament on the postoperative clinical and radiographic results was evaluated, Figgie et al.<sup>[38]</sup> reported that patellefemoral mechanics influenced the postoperative knee scores and motion range of the joint, and the results were satisfactory in changes which are less than 8 mm in the joint line. In a study which reported the results of a mean follow up period of 5.2 years (range 2 to 10 years) for 52 cases who had bilateral TKA and in whom the patella was resurfaced on one side and not on the other, Keblish et al.<sup>[9]</sup> found that the mean change to the proximal of the joint line was 3.52 mm (-7 and +12) in the group with patellar resurfacing, and 1.98 mm (-4 and +13) in the group without patellar resurfacing; and they indicated that there was no significant difference between the groups, and very good results were achieved even in one case of each group where the joint line was moved proximally for more than 10 mm. In the present study, no significant difference was found between the groups in respect to the change of the joint line to proximal. We believe that changes to proximal less than 8 mm in the average are effective in achieving successful results.

Various results have been reported related with patellar tilt and malposition of the patellar prosthesis due to lateral retinacular tension, internal rotation of the femoral or tibial component, failure to balance the soft tissue, instability due to trauma and extreme valgus position of the knee (subluxation and dislocation) in TKA procedures with and without patellar resurfacing.<sup>[2,11,12,15,18,34,40,49,52,53]</sup> In a study on 234 knees of 183 cases who had TKA with patellar resurfacing, Bindelglass et al.<sup>[11]</sup> reported that no patellar tilt and subluxation were found in 128 knees (54.7%), but lateral angulation in 42 (17.9%), medial tilt in 30 (12.8%), and lateral subluxation in 34 (14.5%) knees; during the evaluations of 158 knees with a follow-up period of at least two years (24 to 75 months), no significant difference was found between the 88 knees with no patellar incongruence and the 70 knees with incongruence. In a radiographic evaluation following 85 TKA cases with patellar resurfacing and 96 without patellar resurfacing, Yücel<sup>[49]</sup> reported lateralization in 17 (20%), and dislocation in four (4.7%) knees in the patellar resurfacing group while lateralization in 28 (29.2%), subluxation in six (6.2%) and disloca-

tion in two (2.1%) knees in the non-resurfacing group. Sen et al.<sup>[40]</sup> reported that they had no patellar tilt or subluxation in a study on 31 knees (45.6%) which underwent TKA with patellar resurfacing, and 37 knees (54.4%) without patellar resurfacing. In the present study, no significant difference was found between the groups in terms of tilt, subluxation and their effect on clinical scores.

For total knee arthroplasty procedures, a patellar scoring system including evaluation criteria such as anterior knee pain, quadriceps muscle strenght, ability to rise from a chair and stair-climbing was used.<sup>[27,31,33,39,41,42,47,49,53]</sup> In a follow-up study of at least 10 years (range 10 to 13.4 years) for 28 knees treated with TKA without patellar resurfacing by Kim et al.<sup>[39]</sup> the mean patella score was 25.8; and the mean score for stair-climbing was 3.2 in six knees (21.4%) with anterior knee pain while it was 4.5 in 22 knees (78.6%) without anterior knee pain, providing a significant difference between them. In a study by Feller et al.<sup>[33]</sup> where 40 cases with osteoarthritis were equally divided into two groups of patellar resurfacing and non-resurfacing, undergoing TKA procedure with a follow-up period of three years, the mean patella score was 25.6 in the patellar resurfacing group, and 27.8 in the non-resurfacing group, and they reported that there was no significant difference between the groups, but the score for stair-climbing was lower in the patellar resurfacing group, presenting a significant difference. Our study with a mean patella score of 27.3 (24-30) in Group 1 and 26.2 (20-30) in Group 2, and absence of a significant difference between the groups based on the evaluations using a patellar scoring system is consistent with the literature.

Anterior knee pain resulting from several causes such as malpositioning of the components, implantation of femoral components larger than the required size, improper incision of the patellar bone has been reported in various rates.<sup>[19,20,35,40,46,49]</sup> In a prospective study on 118 knees of 86 cases with a diagnosis of osteoarthritis where 58 knees had TKA with patellar resurfacing and 60 without patellar resurfacing, with a mean follow-up period of 30 months (range 24 to 44 months), Barrack et al.<sup>[46]</sup> found that there was anterior knee pain in four knees (7%) with patellar resurfacing, and eight knees (13%) without patellar resurfacing, and there was no significant difference between the groups. Picetti et al.<sup>[20]</sup> performed TKA

on 100 knees of 84 cases without patellar resurfacing and followed them up for a mean period of 4.5 years (range 2 to 7 years), and found out that 29 knees had anterior knee pain, and 39 had difficulty in stair-climbing. In 85 TKA cases with patellar resurfacing and 77 without patellar resurfacing, Yücel,<sup>[49]</sup> reported that 21% of the cases in the non-resurfacing group were able to climb the stairs by aid or walking stick, and 4% were unable to climb the stairs while 17 of the cases in the patellar resurfacing group were able to climb the stairs with aid or walking stick, and 2% were unable to climb the stairs. In the present study, presence of postoperative anterior knee pain in eight knees (13.6%) in Group 1, and 14 knees (15.6%) in Group 2; problem with stair-climbing in nine knees (15.3%) in Group 1 and 13 knees (14.4%) in Group 2; and absence of a significant difference between the groups are consistent with the literature.

In conclusion, no difference was found between the clinical and radiographic results in cases with or without patellar resurfacing during TKA procedures in our study. When presence of problems such as anterior knee pain, polyethylene wearing, patellar fracture, component loosening, synovial compression, patellar clunk syndrome, osteonecrosis, separation of metal back in the metal-backed patellar prosthesis and impaired extensor mechanism and also challenges in the treatment are taken into consideration, we believe that patellar resurfacing is not necessary for patients other than the ones with significant degeneration of the patellar surface in total knee arthroplasty.

## References

1. Gunston FH, MacKenzie RI. Complications of polycentric knee arthroplasty. *Clin Orthop Relat Res* 1976;(120):11-7.
2. Ranawat CS. The patellofemoral joint in total condylar knee arthroplasty. Pros and cons based on five- to ten-year follow-up observations. *Clin Orthop Relat Res* 1986;(205):93-9.
3. Webster DA, Murray DG. Complications of variable axis total knee arthroplasty. *Clin Orthop Relat Res* 1985;(193):160-7.
4. Clayton ML, Thirupathi R. Patellar complications after total condylar arthroplasty. *Clin Orthop Relat Res* 1982;(170):152-5.
5. Insall JN, Binazzi R, Soudry M, Mestriner LA. Total knee arthroplasty. *Clin Orthop Relat Res* 1985;(192):13-22.
6. Insall J, Scott WN, Ranawat CS. The total condylar knee prosthesis. A report of two hundred and twenty cases. *J Bone Joint Surg [Am]* 1979;61:173-80.
7. Levai JP, McLeod HC, Freeman MA. Why not resurface the patella? *J Bone Joint Surg [Br]* 1983;65:448-51.
8. Soudry M, Mestriner LA, Binazzi R, Insall JN. Total knee arthroplasty without patellar resurfacing. *Clin Orthop Relat Res* 1986;(205):166-70.
9. Keblish PA, Varma AK, Greenwald AS. Patellar resurfacing or retention in total knee arthroplasty. A prospective study of patients with bilateral replacements. *J Bone Joint Surg [Br]* 1994;76:930-7.
10. Beight JL, Yao B, Hozack WJ, Hearn SL, Booth RE Jr. The patellar "clunk" syndrome after posterior stabilized total knee arthroplasty. *Clin Orthop Relat Res* 1994;(299):139-42.
11. Bindelglass DF, Cohen JL, Dorr LD. Patellar tilt and subluxation in total knee arthroplasty. Relationship to pain, fixation, and design. *Clin Orthop Relat Res* 1993;(286):103-9.
12. Briard JL, Hungerford DS. Patellofemoral instability in total knee arthroplasty. *J Arthroplasty* 1989;4 Suppl:S87-97.
13. Doolittle KH 2nd, Turner RH. Patellofemoral problems following total knee arthroplasty. *Orthop Rev* 1988;17:696-702.
14. Johnson DP, Eastwood DM. Patellar complications after knee arthroplasty. A prospective study of 56 cases using the Kinematic prosthesis. *Acta Orthop Scand* 1992;63:74-9.
15. Merkow RL, Soudry M, Insall JN. Patellar dislocation following total knee replacement. *J Bone Joint Surg [Am]* 1985;67:1321-7.
16. Mochizuki RM, Schurman DJ. Patellar complications following total knee arthroplasty. *J Bone Joint Surg [Am]* 1979;61:879-83.
17. Ritter MA, Herbst SA, Keating EM, Faris PM, Meding JB. Patellofemoral complications following total knee arthroplasty. Effect of a lateral release and sacrifice of the superior lateral geniculate artery. *J Arthroplasty* 1996;11:368-72.
18. Brick GW, Scott RD. The patellofemoral component of total knee arthroplasty. *Clin Orthop Relat Res* 1988;(231):163-78.
19. Levitsky KA, Harris WJ, McManus J, Scott RD. Total knee arthroplasty without patellar resurfacing. Clinical outcomes and long-term follow-up evaluation. *Clin Orthop Relat Res* 1993;(286):116-21.
20. Picetti GD 3rd, McGann WA, Welch RB. The patellofemoral joint after total knee arthroplasty without patellar resurfacing. *J Bone Joint Surg [Am]* 1990;72:1379-82.
21. Scott RD, Reilly DT. Pros and cons of patella resurfacing in total knee replacement. *Orthop Trans* 1980;4:328-9.
22. Outerbridge RE. The etiology of chondromalacia patellae. *J Bone Joint Surg [Br]* 1961;43:752-7.
23. Maquet P. Biomechanics of gonarthrosis. [Article in French] *Acta Orthop Belg* 1972;38 Suppl 1:33-54.
24. Insall J, Salvati E. Patella position in the normal knee joint. *Radiology* 1971;101:101-4.
25. Laurin CA, Dussault R, Levesque HP. The tangential x-ray investigation of the patellofemoral joint: x-ray technique, diagnostic criteria and their interpretation. *Clin Orthop Relat Res* 1979;(144):16-26.
26. Merchant AC, Mercer RL, Jacobsen RH, Cool CR. Roentgenographic analysis of patellofemoral congruence. *J Bone Joint Surg [Am]* 1974;56:1391-6.
27. Ewald FC. The Knee Society total knee arthroplasty roentgenographic evaluation and scoring system. *Clin Orthop Relat Res* 1989;(248):9-12.
28. Takahashi Y, Gustilo RB. Nonconstrained implants in revision total knee arthroplasty. *Clin Orthop Relat Res* 1994;(309):156-62.
29. Rand JA. Revision total knee arthroplasty for aseptic loosening. In: Lotke PA, editor. *Master techniques in orthopaedic surgery, knee arthroplasty*. New York: Raven Press; 1995. p.



- 195-217.
30. Scuderi GR, Mann JW. Cement fixation techniques for revision total knee arthroplasty. In: Lotke PA, Garino JP, editors. Revision total knee arthroplasty. Philadelphia: Lippincott-Raven; 1999. p. 304-5.
  31. Ahlback S. Osteoarthritis of the knee. A radiographic investigation. *Acta Radiol Diagn* 1968;Suppl 277:7-72.
  32. Insall JN, Dorr LD, Scott RD, Scott WN. Rationale of the Knee Society clinical rating system. *Clin Orthop Relat Res* 1989;(248):13-4.
  33. Feller JA, Bartlett RJ, Lang DM. Patellar resurfacing versus retention in total knee arthroplasty. *J Bone Joint Surg [Br]* 1996; 78:226-8.
  34. Boyd AD Jr, Ewald FC, Thomas WH, Poss R, Sledge CB. Long-term complications after total knee arthroplasty with or without resurfacing of the patella. *J Bone Joint Surg [Am]* 1993;75:674-81.
  35. Rae PJ, Noble J, Hodgkinson JP. Patellar resurfacing in total condylar knee arthroplasty. Technique and results. *J Arthroplasty* 1990;5:259-65.
  36. Abraham W, Buchanan JR, Daubert H, Greer RB 3rd, Keefer J. Should the patella be resurfaced in total knee arthroplasty? Efficacy of patellar resurfacing. *Clin Orthop Relat Res* 1988; (236):128-34.
  37. Smith SR, Stuart P, Pinder IM. Nonresurfaced patella in total knee arthroplasty. *J Arthroplasty* 1989;4 Suppl:S81-6.
  38. Figgie HE 3rd, Goldberg VM, Heiple KG, Moller HS 3rd, Gordon NH. The influence of tibial-patellofemoral location on function of the knee in patients with the posterior stabilized condylar knee prosthesis. *J Bone Joint Surg [Am]* 1986; 68:1035-40.
  39. Kim BS, Reitman RD, Schai PA, Scott RD. Selective patellar nonresurfacing in total knee arthroplasty. 10 year results. *Clin Orthop Relat Res* 1999;(367):81-8.
  40. Sen C, Akman S, Asik M, Sener N, Bilen E. Comparison of the results of total knee arthroplasty with and without patellar resurfacing. [Article in Turkish] *Acta Orthop Traumatol Turc* 2001;35:189-95.
  41. Gill GS, Joshi AB, Mills DM. Total condylar knee arthroplasty. 16- to 21-year results. *Clin Orthop Relat Res* 1999; (367):210-5.
  42. Ranawat CS, Flynn WF Jr, Saddler S, Hansraj KK, Maynard MJ. Long-term results of the total condylar knee arthroplasty. A 15-year survivorship study. *Clin Orthop Relat Res* 1993;(286):94-102.
  43. Stern SH, Insall JN. Total knee arthroplasty in obese patients. *J Bone Joint Surg [Am]* 1990;72:1400-4.
  44. Schurman JR, Borden LS, Wilde AH. Long term results of total condylar knee prosthesis. *Orthop Trans* 1987;11:443-7.
  45. Insall JN, Ranawat CS, Aglietti P, Shine J. A comparison of four models of total knee-replacement prostheses. 1976. *Clin Orthop Relat Res* 1999;(367):3-17.
  46. Barrack RL, Wolfe MW, Waldman DA, Milicic M, Bertot AJ, Myers L. Resurfacing of the patella in total knee arthroplasty. A prospective, randomized, double-blind study. *J Bone Joint Surg [Am]* 1997;79:1121-31.
  47. Tokgözoğlu MA. Total diz artroplastisinde patellar komplikasyonlar [Uzmanlık Tezi]. Ankara: Hacettepe Üniversitesi Tıp Fakültesi Ortopedi ve Travmatoloji Anabilim Dalı; 1990.
  48. Grace JN, Rand JA. Patellar instability after total knee arthroplasty. *Clin Orthop Relat Res* 1988;(237):184-9.
  49. Yücel M. Diz protezi uygulamalarında patellar yüzey değiştirme ve patellofemoral eklem sorunları. *Acta Orthop Traumatol Turc* 1995;29:405-8.
  50. Phillips AM, Goddard NJ, Tomlinson JE. Current techniques in total knee replacement: results of a national survey. *Ann R Coll Surg Engl* 1996;78:515-20.
  51. Jeffery RS, Morris RW, Denham RA. Coronal alignment after total knee replacement. *J Bone Joint Surg [Br]* 1991;73:709-14.
  52. Ritter MA, Faris PM, Keating EM, Meding JB. Postoperative alignment of total knee replacement. Its effect on survival. *Clin Orthop Relat Res* 1994;(299):153-6.
  53. Aglietti P, Buzzi R, Gaudenzi A. Patellofemoral functional results and complications with the posterior stabilized total condylar knee prosthesis. *J Arthroplasty* 1988;3:17-25.