



Osteometry of the femora in Turkish individuals: a morphometric study in 114 cadaveric femora as an anatomic basis of femoral component design

Türk toplumunda femur osteometrisi: Femoral komponent tasarımı için 114 kadavra femurunda morfometrik çalışma

Bulent ATILLA, Ali OZNUR, Omur CAGLAR, Mazhar TOKGOZOGLU, Mumtaz ALPASLAN

Hacettepe University Faculty of Medicine, Department of Orthopaedics and Traumatology

Amaç: Total kalça artroplastisi konusunda yapılan klinik ve deneysel çalışmalar uzun dönemde implant fiksasyonu için protez ve kemik arasında iyi bir geometrik uyum olması gerektiğini göstermiştir. Total kalça protezlerinin uzun dönemdeki başarısı için proksimal femur anatomisinin iyi bilinmesi ve kritik noktalarda ortalama değerlerinin tanımlanması gerekir. Literatürde protez boylarına ve implantasyonuna ait sayısal bilgiler Batı toplumlarına ait bireylerin femurlarının osteometrik çalışmalarına dayanmaktadır. Bu çalışmada Türk toplumunda femur osteometrisi incelendi ve gelecek çalışmalara veritabanı oluşturulması amaçlandı.

Çalışma planı: Bilinen gelişimsel bir kemik hastalığı olmayan 114 kadavra erişkin femurunda konvansiyonel radyografik yöntemlerle proksimal femur anatomisi ve açısal yapısı ile ilgili morfometrik ölçümler yapıldı. Ölçümler Noble ve ark. tarafından geliştirilmiş yöntemlere göre yapıldı. Karşılaştırma için, Noble ve ark.nın Batı toplumu için bildirdikleri morfometrik veriler kullanıldı.

Sonuçlar: Türk toplumundaki bireylerin femurlarında bazı özelliklerin farklı olduğu görüldü. Baş büyüklüğü ve offseti karşılaştırılan verilerle benzer olmakla beraber, baş-boyun açısındaki valgus pozisyonuna bağlı olarak Türklerde femur başı daha yüksek yerleşimli bulundu. Proksimal femoral metafiz daha dar idi. Distalde, istmik segmentin daha dar ve daha uzun olduğu dikkat çekti.

Çıkarımlar: Türk toplumunda femoral geometri Batı toplumlarına ait değerlerden farklılık göstermektedir. Total kalça protezi tasarımı ve uygulamasında bu özelliklerin dikkate alınması gerektiği kanısındayız.

Anahtar sözcükler: Antropometri; kadavra; femur/anatomi ve histoloji/radyografi; kalça protezi; protez tasarımı; referans değeri; Türkiye.

Objectives: Clinical and experimental studies of total hip arthroplasty have demonstrated that a close geometric fit between the femoral component and supporting bone is essential for durable implant fixation. Long-term success of total hip prostheses depends on appreciation of the proximal femur anatomy and identification of mean reference values of critical landmarks. Current data on dimensions of prostheses and implantation are based on osteometric measurements of the femora in Western populations. This study was designed to evaluate osteometric features of femora in Turkish individuals and to establish a national database for future studies.

Methods: We conducted morphometric measurements of proximal femoral anatomy and its angular configuration on conventional radiograms of 114 cadaveric adult femora of Turkish individuals who did not have any developmental bone abnormality. Measurements were made according to the parameters defined by Noble et al. For comparison, we used morphometric data reported on Western populations by the same investigators.

Results: Several femoral features were found to be different in Turkish individuals. Although femur head size and offset were similar to Western values, Turkish subjects had a higher femoral head due to valgus position of the femoral head-neck angle, a narrower proximal femoral metaphysis, and a narrower medullary canal with a longer isthmic segment.

Conclusion: Our data revealed diverse features of femoral geometry in Turkish individuals compared to Western populations. These differences should be taken into account in the design and development of hip prostheses.

Key words: Anthropometry; cadaver; femur/anatomy & histology/radiography; hip prosthesis; prosthesis design; reference values; Turkey.

Anthropology clearly states racial and morphologic differences between Middle-Eastern and Caucasians.[1,2] Variations of the upper femoral morphology between racial groups may be significant enough to require modifications in total hip prosthesis design. Current data regarding the correct sizing of a prosthesis and technical guides to insertion are largely based on osteometric measurements in Caucasians.[3,4] It is not known whether such measurements are directly applicable to the hips of non-Caucasians, and whether there are any morphometric differences between the Middle-Eastern and the Caucasian hips.

The present study examined the morphology of Turkish femurs using measurements from conventional radiography and determined similarities and differences between the Turkish and Caucasian femurs, providing a database for further work.

Materials and methods

The femurs of 114 Turkish adult skeleton were studied with conventional radiography to provide data on their dimensions and angular alignment. Obtained data were compared with published reports on Caucasian femurs to determine similarities and differences. Femora without evidence of osseous pathology were obtained from skeletons donated to the anatomy laboratories of Medical Faculty. Each femur was labeled for identification. Data on the age and the sex of the donor population was incomplete, however each femur belong to an adult person.

Roentgenograms of each specimen were prepared by fitting the femora into polyurethane blocks that provided views parallel and perpendicular to the plane of the femoral neck at 1m tube-to-film distance. A roentgenographic scale allowed compensation for magnification, which was typically 3%.

To enable reliable measurement of dimensions of bone, standard periosteal (extracortical) and endosteal (intracortical) reference lines were determined at certain levels. Distance of different reference lines were measured according to the method described by Noble et al.^[4] (Fig. 1).

Mean and standard deviations were measured for each dimension of the femurs. Noble's data was accepted to represent Caucasians. One-sample t-test is used to test the significance of the difference

between two populations. An absolute t value greater than 1.96 implied a significant difference.

The bones were also grouped by the shape of the proximal femur using 'the canal/flare index'. The canal/flare index defined as the ratio of the intracortical width of the femur at a point 20mm proximal to the lesser trochanter and width at the canal isthmus. The femurs then subjectively characterized as 'normal' (indices between 3.0-4.7), 'stove pipe' (relatively straight sided due to canal flare indices less than 3.0), or 'champagne-fluted' (highly tapered proximal segment with indices between 4.7-6.5).

Coefficients of reliability of the measurements were determined on replicate procedures made by 2 months apart by two contributing authors. Intraclass correlation coefficients (r_r) are used to evaluate the interobserver reliability for the entire series. They were $r_r = 0.84$ for the anteroposterior measurements, $r_r = 0.98$ for lateral roentgenogram measurements and, $r_r = 0.83$ for angle measurements.

Results

Average dimensions for all the femora examined in our series and variables characterizing the femoral specimens in Noble et. al.'s study were presented in Table 1

Distribution of canal flare indices between both groups were compared in Figure 2.

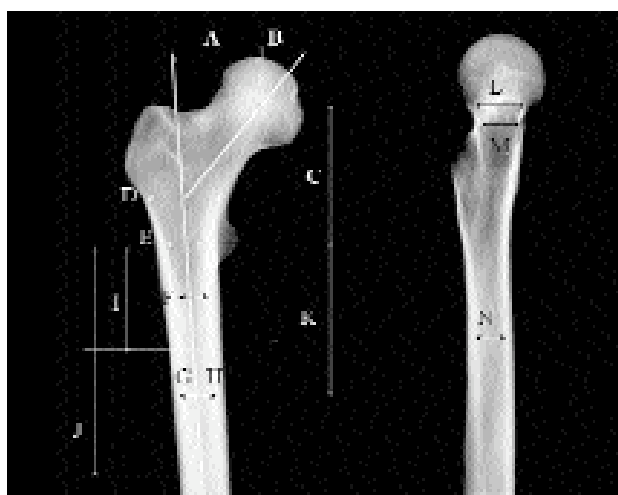


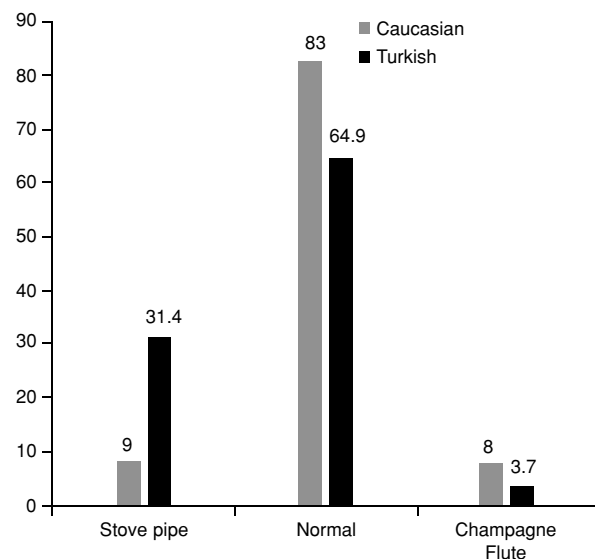
Figure 1. Standard reference lines to measure femoral dimensions in anteroposterior and lateral roentgenograms. See Table 1 for a legend describing each lettered dimension.

Table 1. Variables Characterizing the Femoral Specimens

Dimension	No	Average±St. Dev.	Min-Max	Noble et al.
(A) Femoral head offset (mm)	114	42.7±6.54	27–65	43.0±6.8
(B) Femoral head diameter (mm)	114	45.8±4.17	37–55	46.1±4.8
(C) Femoral head position (mm)	114	59.1±7.74	42–80	51.6±7.1
(D) Canal width (lesser trochanter +20mm)	114	33.4±5.43	22–46	45.4±5.3
(E) Canal width (mm)	114	22.6±3.58	13–32	29.4±4.6
(F) Canal width (lesser trochanter –20mm)	114	16.9±5.1	9–61	20.9±3.5
(G) Isthmus width (AP projection) (mm)	108	10.7±1.84	7–17	12.3±2.3
(H) Extracortical width at isthmus level (AP projection) (mm)	113	27.3±3.38	21–36	27.0±3.1
(I) Proximal border of isthmus	108	66.7±18	27–113	86.1±17.8
(J) Distal border of isthmus(mm)	107	151.5±23.91	78–200	145±19.4
(K) (K) Isthmus position (mm)	109	104.0±27.9	11–197	113.4±16.4
(L) AP canal width (osteotomy level)(mm)	113	23.2±4.22	13–35	24.1±3.1
(M) Medial diameter of femoral neck(mm)	113	19.9±4.21	10–35	16.5±2.9
(N) Isthmus width (LAT projection)	108	13.7±2.48	9–25	16.9±3.5
(α) Neck-shaft angle (°)	114	128.4±4.75	116–145	124.7±7.4

Comparison of Turkish femurs with Caucasians' revealed both differences and similarities. Head diameter (A) and femoral head offset (B) were approximately the same in each group ($t=0.16$ and $t=0.8$ respectively). However, femoral head location (C) was higher in Turks ($t=7.74$), due to an increase in neck/shaft angle ($t=8.54$); demonstrating valgus position of the femoral head.

Despite the similarity of the outer cortical diameters (H), of both populations at the isthmus level

**Figure 2.** Distribution of canal flare indices compared with these obtained by Noble et al.

($t=0$), inner diameter of Turkish isthmus is relatively narrow both in the anteroposterior (G) and lateral (N) projections, ($t=7.5$ and 16.8 respectively). This is a fact of thicker cortex. Depth of isthmus from the lesser trochanter was more proximal in Turkish femurs and, 'isthmus segment', (i.e., cranial and caudal extensions of the narrowest diaphyseal segment in 1mm tolerance) is markedly longer (J-I). (Fig.3).

Discussion

The availability of basic geometric data describing the proximal femur allows assessment of the match between the shape of existing components and the proximal femur and allows guidelines to the development of a new prosthetic design. Previous studies investigating the morphometry of the hip varied in the technique used and populations studied.^[4,5,6] Some studies have used direct measurements from cadaveric hips, whereas others have used measurements from computed tomography (CT) scans.^[7] However, in these studies there was either no separation into the different racial groups or the measurements were based on hips of Caucasians. However, medical literature revealed evidence of distinct morphometric features in different racial groups.^[7,8]

Location of the femoral head in vertical and frontal planes are important for restoration of the original center of hip rotation and they determine the

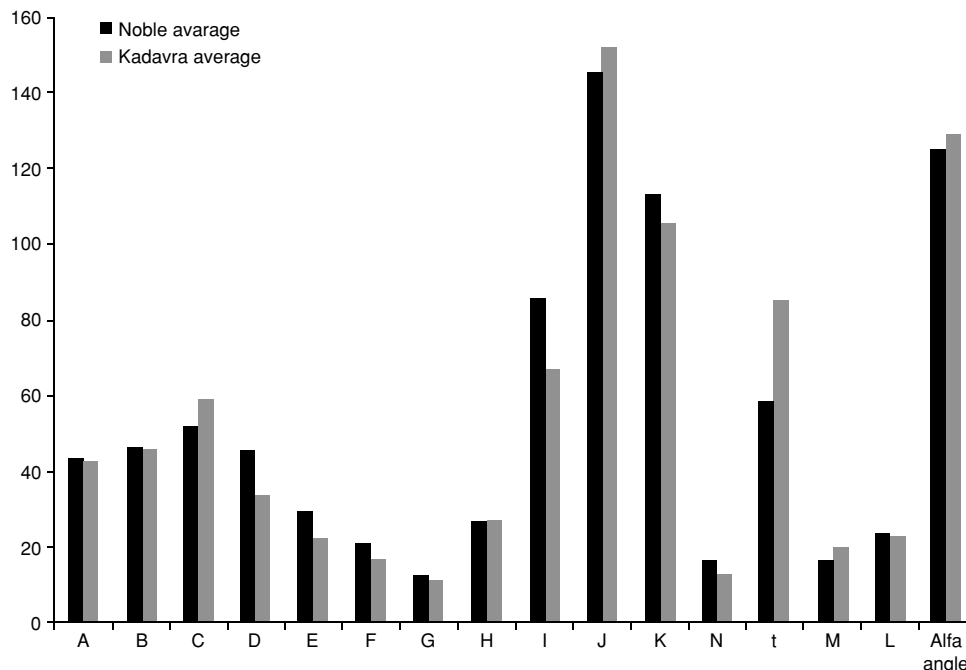


Figure 3. While head diameter (A) and, femoral head offset (B) were approximately the same in both populations, femoral head is located (C) higher in Turks. (t: isthmic segment)

stability of the reconstructed joint. Restoration of the original position of the center of the femoral head ensures maintenance of leg length and re-establishment of the original balance of the abductor and joint reaction forces.

Contact between the femoral stem and the proximal metaphysis has been shown to control micromotion and subsidence of the femoral component.^[5] In that aspect, statistical correlation between individual dimensions of the femur may be used to describe the proximal shape, independent of its size. The canal flare index expressing the overall shape of the proximal femoral metaphysis in the coronal plane identifies three different shapes. According to our investigation, proximal femoral metaphysis in Turks demonstrates marked narrowing. The mean values of the canal flare index were very similar in two studies based on Caucasian femurs and each of stove pipe femurs and champagne flute femurs were represented in approximately 10%.^[4] Whereas the stovepipe femurs are seen quite common (31.4%) and the champagne flute femurs are evidently rare (3.7%) in the Turkish population, as demonstrated in Figure 2.

Distance of isthmus to cut surface and its diameter are of particular importance in cemented hip replacements realized by modern cementing tech-

niques. These features determine the level and size of intramedullary plugs, hence the optimal length and distal diameter of a femoral component design. Cemented stems that are too short are subject to unusual rates of loosening.^[5] Whereas stems that are too long can cause displacement of the cement plug into distal flare of the medullary canal. Despite the fact that the outer cortical diameters (H), of both populations are very similar at the isthmic level ($t=0$), Turkish isthmus is relatively narrow in the intramedullary aspect both in anteroposterior (G) and lateral (N) projections, ($t=7.5$ and 16.8 respectively). Isthmus was located more proximal in Turkish femurs and, 'isthmic segment' (t), (i.e., cranial and caudal extensions of the narrowest diaphyseal segment in 1mm tolerance), begins proximally and it is markedly longer compared to the Caucasians.

A possible drawback to our method of study is the accuracy of direct measurements from skeletons as their dimensions may change during the drying process. This may have an impact on numeric data based on distance measurements. However, the authors believe that this negligible for dimensional analysis (i.e., proportions of the measurements rather than the numeric data itself), and angular measurements.

Some authors stated that a bidimensional study is limited due to the weakness of standard radiographs for a reliable morphometric analysis due to rotational imprecise positioning. Correct positioning of the femur of a patient is difficult in practice because of pain or contracture, and small variations in leg rotation significantly alter the analyzed parameters^[9,10] In our study, femoral specimens provided accurate positioning.

In conclusion this study demonstrates marked differences in proximal morphology of the femurs of Middle-Eastern and Caucasians. A typical Turkish femur possesses a head in more valgus position, a straight and compressed proximal segment. More distally, narrower and longer isthmus segment differentiates Turkish femurs from its Caucasian counterparts. We believe that, such differences need to be considered when a total hip prosthesis is designed.

References

1. Birdsell JB. Human evolution: an introduction to the new physical anthropology. Chicago: Rand-McNally; 1972.
2. Ferembach D. Formation et évolution de la brachycéphalie au Proche-Orient. *Homo* 1966;17:160-72.
3. Rubin PJ, Leyvraz PF, Aubaniac JM, Argenson JN, Esteve P, de Roguin B. The morphology of the proximal femur. A three-dimensional radiographic analysis. *J Bone Joint Surg [Br]* 1992;74:28-32.
4. Noble PC, Alexander JW, Lindahl LJ, Yew DT, Granberry WM, Tullos HS. The anatomic basis of femoral component design. *Clin Orthop Relat Res* 1988;(235):148-65.
5. Crowninshield RD, Brand RA, Johnston RC, Milroy JC. An analysis of femoral component stem design in total hip arthroplasty. *J Bone Joint Surg [Am]* 1980;62:68-78.
6. Skirving AP. The centre-edge angle of Wiberg in adult Africans and Caucasians. A radiographic comparison. *J Bone Joint Surg [Br]* 1981;63:567-8.
7. Fang D, Cheung KM, Ruan D, Chan FL. Computed tomographic osteometry of the Asian lumbar spine. *J Spinal Disord* 1994;7:307-16.
8. Takaoka K, Sakamaki T, Yanagimoto S, Matsumoto T, Sugano N, Saito S, et al. The Asian hip. In: Callaghan JJ, Rosenberg AG, Rubash HE, editors. *The adult hip*. Philadelphia: Lippincott Raven; 1998. p. 1105-24.
9. Iguchi H, Hua J, Walker PS. Accuracy of using radiographs for custom hip stem design. *J Arthroplasty* 1996;11:312-21.
10. Kelley SS, Fitzgerald RH Jr, Rand JA, Ilstrup DM. A prospective randomized study of a collar versus a collarless femoral prosthesis. *Clin Orthop Relat Res* 1993;(294):114-22.