



# Closed reduction in the treatment of developmental dysplasia of the hip

## *Gelişimsel kalça displazisi tedavisinde kapalı redüksiyon*

**M. Cemalettin AKSOY**

*Hacettepe University Faculty of Medicine Department of Orthopaedics and Traumatology*

*Gelişimsel kalça displazisinde kapalı redüksiyon ve alçı immobilizasyonu hastalığın tedavisinde kullanılan standart yöntemlerden biridir. Bu tedavi, yürüme çağı öncesinde, genel anestezi altında ve artrografik kontrollü olarak uygulanmaktadır. İşlem sırasında zorlamalı redüksiyonlardan kaçınılması, aşırı pozisyonlarda kalçanın immobilize edilmemesi büyük önem taşımaktadır. İşlemin geç dönemde sonucunu etkileyen en temel parametre, femur başında meydana gelen avasküler nekrozdur (AVN). Avasküler nekrozdan kaçınmak için değiştirilebilir tüm faktörlerin hasta lehinde değişimi sağlanmalıdır. Günümüzde deneyimli çocuk ortopedistleri tarafından uygulandığında, düşük oranda AVN ile tatminkar sonuç veren bir yöntem olarak görülmektedir.*

*One of the standard treatment methods for developmental dysplasia of the hip is closed reduction followed by immobilization in a hip spica cast. This treatment is performed before achievement of independent walking, under general anesthesia and with arthrographic control. Avoidance of forced reductions and immobilization of the hip with extreme positions is of utmost importance during the procedure. Development of avascular necrosis (AVN) of the femur head is the main parameter affecting the late outcome of the procedure. All modifiable factors should be influenced in favor of the patient to avoid AVN. This method appears to be satisfying with acceptable rates of AVN when applied by experienced pediatric orthopedic surgeons.*

Regardless of patient's age, the goal is same in the treatment of Developmental Dysplasia of the Hip (DDH). This objective is primarily to provide anatomic and stable reduction, maintenance of the achieved reduction and capturing the normal developmental course of hip. The most essential target of this short term objective should be achieving a long-lasting, preferably life time stable, fully functioned and pain free hip. While treating with this goal, physician should choose the optimum method for his/her patient among several methods. Today, treatment algorithms have been formed to decrease the complexity in DDH treatment. Despite being used more limitedly in these algorithms today than it was used in the past, closed reduction is one of the most indispensable methods of DDH treatment. In this article, description, efficiency and possible compli-

cations and problems of closed reduction as a method will be reviewed.

### **Description and method**

Closed reduction under general anaesthesia in DDH treatment can be defined as spica cast application to provide reduction of dislocated or subluxated hip or to maintain the achieved reduction. Currently, this method is an approach preferred in 12 months old or younger patients. Other methods are generally preferred in patients over 1 year old not to increase complication rates. The first method to be preferred among 0-4<sup>[6]</sup> month old patients should be Pavlik harness. Closed reduction is preferred in patients of this age group when treatment is a failure with Pavlik harness or bandage is not applicable due to family incomppliance, social reasons etc. The

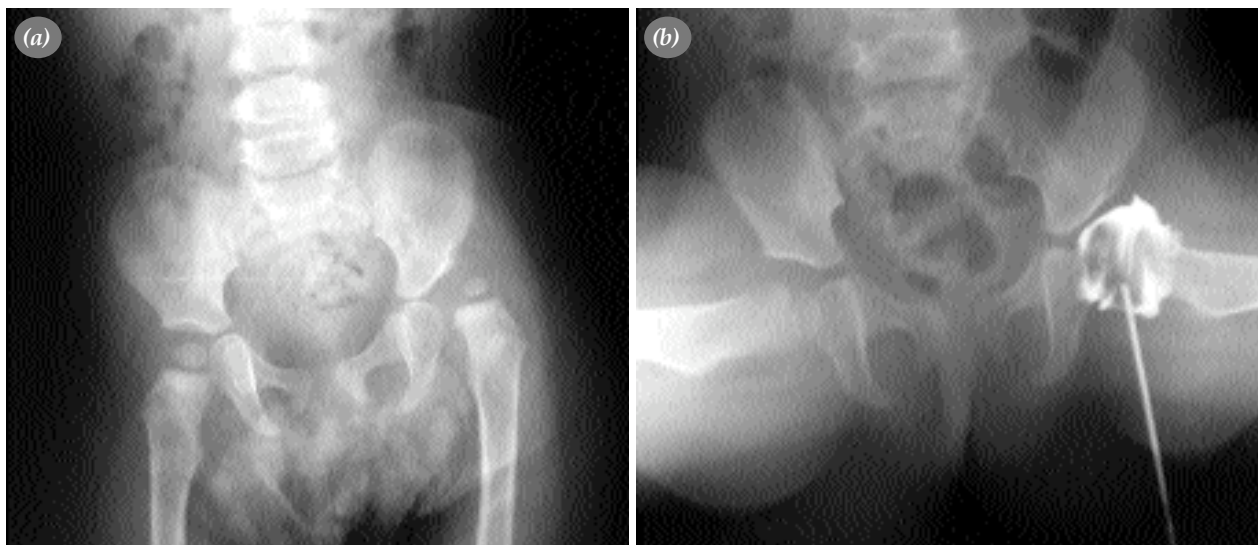author chooses closed reduction before walking period in his own application. While Pavlik harness is used as first method in patients diagnosed before six months old, closed reduction or plaster cast immobilization is used as standard method in patients when Pavlik harness is not successful or bandage cannot be used due to different reasons.

Traction before closed reduction (skin or skeleton, home or hospital) is one of the methods applied for years to provide a higher rate of treatment with closed reduction and to decrease avascular necrosis (AVN) rates.<sup>[1,2,3]</sup> However, today traction before reduction is a rarely preferred method. The basic reason of this situation is that the effects of traction application on particularly avascular necrosis rates could not be shown positively in terms of science.<sup>[4,5]</sup> Also, in the research conducted by Paediatric Orthopaedic Society of North America- POSNA, it was found out that only 5% of members used traction before reduction.<sup>[6]</sup> Besides, although traction method has been used as standard treatment method in author's clinic for years, it was seen that there was no significant difference between results of these patients and patients on whom traction was not applied in terms of avascular necrosis rates.<sup>[7]</sup> Thus, the author does not apply traction before reduction in his applications.

Closed reduction is carried in the operating room under general anaesthesia. Reduction should be tried without any force applied. It is generally achieved in

flexion or abduction position of the hip. Therefore, arthrography is required to determine the reduction quality. It is also possible to determine the situations preventing reduction. The acceptable way of arthrography controlled reduction is anatomic reduction (Fig. IA and IB). The hip's safe zone (adduction-abduction motion range in which reduction can be maintained) should be determined. In case this range is narrow, it should be widened by open or closed adductor tenotomy. This procedure is also needed to decrease the frequency of AVN.

One of the most important decisions that a surgeon applying closed reduction should make is to determine the power to be applied for reduction. Surgeon should not need more force to maintain this after providing reduction. Also, excess positions should not be required for maintenance of reduction. It should be maintained in human position. This is hyperflexion and restricted abduction. In his clinical application, the author gives at least 90 degrees flexion position to the hip and avoids abduction position more than 45-50 degrees. If inner rotation movement in addition to excess abduction is needed to maintain reduction, this is a message indicating that closed method is not suitable for the patient and excess abduction and inner rotation must definitely be avoided. Second basic point is the quality of reduction. Acceptable reduction is arthrography controlled anatomic reduction. The surgeon should not hesitate about this.



**Figure 1** (a) Posterior-anterior pelvic graph of a 7 month-old baby girl with left hip dislocation. (b) Concentric reduction view of the same patient in human position after arthrography.

After reduction is provided anatomically and within acceptable limits and this situation is arthrographically shown, spica cast should be applied for the maintenance of reduction. The authors prefers that plaster cast is extended to both ankles in babies. The most important advantage of standard plaster casts is their shapeability. However synthetic plaster casts are more durable, light and allow better imaging in radiological control after plaster cast. Also application is facilitated. Although the author prefers synthetic materials, it is best for the surgeon to use the most familiar method. (Fig. II). Basic point while plaster cast is applied is that hip is taken to the requested position and this position is not changed during casting. Abduction amount is often increased with the concern of exhaustion and reduction loss during the procedure. Surgeon should be careful about this. Other basic point is shaping the plaster cast. Plaster cast should be shaped well particularly in gluteal region to prevent reduction losses. Radiological reduction control should definitely be made after casting procedure is finished. In suspected situations and if image of enough quality cannot be achieved due to the cast, computerized tomography (CT) or magnetic resonance imaging (MRI) to check reduction quality.<sup>[9,10]</sup>

Immobilization period within the cast is not standard. Differences can be seen between clinics and surgeons. Applications of various surgeons are mentioned in classic paediatric orthopaedic books without giving certain periods.<sup>[11]</sup> General application is immobilization of patient with plaster cast for 3 months. Patient and the cast should be checked in the 6th week of application. The fact that reduction continues should be mentioned in control visits. Cast should be replaced if it is destroyed. This replacement should preferably be done in OR conditions. It is not possible to talk about standard applications after cast is taken away.<sup>[11]</sup> Some surgeons prefer to use the device until hip is totally back to normal while others use abduction device for a certain period. Author usually makes the follow-up of patients with abduction device for 2-3 months after 3 months of immobilization. Abduction device should firstly be used in a full time manner which is 22-23 hours a day followed by 10-12 hours a day (e.g; 6 weeks full time and 6 weeks partially). Excess positions should certainly be avoided while the device is applied to

patients. Scientific efficiency of this device application is not clear and traditionally applied in many clinics.

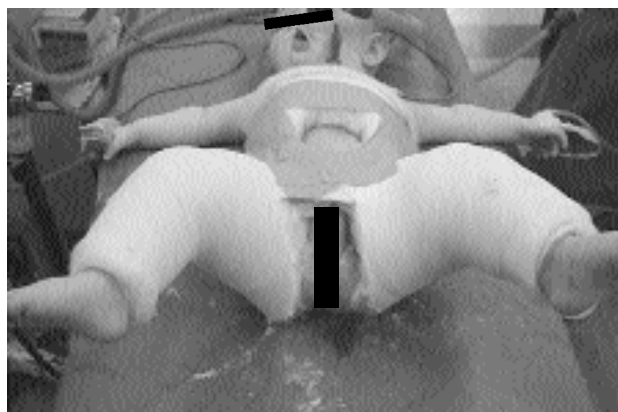
## Complications

Complications after closed reduction in DDH treatment can be divided into two sub-groups. These are early and late complications. Early complications belong to cast and arthrography. Detailed information about these can be found in many orthopaedic books. Growth disturbance of proximal femur that appears basically in late period and AVN are the most important complications of the procedure that affect the hip. This situation is defined as proximal femoral growth disturbance by some authors.<sup>[12]</sup>

The most utilized of AVN findings is defined by Salter et al.<sup>[8]</sup> These are;

1. Non-appearance of ossific nucleus of femoral head 1 year after reduction,
2. Lack of growth in ossific nucleus of femoral head within 1 year after reduction
3. thickening in femoral neck within 1 year after reduction
4. Increased density of femoral head and fragmentation of femoral head
5. deformity in femoral head and neck after completion of femoral head reossification: coxa magna, coxa plana, coxa vara, short and thick femur neck.

There is no ideal classification for made for AVN. Although, there is no definition at present

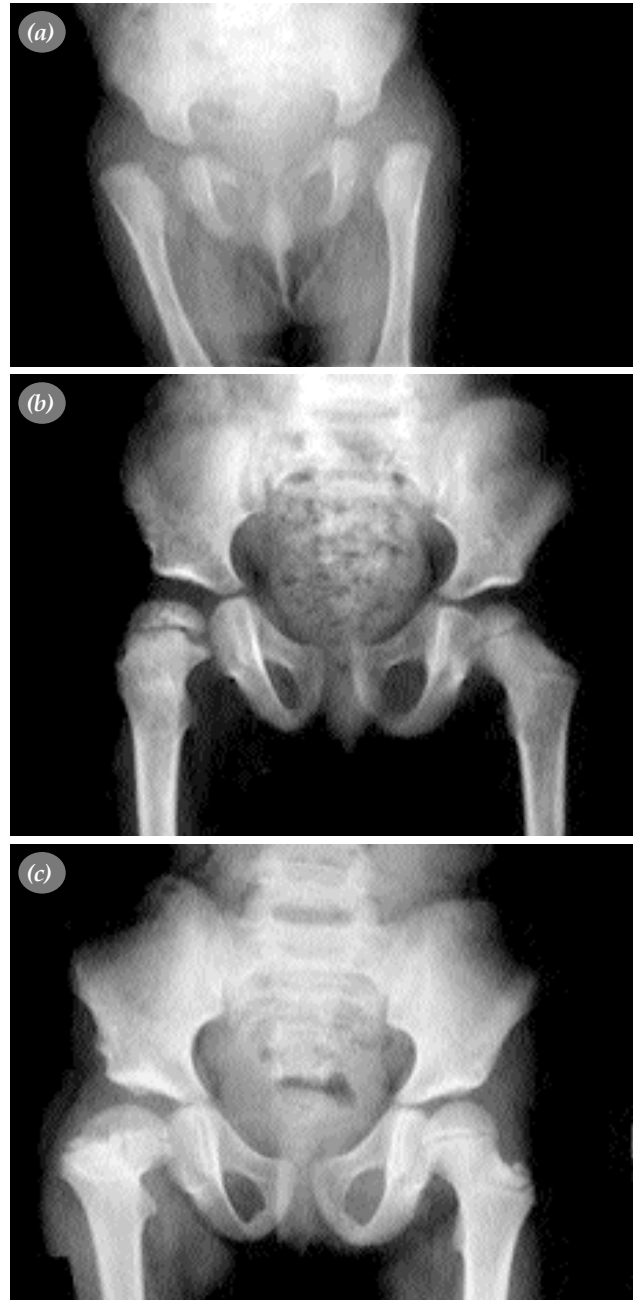


**Figure 2.** Synthetic plaster cast immobilization after closed reduction.

which is accepted by researchers and completely defines the deformities that occur, Burcholz and Ogden, Kalamchi and Mac Ewen classifications are frequently used. Classifications have similar features and define 4 types of AVN.<sup>[13]</sup> In both classifications, temporary fragmentation and delay in appearance of ossific nucleus, lateral epiphyseal damage, medial epiphyseal damage and complete head invasion are basic parameters (Fig IIIA, B, C)

Many factors are held responsible about AVN in literature. However it is not possible to define a certain reason. Femoral head AVN does not occur in untreated hips. Therefore, there is no doubt that it is an iatrogenic complication. Circulation disorder, pressure necrosis are the most accused reasons.<sup>[11]</sup> Traction application, age at the time of reduction, power applied for reduction, immobilization position, appearance of femoral head ossific nucleus, position of femoral head are topics discussed in literature.<sup>[11]</sup> Some of these factors cannot be changed by the treating surgeon. However it is possible to decrease the complication rate by changing some of these. It is not possible to talk about a certain rate in literature. Usually different rates are mentioned by assessing various features in heterogeneous series. Rates between 0-73 percent reported from various articles are given in classical books.<sup>[11]</sup> Aksoy et al reported 15 % AVN after closed reduction. Type I AVN is determined in 7% of these patients (temporary fragmentation or delay in occurrence of ossific nucleus). According to this, AVN rate with the possibility to create a problem in long term seems to be 8%.<sup>[7]</sup> The most important factor that affects long term result in this study is determined as AVN. Also, patient's age and acetabular index before reduction are determined as factors statistically related to AVN.<sup>[7]</sup> The highness of acetabular index and performing the treatment in late period increase the risk of AVN. In this study, satisfactory results were achieved in more than 80% of patients.<sup>[7]</sup> However study results are not homogenous in the literature as mentioned and every study brings different factors.

Common compromising point of all studies is that the basic factor that affects prognosis in DDH treatment is AVN. Therefore, decreasing AVN frequency should be the most basic approach in patients treated with closed reduction. In this case surgeon can be changed and situation that is certain-



**Figure 3.** (a) Pelvis anterior posterior graph of a 6 month old patient with bilateral hip dislocation. (b) Image of the same patient in which reduction continued acetabulum development is well however femoral head development is compatible with AVN, during follow up after closed reduction (c) Deformation in AVN related head in right hip despite good development in left hip, thickness and shortness in right hip femoral head.

ly related to AVN should be changed in a positive way. These are; performing the procedure under general anaesthesia with suitable looseness of muscle, performing reduction without force, anatomic

reduction and confirmation of this during and tabaif needed after the procedure, avoidance of extreme positions and not insisting on closed reduction when necessary.

### **Situations that require attention in closed reduction procedure and afterwards**

Closed reduction is a method applied frequently during DDH treatment and generally seen as a simple procedure. However, considering patient's age and situation that may be caused by possible complication in the future, it is clear that closed reduction is a much more important intervention than many orthopaedic procedures. Therefore, procedure must be done under maximum attention and necessary time should be spent. Following situation define frequently made mistakes that increase complication rates.

1- The family should be adequately informed when closed reduction is decided for patient. Surgeon should have declared to the family that open reduction might be performed in necessary. Inadequate notification of the family is a factor that causes surgeon to insist on closed method.

2- Procedure should preferably be applied as prioritized case of the day in early hours and assuming that open surgery is needed while making OR plan of the day, saving enough time and making bed reservation to hospitalize the patient if needed. If preparation for open reduction is not made, is there is no bed for patient after operation, these factors increase surgeon's insisting on closed reduction and calls for acceptance of inadequate reductions and immobilization in extreme positions and complications. Risk of surgeon's insisting on closed reduction increases due to surgeon's exhaustion and in patience if procedure is made in the last hours of the day. Closed reduction procedure should not be seen as the resting case of surgeon and his/her team between two long interventions. This situation is one of the most basic mistakes that create inattentive procedure and complication risk.

3- Cleaning conditions should be cared in a maximum level during arthrography procedure and infection risk of the joint should be decreased to a minimum level.

4- Surgeon should avoid continuous increase of abduction with the concern of exhaustion and reduction loss during casting. Patient position should frequently be checked. There should be no hesitation about plaster replacement if bad positioning is determined after plaster cast application.

5. The procedure should certainly be done by an experienced surgeon on paediatric orthopaedics or under his/her supervision.

6. Surgeon should certainly check the patients and plaster cast after they wake up. Neurovascular status of lower extremities should be evaluated. Also, it must be determined that plaster does not apply any pressure on the chest of baby and abdomen space is adequate. Genital zone must be adequately opened to provide the care of baby and must be checked by surgeon.

7. Family should be informed in details about the plaster care and possible complications and people and place to be applied in case of a problem should be determined.

### **Conclusion**

Closed reduction is a treatment method applied in eligible patients with satisfactory results for years in DDH treatment. The procedure gives good results in satisfactory rates and low complication rates when applied by experienced orthopaedic surgeons. Currently, arthrography controlled closed reduction and cast immobilization in human position by avoiding excess positions before walking period under general anaesthesia still remains as an acceptable standard method. It should be remembered that in DDH treatment, time helps re-shaping only in hips without AVN and with provision of stable reduction; otherwise time has no healing effect.

### **References**

1. Gogus MT, Aksoy MC, Atay OA, Acaroglu RE, Surat A. Treatment of congenital dislocation of the hip. Results of closed reduction and immobilization in the hip spica cast. *Turk J Pediatr* 1997;39:499-503.
2. Weiner DS, Hoyt WA Jr, O'dell HW. Congenital dislocation of the hip. The relationship of premanipulation traction and age to avascular necrosis of the femoral head. *J Bone Joint Surg [Am]* 1977;59:306-11.
3. Gage JR, Winter RB. Avascular necrosis of the capital femoral epiphysis as a complication of closed reduction of congenital dislocation of the hip. A critical review of twenty years' experience at Gillette Children's Hospital. *J Bone Joint Surg [Am]* 1972;54:373-88.



4. Weinstein SL. Traction in developmental dislocation of the hip. Is its use justified? *Clin Orthop Relat Res* 1997; (338):79-85.
5. Kutlu A, Ayata C, Ogun TC, Kapicioglu MI, Mutlu M. Preliminary traction as a single determinant of avascular necrosis in developmental dislocation of the hip. *J Pediatr Orthop* 2000;20:579-84.
6. Fish DN, Herzenberg JE, Hensinger RN. Current practice in use of prereduction traction for congenital dislocation of the hip. *J Pediatr Orthop* 1991;11:149-53.
7. Aksoy MC, Ozkoc G, Alanay A, Yazici M, Ozdemir N, Surat A. Treatment of developmental dysplasia of the hip before walking: results of closed reduction and immobilization in hip spica cast. *Turk J Pediatr* 2002;44:122-7.
8. Salter RB, Kostuik J, Dallas S. Avascular necrosis of the femoral head as a complication of treatment for congenital dislocation of the hip in young children: a clinical and experimental investigation. *Can J Surg* 1969;12:44-61.
9. McNally EG, Tasker A, Benson MK. MRI after operative reduction for developmental dysplasia of the hip. *J Bone Joint Surg [Br]* 1997;79:724-6.
10. Hernandez RJ. Concentric reduction of the dislocated hip. Computed-tomographic evaluation. *Radiology* 1984;150: 266-8.
11. Weinstein SL. Developmental hip dysplasia and dislocation. In: Morrissy RT, Weinstein SL, editors. *Lovell and Winter's pediatric orthopaedics*. Philadelphia: Lippincott Williams & Wilkins; 2006. p. 987-1037.
12. Malvitz TA, Weinstein SL. Closed reduction for congenital dysplasia of the hip: functional and radiographic results after an average of thirty years. *J Bone Joint Surg [Am]* 1994; 76:1777-92.
13. Tachdjian MO. Congenital dysplasia of the hip. In: Tachdjian MO, editor. *Pediatric orthopaedics*. Philadelphia: W. B. Saunders; 1990. p. 247-549.