



## Use of vacuum-assisted closure in the topical treatment of surgical site infections

### *Cerrahi alanda gelişen enfeksiyonların tedavisinde vakum yardımcı örtüm sistemi uygulamalarımız*

Ayhan KILIC, Ufuk OZKAYA, Sami SOKUCU, Seckin BASILGAN, Yavuz KABUKCUOGLU

*Taksim Education and Training Hospital Orthopaedics and Traumatology Department*

**Amaç:** Cerrahi alanda gelişen enfeksiyonun bölgesel tedavisinde vakum yardımcı örtüm sistemi ile elde ettiğimiz sonuçlar değerlendirildi.

**Çalışma planı:** Cerrahi alanda gelişen enfeksiyon nedeniyle 17 hastaya (10 erkek, 7 kadın; ort. yaş  $60\pm 20$ ) VAC sistemi (Vacuum-Assisted Closure, Kinetic Concept Inc.) ile vakum yardımcı yara örtme tedavisi uygulandı. Enfeksiyonlu yaraların altısı kalça, beşi krus, üçü diz, ikisi sakrum ve biri el bölgesindeydi. On beş hastada (%88.2) enfeksiyon etkeni olarak gram-pozitif bakteri saptandı. Altı hastada (%35.3) enfeksiyon hastane kökenliydi. Yaralara, ilk iki gün sürekli, sonraki günlerde ise aralıklı olarak 100-125 mmHg negatif basınç uygulandı. Hastalar ortalama  $11\pm 6$  ay takip edildi.

**Sonuçlar:** Vakum tedavisinin uygulama süresi ortalama  $16\pm 4$  gün, hastanede yatış süresi  $31\pm 19$  gün idi. Hastalara vakum tedavisi öncesinde ortalama üç cerrahi girişim (dağılım 1-6) yapıldı. Yaradan gelen akıntı miktarı  $500\pm 150$  ml ölçüldü. Yaraların tümünde doku ödemi ve akıntı sorunu çözüldü. Temiz ve kuru görünümlü bir cerrahi yara sahası elde edildi. On bir hastada (%64.7) cerrahi bölgesindeki enfeksiyon, uygun antibiyotik kullanımı ve vakum tedavisi ile klinik ve bakteriyolojik olarak tedavi edildi. Hastane nedenli enfeksiyonları olan altı hastada ise yara sorunlarının çözümünü takiben yara kültürüne uygun antibiyotik kullanımına devam edildi. Tedavi öncesinde  $36\pm 14$  cm<sup>2</sup> olan yara alanı uygulama sonunda  $11\pm 10$  cm<sup>2</sup>'ye geriledi ( $p<0.05$ ). Vakum tedavisinden sonra sadece iki hastanın (%11.8) yaralarının örtümünde ek cerrahi girişime gerek görüldü. İki hastada (%11.8) uygulama sırasında basınca bağlı ağrı görüldü.

**Çıkarımlar:** Vakum yardımcı yara örtüm yöntemi, enfekte yaraların bakımında bölgesel üstünlükleri yanı sıra daha hızlı ve konforlu bir tedavi olanağı sunar. Bu özellikleri ile konvansiyonel yara bakım yöntemlerine güvenilir bir seçenek sayılabilir.

**Anahtar sözcükler:** Negatif basınçlı yara tedavisi; yara iyileşmesi; yara enfeksiyonu/tedavi.

**Objectives:** This study was designed to evaluate the results of vacuum-assisted closure in the topical treatment of surgical site infections.

**Methods:** Vacuum therapy was performed in 17 patients (10 males, 7 females; mean age  $60\pm 20$  years) using the VAC system (Vacuum-Assisted Closure, Kinetic Concept Inc) for the treatment of surgical site infections. Infective wounds were in the hip (n=6), crus (n=5), knee (n=3), sacrum (n=2), and hand (n=1). The causative organism for infections was gram-positive bacteria in 15 patients (88.2%), and six patients (35.3%) had nosocomial infections. The wounds were treated with a negative pressure of 100-125 mmHg applied continuously for the first two days, and then intermittently for the following days. The mean follow-up period was  $11\pm 6$  months.

**Results:** The mean duration of vacuum therapy was  $16\pm 4$  days and the mean length of hospitalization was  $31\pm 19$  days. The patients underwent a mean number of three surgical procedures (range 1 to 6) before vacuum therapy. The mean amount of discharge from the wound was  $500\pm 150$  ml. Tissue edema and discharge problems were resolved in all the wounds and a hygienic and dry-looking surgical site was attained. In 11 patients (64.7%), clinical and bacteriologic eradication of infections was achieved at the surgical site through antibiotic use and vacuum therapy. Six patients with nosocomial infections continued to receive antibiotic treatment following resolution of surgical site problems. The mean wound area showed a significant reduction from  $36\pm 14$  cm<sup>2</sup> to  $11\pm 10$  cm<sup>2</sup> following vacuum therapy ( $p<0.05$ ). Only two patients (11.8%) required further surgical interventions for the closure of wound site. Two patients (11.8%) complained of pain associated with vacuum application.

**Conclusion:** Besides its topical advantages in the care of infected wounds, vacuum-assisted closure provides a more rapid and comfortable treatment opportunity, representing a reliable alternative to conventional wound care methods.

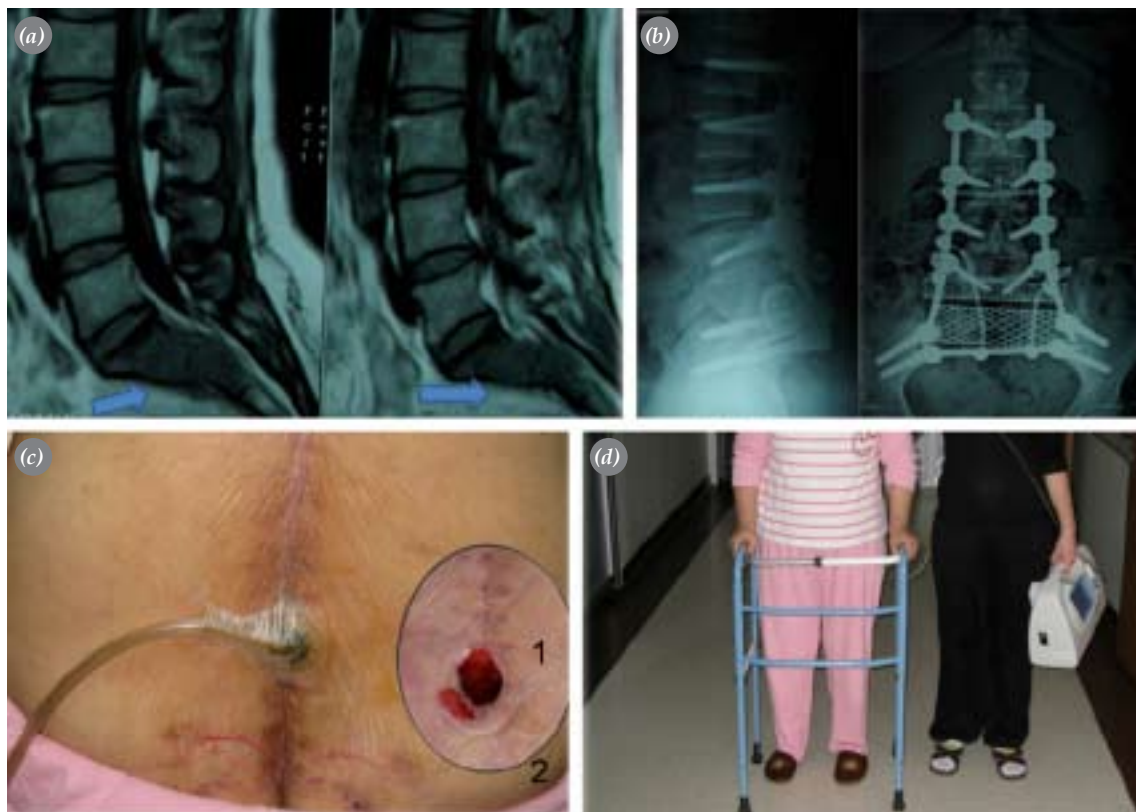
**Key words:** Negative-pressure wound therapy; wound healing; wound infection/therapy.

One of the most complex complications of extremity surgery is the infection associated with soft tissue loss. This situation seen in 1-12% of orthopedic interventions lead to problems related to the coverage of surgical materials and bone structures located in the wound area.<sup>[1-2]</sup> There are different opinions about selection of treatment method. In conventional treatment, specific surgical interventions varying from wet dressing, use of colloid gels and skin grafting to free flap transfer, all after wound irrigation and debridement of necrotic tissue.<sup>[3-4]</sup> An alternative method that has been started to be widely used in recent years is vacuum assisted closure systems. Those systems are given many different names such as topical negative pressurization, sub-atmospheric pressure treatment, sub-atmospheric pressured dressing and vacuum treatment (VT).<sup>[3-6]</sup>

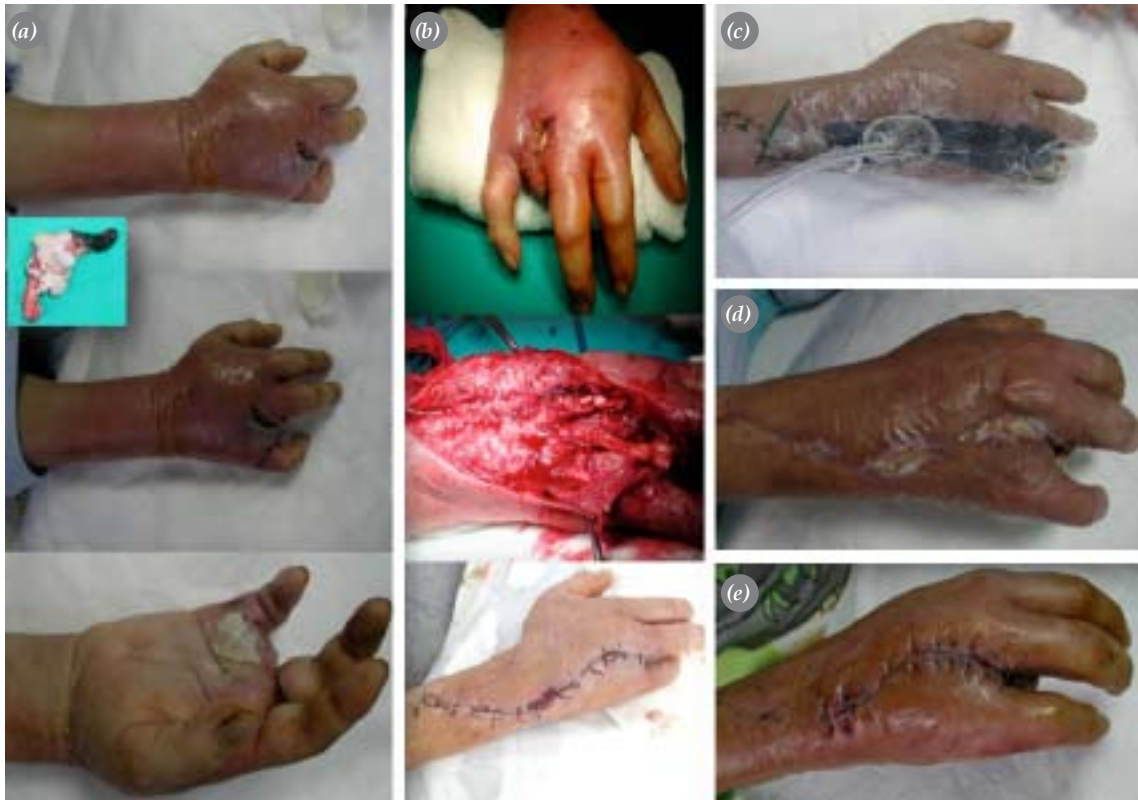In Cochrane Library, there are 269 original studies, out of a total number of 674 publications about va-

cuum treatment cited in 2007.<sup>[5,6]</sup> The most evident effect of vacuum treatment on the injured tissue is the increase of local blood circulation. Morykwas et al.<sup>[7]</sup> demonstrated that local blood circulation baseline four times increased by an applied negative pressure of 125mm Hg and in order that negative pressure effect persistence need to intermittent application. Another impact of vacuum treatment on the cellular structure of the wound surface is its mechanical stress.

As a consequence of this effect, cell proliferation and regeneration of granulation tissue are facilitated. Though third and the most controversial effect is removal of protease enzymes that are known to inhibit healing and decrease in bacterial count on the infected tissue.<sup>[8-12]</sup> Obviously, this point has a particular clinical outstanding for the treatment of post-operative wound complications. However, the shared information regarding the matter is limited to few studies.<sup>[10, 13-20]</sup>



**Figure 1.** The following are the observations from a patient suffering from waist pain extending to both legs: **(a)** MR imaging of a heterogeneous mass (48x32x60mm) that is detrimental to vertebrae, extending to pre-sacral area on the anterior side and to spinal channel on the posterior side, which affects S1 and S2 segments. **(b)** X-ray graphics after radical resection and posterior stabilization. **(c)** Uncovered wound in the surgery area after debridement following deep infection by *E. coli* and its vacuum assisted treatment. **(d)** Physical activity level of the patient after the initiation of vacuum treatment.



**Figure 2.** (a) Fourth finger on the right hand of the patient, who suffers from erythema, edema and pain, was amputated from metacarpophalangeal joint. Microbiological sampling was made after regional debridement. (b) Upon microbiological detection of *Clostridium* proliferation, a broad debridement and wound irrigation was done on the second day of admission. Infection was observed to spread over the deep tissues in dorsal side of the forearm. (c) Following the second operation, a vacuum treatment has been conducted for 12 days and (d) healing was observed. (e) Subsequent to the amputation of fourth metacarpal ray, patient was discharged 23 days after admission.

In this study, our results of vacuum assisted closure system were evaluated in the local treatment of infections occurred in the operated site.

### Patients and method

17 patients (10 males, 7 females; mean age  $60 \pm 20$ ), who received vacuum treatment in our clinics between 2006 and 2008 were evaluated retrospectively. Wound drainage for more than 5 days, existence of culture-positive infection and wound dehiscence with skin necrosis were our inclusion criteria.<sup>[18]</sup> Six (35.3%) of the infected wounds were on the hip region while five (29.4%) were on crus, three (17.7%) were on knee, two (11.8%) were on sacrum and one (5.9%) was on the hand. Trauma surgery ( $n=8$ ), arthroplasty ( $n=4$ ), tumor surgery ( $n=2$ ) and others (gas gangrene, lower leg amputation due to diabetes, open injury related to trauma) were the invasive treatments conducted (Figure 1, 2).

In 13 patients (76.5%), surgical materials (DHS

pins, plates, screws, prosthesis) applied on bone or joint surfaces in the early interventions were removed during preceding debridement terms. Among patients to whom trauma surgery was applied, three were treated with skeletal traction and five were applied external fixators. In patients with prosthesis (including the one with tumor resection), joint spacers made of bone cement with antibiotic (4 g teicoplanin) were implanted in the surgical site after removal of infected prosthesis. Vacuum treatment was started in those patients after 6 weeks.

Infections were evaluated together with the hospital infection committee. Wound cultures and laboratory parameters (sedimentation, CRP, leukocytes counting) taken weekly basis were used to follow up the patients. In 15 patients (88.2%), infection was due to gram-positive bacteria (Table 1). Structure based evaluation revealed that there was a hospital infection in 6 patients (35.3%). All patients' wound was treated with

**Table 1.** Distribution of bacteria responsible for infections

	Number of patients	%
<i>Staphylococcus aureus</i>		
Methicilline sensitive	3	17.7
Methicilline resistant	4	23.5
<i>Escherichia coli</i>	2	11.8
<i>Staphylococcus epidermidis</i>	4	23.5
<i>Pseudomonas aeruginosa</i>	2	11.8
<i>Acinetobacter baumannii</i>	1	5.9
<i>Clostridium perfringens</i>	1	5.9

debridement and irrigation operation several times. IV antibiotic therapy and vacuum treatment were initiated in reference to the wound culture results.

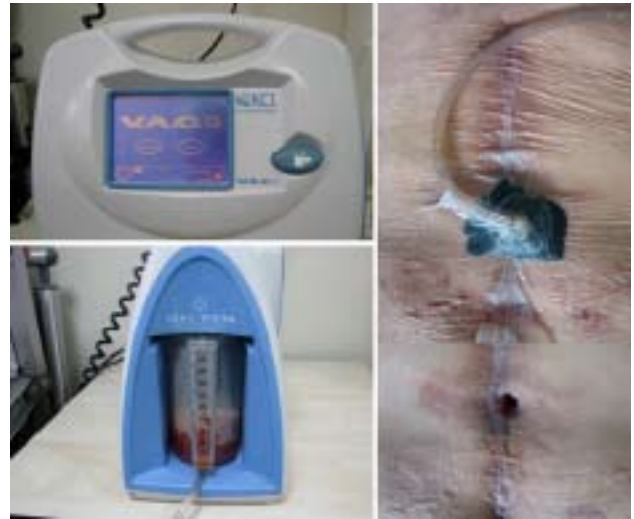In our study, VAC system was used as vacuum assisted closure system (Vacuum-Assisted Closure, Kinetic Concept Inc, San Antonio, TX, USA). Vacuum was applied on to the wound continuously for the first two days and intermittently through the rest of the treatment, at 100-125 mmHg negative pressure. Dressings were changed every 48 hours. Wounds were sized, surface debridement was conducted and the drainage amount was recorded. For sizing of wounds, scale of a universal joint goniometer was used.

(i) Drainage less than 20 ml between two dressings, (ii) improvement of lab findings about infection and/or detection of no bacterial count in the wound culture and (iii) reduction of tissue loss and wound' being closeable through simple reconstructive methods were our endpoint criteria.

Severe pain, lack of psychological adoption, observation of purulent material of remarkable amount during the dressing or within the waste container and excessive bleeding were our drop-out criteria.

Sponges made of polyurethane or polyvinyl alcohol with a pore size range of 400 – 600  $\mu$ m were used as filling material and self-adhesive semi-permeable covering films in the vacuum aided application. An in-line pressure regulator (T.R.A.C system, Kinetic Concept Inc), drainage collection container and negative pressurizer were the other components of the system (Figure 3).

Initial debridement and irrigation procedures were carried out in the operation room. Following deep tissue debridement, for those wounds with closeable muscle layer (hip and sacrum), an open cutaneous or



**Figure 3.** Vacuum treatment device and application method.

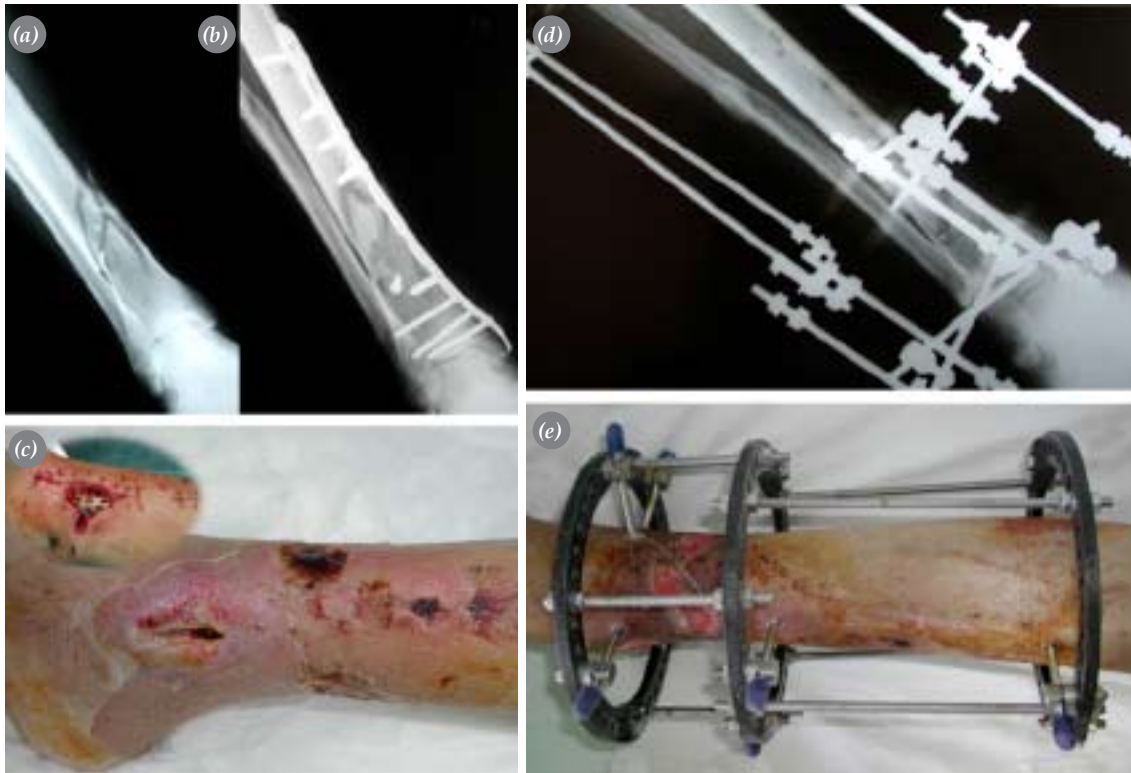
sub-cutaneous area of 4x6 cm (~ 20 cm<sup>2</sup>) was prepared after appropriate stitching of muscle and fascia layers. The prepared area or directly the wound surface was covered with an appropriately sized polyurethane sponge material. Wound area was covered with self-adhesive semi-permeable film. Connections were inserted through a hole made on the film and the system was started. Extended debridement and wash-outs subsequent to vacuum applications were conducted under anesthesia. The mean follow-up time was 11±6 months.

Collected data were analyzed with Wilcoxon test using SPSS 11.5 software.

**Results**

The mean time of vacuum treatment and hospitalization were 16±4 days and 31±19 days, respectively. Average number of surgical interventions per patient was 3 (range: 1-6). Mean total volume of collected wound drainage was 500±150 ml.

Problems associated with tissue edema and drainage, were solved in all wounds. A surgical wound area with dry and clean look was obtained (Figure 4). In 11 patients (64.7%), infection observed in the surgical area was treated both clinically and microbiologically, by using appropriate antibiotics and vacuum treatment. In 6 patients with hospital infection, vacuum treatment was terminated with resolution of wound complications; however the use of antibiotics determined with the wound culture was continued. Subsequent follow ups were carried out in the infection clinics. One patient in



**Figure 4.** (a) Tibia and fibula fractures on the right crus were diagnosed and (b) locked plate was applied to 70 years old male by minimal invasive technique 3 days after trauma (c) One month after surgery, in the surgical area located on the medial side of ankle, were observed wound drainage, dehiscence and peripheral edema. Debridement and irrigation was done. (d) Plate and screws removed and fractures treated with circular ex fix. frame (e) Scene after 14 days of vacuum treatment.

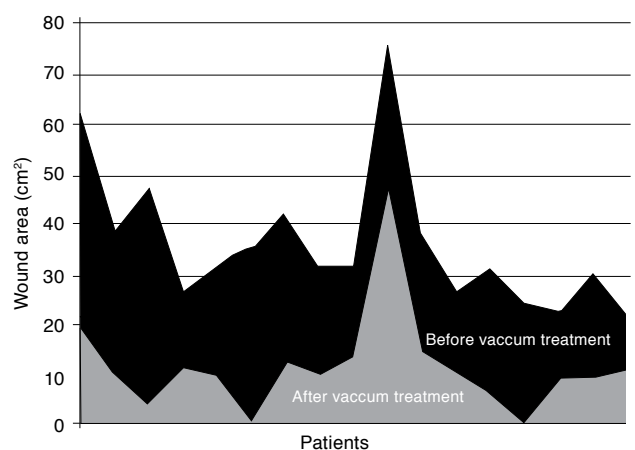
this group, who was applied tumor prosthesis for osteosarcoma, had to go under supra-patellar amputation. Only two patients (11.8%) needed additional surgical intervention (skin graft, local rotation flap) for complete coverage of wounds after vacuum treatment.

The mean wound area of  $36 \pm 14$  cm<sup>2</sup> was reduced to  $11 \pm 10$  cm<sup>2</sup> after the treatment ( $p < 0.05$ ) (Figure 5). Two patients (11.8%) complained for pain due to pressure during the application. Those complaints were overcome by decreasing the pressure for 25 mmHg.

## Discussion

Vacuum treatment as a method that has been used in the past, for superficial tissue losses such as burns and pressure injuries, it has found new areas of use in severe soft tissue losses associated with orthopedic infections as well as tumor surgery, in recent years. [1, 2, 4, 8, 10, 13, 21, 22] For those injuries that require long term administration of antibiotics and special techniques such as free tissue transplantation, care is a complicated process. [1, 2, 14-17] Implementation of localized

vacuum treatment provides some advantages for such purposes. The first of those advantages is the evacuation of exudates, which is usually the sign of deep injury infections and broad necrosis of soft tissues. [10, 15-18] Vacuum treatment provides the excretion of proteases that are known to have negative impact on



**Figure 5.** Distribution of wound surface areas before and after vacuum therapy

cells contributing to tissue healing, while assisting the control on local and systemic bacterial counts.<sup>[23]</sup> Vacuum treatment assisted in solving problems related to tissue edema and wound drainage in all cases; a clean and dry surgical wound area was obtained by preventing the formation of dead space. Development of granulation tissue was facilitated through the increase of local blood circulation. A significant shrinkage of wound area was observed in 16 days, as an average of all patients. In a study of 1500 general body trauma patients by Kaplan et al<sup>[24]</sup> which is the most extensive series in its class, VT was shown to decrease the time and cost of hospitalization to almost the half. In our study, VT contributed to the complete recovery of local and general infections in 11 patients; 15 wounds (88.2%) healed without extra need in surgical intervention. Only two wounds (11.8%) required additional surgical treatment at day 10 of vacuum treatment. Brandi et al<sup>[25]</sup> reported uncomplicated closure of all tendons and muscles with closure problems by VT aided epidermalized skin application.

Regardless of the selected treatment method, those wounds may require prolonged hospitalization, intensive use of medications and multiple surgical interventions.<sup>[26]</sup> Some of our patients who went under a mean number of three surgical operations had to be hospitalized for 1 month. In reference to conventional dressing, this costly process that is limiting daily life was shorter.<sup>[27, 28]</sup> Only two patients (11.8%) complained for pain due to pressure during the application. Complications such as recurrent infection, septicemia and fluid-electrolyte losses were not observed.<sup>[28]</sup>

Limitations of our study were the small sample size and lack of a control group. Inability of bacteria counting in the wound area was another constraint.

As a result, vacuum aided wound closure method, provides faster and more comfortable treatment as well as its local treatment advantages in infected wound care. Owing to those features, VT appears to be safe option to conventional wound care methods.

## References

- Bihariesingh VJ, Stolarczyk EM, Karim RB, van Kooten EO. Plastic solutions for orthopaedic problems. *Arch Orthop Trauma Surg* 2004;124:73-6.
- Kramhøft M, Bødtker S, Carlsen A. Outcome of infected total knee arthroplasty. *J Arthroplasty* 1994;9:617-21.
- Demir A, Demirtaş Y, Çıfci M, Öztürk N, Karacalar A. Topikal negatif basınç (vakum yardımcı kapama [VAC]) uygulamalarımız. *Türk Plast Rekonstr Est Cer Derg* 2006; 14:171-7.
- Başer NT, Işık V, Bulutoğlu R, Gökrem S, Aslan G. Yara bakımı ve tedavisinde subatmosferik basınçlı yara pansumanı. *Türkiye Klinikleri J Med Sci* 2007;27:902-15.
- Schintler MV, Prandl EC. Vacuum-assisted closure - what is evidence based? *Eur Surg* 2008;40:11-8.
- Hunter JE, Teot L, Horch R, Banwell PE. Evidence-based medicine: vacuum-assisted closure in wound care management. *Int Wound J* 2007;4:256-69.
- Morykwas MJ, Argenta LC, Shelton-Brown EI, McGuirt W. Vacuum-assisted closure: a new method for wound control and treatment: animal studies and basic foundation. *Ann Plast Surg* 1997;38:553-62.
- Vikatmaa P, Juutilainen V, Kuukasjärvi P, Malmivaara A. Negative pressure wound therapy: a systematic review on effectiveness and safety. *Eur J Vasc Endovasc Surg* 2008; 36:438-48.
- Scherer SS, Pietramaggiore G, Mathews JC, Prsa MJ, Huang S, Orgill DP. The mechanism of action of the vacuum-assisted closure device. *Plast Reconstr Surg* 2008;122:786-97.
- Argenta LC, Morykwas MJ, Marks MW, DeFranzo AJ, Molnar JA, David LR. Vacuum-assisted closure: state of clinic art. *Plast Reconstr Surg* 2006;117(7 Suppl):127S-42S.
- Saxena V, Hwang CW, Huang S, Eichbaum Q, Ingber D, Orgill DP. Vacuum-assisted closure: microdeformations of wounds and cell proliferation. *Plast Reconstr Surg* 2004; 114:1086-96.
- Venturi ML, Attinger CE, Mesbahi AN, Hess CL, Graw KS. Mechanisms and clinical applications of the vacuum-assisted closure (VAC) Device: a review. *Am J Clin Dermatol* 2005;6:185-94.
- Joseph E, Hamori CA, Bergman S, Roaf E, Swann NF, Anastasi GW. A prospective, randomized trial of vacuum-assisted closure versus standard therapy of chronic non-healing wounds. *Wounds* 2000;12:60-7.
- Kanakaris NK, Thanasis C, Keramaris N, Kontakis G, Granick MS, Giannoudis PV. The efficacy of negative pressure wound therapy in the management of lower extremity trauma: review of clinical evidence. *Injury* 2007;38 Suppl 5:S9-18.
- DeFranzo AJ, Argenta LC, Marks MW, Molnar JA, David LR, Webb LX, et al. The use of vacuum-assisted closure therapy for the treatment of lower-extremity wounds with exposed bone. *Plast Reconstr Surg* 2001;108:1184-91.
- Webb LX. New techniques in wound management: vacuum-assisted wound closure. *J Am Acad Orthop Surg* 2002; 10:303-11.
- Herscovici D Jr, Sanders RW, Scaduto JM, Infante A, DiPasquale T. Vacuum-assisted wound closure (VAC therapy) for the management of patients with high-energy soft tissue injuries. *J Orthop Trauma* 2003;17:683-8.
- Gomoll AH, Lin A, Harris MB. Incisional vacuum-assisted

- closure therapy. *J Orthop Trauma* 2006;20:705-9.
19. Blume PA, Walters J, Payne W, Ayala J, Lantis J. Comparison of negative pressure wound therapy using vacuum-assisted closure with advanced moist wound therapy in the treatment of diabetic foot ulcers: a multicenter randomized controlled trial. *Diabetes Care* 2008;31:631-6.
  20. Wongworawat MD, Schnall SB, Holtom PD, Moon C, Schiller F. Negative pressure dressings as an alternative technique for the treatment of infected wounds. *Clin Orthop Relat Res* 2003;(414):45-8.
  21. Saleh K, Olson M, Resig S, Bershadsky B, Kuskowski M, Gioe T, et al. Predictors of wound infection in hip and knee joint replacement: results from a 20 year surveillance program. *J Orthop Res* 2002;20:506-15.
  22. Bickels J, Kollender Y, Wittig JC, Cohen N, Meller I, Malawer MM. Vacuum-assisted wound closure after resection of musculoskeletal tumors. *Clin Orthop Relat Res* 2005; 441:346-50.
  23. Mouës CM, Vos MC, van den Bemd GJ, Stijnen T, Hovius SE. Bacterial load in relation to vacuum-assisted closure wound therapy: a prospective randomized trial. *Wound Repair Regen* 2004;12:11-7.
  24. Kaplan M, Daly D, Stemkowski S. Early intervention of negative pressure wound therapy using Vacuum-Assisted Closure in trauma patients: impact on hospital length of stay and cost. *Adv Skin Wound Care* 2009;22:128-32.
  25. Brandi C, Grimaldi L, Nisi G, Silvestri A, Brafa A, Calabrò M, et al. Treatment with vacuum-assisted closure and cryo-preserved homologous de-epidermalised dermis of complex traumas to the lower limbs with loss of substance, and bones and tendons exposure. *J Plast Reconstr Aesthet Surg* 2008;61:1507-11.
  26. Apelqvist J, Armstrong DG, Lavery LA, Boulton AJ. Resource utilization and economic costs of care based on a randomized trial of vacuum-assisted closure therapy in the treatment of diabetic foot wounds. *Am J Surg* 2008;195:782-8.
  27. Özsüt H, Tözün R, Çağatay A, Eraksoy H. Kronik osteomyelit ve total protez infeksiyonlarında yüzeysel sürüntü kültürleriyle, derin doku veya aspirat materyallerinin mikrobiyolojik sonuçlarının karşılaştırılması. *Klimik Dergisi* 2007;20:71-6.
  28. Norton SE, De Souza B, Marsh D, Moir G. Vacuum-assisted closure (VAC Therapy) and the risk of fluid loss in acute trauma. *Ann Plast Surg* 2006;56:194-5.