



Simvastatin improves spinal fusion in rats

Bora BOSTAN¹, Taner GÜNEŞ¹, Murat AŞCI¹, Cengiz ŞEN², Mehmet Halidun KELEŞTEMUR³,
Mehmet ERDEM⁴, Reşit Doğan KÖSEOĞLU⁵, Ünal ERKORKMAZ⁶

¹Department of Orthopedics and Traumatology, School of Medicine, Gaziosmanpaşa University, Tokat, Turkey;

²Department of Orthopedics and Traumatology, School of Medicine, Bezmialem Vakıf University, İstanbul, Turkey;

³Department of Mechanical Engineering, School of Engineering, Melikşah University, Kayseri, Turkey;

⁴Department of Orthopedics and Traumatology, Dr. Lütfi Kırdar Kartal Training and Research Hospital, İstanbul, Turkey;

⁵Department of Pathology, School of Medicine, Gaziosmanpaşa University, Tokat, Turkey;

⁶Department of Biostatistics, School of Medicine, Gaziosmanpaşa University, Tokat, Turkey

Objective: Statins stimulate bone formation by inducing the expression of bone morphogenetic proteins (BMP-2). The aim of our study was to investigate the effects of orally administered simvastatin on spinal fusion in rats.

Methods: Twenty rats were randomized into a spinal fusion group (SF) (n=10) or a spinal fusion and oral simvastatin administered group (SFS) (n=10). A spinal fusion was performed between L4-L6 representing two levels. Simvastatin (120 mg/kg/day) was administered orally in the SFS group. The rats were killed at the end of the 12 week study period.

Results: Manual palpation revealed two moderate fusions in the SF group. The SFS group did not reveal any signs of pseudoarthrosis. An average three-point bending force causing failure of fusion revealed results of 148.80±39.403 Newtons and 123.80±28.479 Newtons in SFS and SF groups, respectively (p>0.05). Histological examination revealed better fusion grades in the SFS group (mean: 9.30±0.949) than in the SF group (mean: 6.80±2.044) (p=0.003). Radiographic examination revealed Grade C fusion in two levels and Grade A fusion in 18 levels in the SF group. In the SFS group, Grade C fusion was detected in one level and Grade A fusions in 19.

Conclusion: Our results suggest that simvastatin can promote spinal fusion and can be used as an adjunct to spinal fusion procedures in an elderly population with high cholesterol levels.

Key words: BMP; pseudoarthrosis; simvastatin; spinal fusion; statin.

Specific competitive inhibitors of 3-hydroxy-3-methylglutaryl coenzyme A reductase (HMG-CoA reductase) –such as fluvastatin, lovastatin, simvastatin, pravastatin, and atorvastatin– are widely used agents for lipid reduction, and lessen the risk of arteriosclerosis with minimal side effects.^[1-3] It has been reported that statins, especially lovastatin and simvastatin, stimulate bone healing and formation by inducing the expression of bone morphogenetic pro-

teins (BMP-2).^[4] Bone morphogenetic proteins are important regulators of the healing of bone fractures.^[5] Posterior spinal fusion, which mimics the healing process of the bone, is commonly used for spinal operations, such as spondylolisthesis, scoliosis, kyphosis, degenerative spinal disorders and tumors.^[6,7] In the present study, our aim was to investigate the effects of orally administered simvastatin on spinal fusion in rats.

Correspondence: Bora Bostan, MD. Gaziosmanpaşa Üniversitesi Tıp Fakültesi, Ortopedi ve Travmatoloji Anabilim Dalı, 60100, Merkez, Tokat, Turkey.
Tel: +90 533 - 317 14 82 e-mail: borabostan@gmail.com

Submitted: July 31, 2010 **Accepted:** December 8, 2010

©2011 Turkish Association of Orthopaedics and Traumatology

Materials and methods

All procedures were conducted in accordance with the National Institute of Health's Guide for the Care and Use of Animals and were approved by the local ethical committee. Twenty male Sprague Dawley rats (mean age: 6 months; range: 5-6 months), each weighing 300 grams, were used. The rats were housed in polycarbonate cages and fed with standard food and water. The rats were randomized into two groups; a spinal fusion group (SF; n=10) or a spinal fusion and oral simvastatin administered group (SFS; n=10). Both groups were fed chocolate for 10 days before the operation. In the SFS group, simvastatin was crushed and mixed with the chocolate to be administered orally at a dose of 120 mg/kg/day (Zocor; Merck, NJ, USA) for seven days preoperatively and continued for 12 weeks postoperatively. An equal amount of chocolate was given to the rats in the SF group. The rats were operated on using the technique described by Dimar.^[7] Animals were anesthetized with a 0.45 cc intraperitoneal injection of a solution with a ratio of 60 mg/kg ketamine and 6 mg/kg xylazine. Intramuscular Penicillin G (100,000 U) was used as an infection prophylaxis before the operation. Next, the animals were affixed to a small operating table and shaved and the operation side was sterilized with a 10% povidone iodine solution.

To harvest a bone graft from the tail, the tail was amputated and all soft tissue was removed from the bone using forceps, rongeurs and scalpels. Five vertebrae were separated from the intervertebral discs and all periosteum was removed (Fig. 1). The bone was morselized with rongeurs and weighed to create a homogenous distribution of the grafts between the groups. The average bone graft was 0.30 g (range: 0.25-0.32 g). A dorsal longitudinal incision was made from L3 through the sacral midline for the posterior spinal fusion procedure. The subcutaneous tissue was sharply dissected and the paravertebral muscles were detached and retracted laterally to the facet joints with automatic retractors. After the meticulous removal of all the posterior spinal soft tissues, decortication of the dorsal surfaces of transverse processes and facet joints was performed with an electrical high-speed burr (Core Ref 5400-50; Stryker, MI, USA). A hole was created in the spinous process of

L4, L5 and L6 (representing two level fusion), and a stainless cerclage wire was passed in a figure-of-eight fashion to enhance stabilization. After stabilization, the autogenous bone graft harvested from the tails was placed along the posterior lamina and transverse processes (Fig. 2). The paraspinal muscles were closed with a running suture and the incision was closed with metal clips.

All animals survived for 12 weeks and at the end of the 12 week period they were killed using an intra-abdominal injection of pentobarbital (100 mg/kg body weight). All soft tissue and muscles were dissected from the spinal segment L2 through the sacrum. The lumbar vertebrae and the sacrum were then enblock resected. All cerclage wires were removed and the fusion sites were assessed by three examiners using a manual palpation method for the signs of pseudoarthrosis^[7] (Table 1). Micro-motions in either plane (coronal and sagittal) were assessed for each level (L4-L5 and L5-L6). Radiographies of

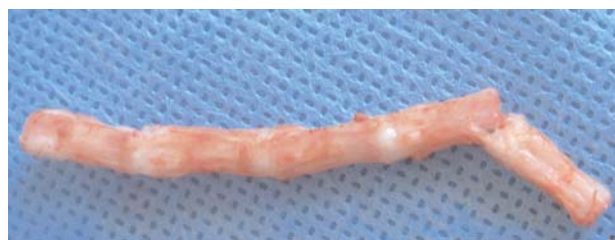

Fig. 1. All soft tissues of the tail were cleaned. [Color figure can be viewed in the online issue, which is available at www.aott.org.tr]

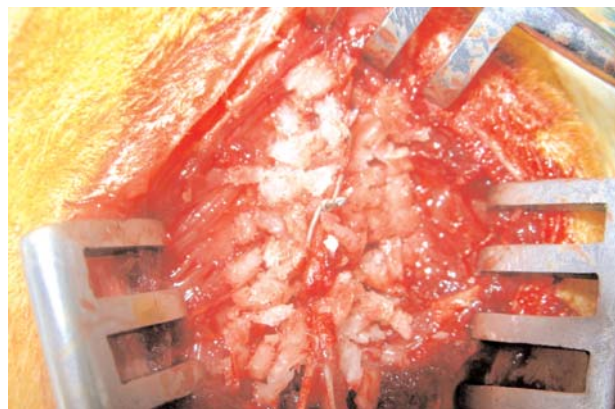


Fig. 2. Morselized bone graft taken from the tail placed over the decorticated posterior lamina and facet joints. [Color figure can be viewed in the online issue, which is available at www.aott.org.tr]

all animals were taken and an assessment of fusion mass was performed according to Lenke et al.^[8] (Table 1; Figs. 3 and 4). A biomechanical three-point bending test was performed using a mechanical testing device (Hounsfield H50KM; Hounsfield Test Equipment Ltd., Surrey, England). The specimens were placed on the machine with the dorsal sides facing towards the tip of the force applicator. Force was applied to the middle of the fused segment at a constant rate of 10 mm/minute until failure occurred. The force at the time of the failure was recorded in Newton units.

Histological examination was made in both groups. After removal of their soft tissue, the spinal segments from L2 to the sacrum were fixed in a solution of 10% formalin, decalcified and stained with a standard hematoxylin eosin stain. Next, examination was made under standard light microscopy. Histological examination was made as described in the study by Huddlestone et al.^[9] (Table 1), on four fields per specimen (each specimen had two levels, and each level two fields; right and left). The scores of the four fields were averaged.

Statistical analysis

A Kolmogorov-Smirnov test was used to determine the distribution of the two groups. Two independent t-tests were used to compare the biomechanical three-point bending forces and histopathological scores of group SF and group SFS. Significance level was set at $p < 0.05$ and calculations were performed using SPSS software (SPSS Inc., IL, USA).

Table 1. Assessment of fusion by manual palpation, histological examination and radiography.

Grade of fusion	Manual palpation (Dimar et al. ^[7])
Solid	No micro-motion in anteroposterior and lateral planes
Moderate	Micro-motion in one plane
Pseudoarthrosis	Unrestricted motion in either plane
Grade of fusion	Histological examination (Huddlestone et al. ^[9])
Grade 1	Fibrous tissue
Grade 2	Predominantly fibrous tissue with some cartilage
Grade 3	Equal amount of fibrous tissue with some cartilage
Grade 4	All cartilage
Grade 5	Predominantly cartilage with some woven bone
Grade 6	Equal amount of cartilage and woven bone
Grade 7	Predominantly woven bone with some cartilage
Grade 8	Entirely woven bone
Grade 9	Woven bone with some mature bone
Grade 10	Lamellar (mature) bone
Grade of fusion	Radiographic evaluation (Lenke et al. ^[8])
A	Definitely big trabeculated bilateral fusion mass
B	Possibly solid unilateral large fusion mass with contralateral small fusion mass
C	Probably not solid, thin fusion masses bilaterally
D	Definitely not solid, graft resorption bilaterally

Results

Manual palpation revealed two moderate fusions in 20 levels (90%) in the SF group, whereas the treatment group revealed no signs of pseudoarthrosis in 20 levels. An average three-point bending force causing failure of fusion revealed 148.80 ± 39.403 Newtons and 123.80 ± 28.479 Newtons in the SFS and SF groups, respectively ($p > 0.05$) (Table 2). Histological exami-

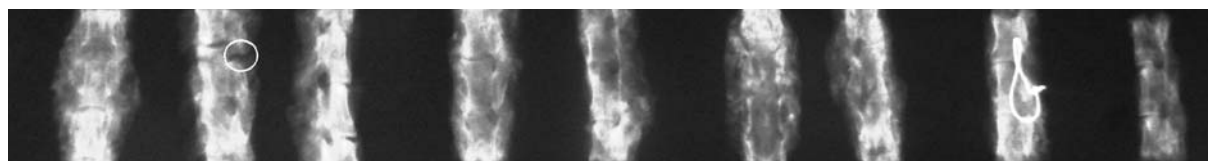


Fig. 3. Radiography of the SFS group (circle showing Grade C fusion).

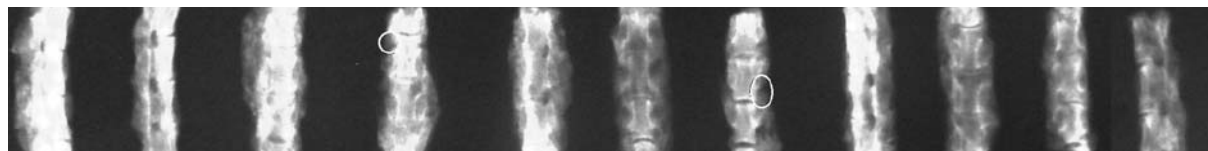


Fig. 4. Radiography of the SF group (circles showing Grade C fusions).

nation revealed better fusion grades in the SFS group, with a mean of 9.30 ± 0.949 than with the SF group, with a mean of 6.80 ± 2.044 ($p=0.003$) (Table 2; Figs. 5 and 6). Radiographic examination revealed Grade C fusion in two levels and Grade A fusion in 18 levels in the SF group. We detected Grade C fusion in one level and Grade A fusion in 19 levels in the SFS group. (Figs. 3 and 4).

Discussion

Posterior spinal fusion is commonly used for spinal operations for spondylolisthesis, scoliosis, kyphosis, degenerative spinal disorders and tumors.^[6] To prevent pseudoarthrosis, new substitutes have been used in clinical and experimental studies, such as heterologous demineralized bone matrix, bone morphogenetic protein-7, and osteogenic protein-1.^[10-13] BMPs are important regulators of the bone in the healing of fractures.^[5] It has been reported that statins—especially lovastatin and simvastatin—stimulate bone formation by inducing the expression of BMP-2 and that orally administered drugs increase cancellous bone volume.^[4] Furthermore, angiogenesis is essential for bone formation.^[5] Hydrophobic statins stimulate vascular endothelial growth factor expression in osteoblasts, which in turn promote differentiation.^[14] Another effect of simvastatin on bone formation is the inhibition of inflammation.^[15] Statins inhibit the HMG-CoA reductase enzyme which is key in the formation of cholesterol and other pathways, including the formation of farnesyl-

Table 2. Biomechanical and histological test results of the two groups.

Groups	Biomechanics mean \pm SD (Newton)	Histology mean \pm SD
SF group	123.80 \pm 28.479	6.80 \pm 2.04
SFS group	148.80 \pm 39.403	9.30 \pm 0.94
p	0.121	0.003

pyrophosphate (which is necessary for activation of osteoclasts).^[16] Beneficial effects of HMG-CoA reductase inhibitors on cardiac events are mainly due to their hypocholesterolemic effects.^[17,18] Minimal side effects of statins have been reported.^[3]

Another statin, called cerivastatin, given at a high dose (1.0 mg/kg/day) induced bone union of allograft to host bone in a rat model in one study. This effect was attributed to more bone growth due to the increase of BMP-2 and vascular endothelial growth factor.^[19] Rats are good candidates for spinal fusion models.^[10,20] We used a drug delivery model developed by Huang-Brown and Guhad^[21] which is reported to be an effective, consistent, reliable method of oral drug delivery to a large group of rats for a long period of time. The meta-analysis study by Douglas et al. suggests that statins cause significant reduction in hip and non-spine fractures.^[22]

The effect of the systemic and local administration of simvastatin on bone healing has been investi-

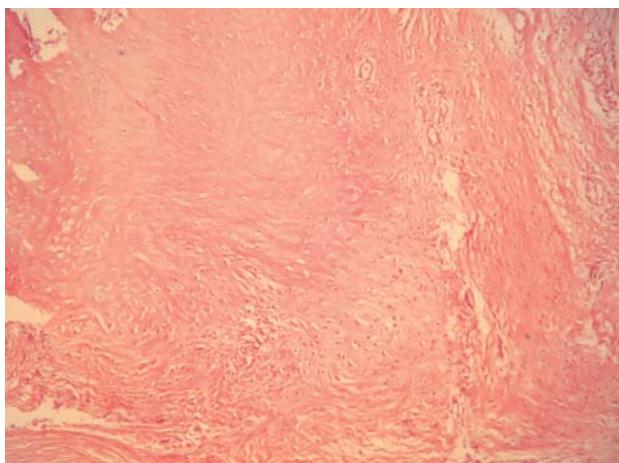


Fig. 5. Fusion area consisting of predominantly cartilage tissue (H-E x30). [Color figure can be viewed in the online issue, which is available at www.aott.org.tr]

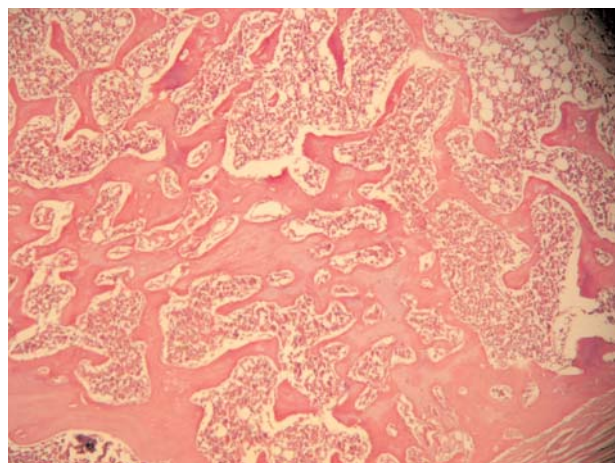


Fig. 6. Mature lamellar bone and bone marrow in the healing areas (H-E x20). [Color figure can be viewed in the online issue, which is available at www.aott.org.tr]

gated in several studies.^[19,23-30] Wong and Rabie created 15 defects in the parietal bone of rabbits; five of them were grafted with simvastatin collagen grafts, five were grafted with collagen alone, and the last group were left empty.^[24] The simvastatin collagen graft group revealed 308% more new bone formation than collagen grafts. Wong and Rabie concluded that statin collagen grafts can be used with other bone grafting materials (such as autogenous bone grafts) to exert their osteoinductive effects on larger defects.^[24] Mundy et al. suggested that a subcutaneous injection of simvastatin causes a 50% increase in new bone formation in rat calvaria at 21 days; this observation is comparable to that seen with fibroblast growth factor.^[25] Wong and Rabie found that a statin graft applied to the defect in a skull of a rabbit induced bone formation by day five; by the 14th day, an abundance of bone formation was detected.^[26] Stein et al. reported that locally applied simvastatin in methylcellulose gel leads to a 45% increase in bone area in the mandible.^[29] In a study by Ma et al., the effect of oral simvastatin on bone formation and ceramic resorption in a peri-implant defect model was investigated and reported to be ineffective in repairing defects; this was because the drug was severely eliminated by the liver which led to poor bioavailability.^[30] In another study by Skoglund et al. 40 mice were given 120 mg/kg simvastatin orally per day; this resulted in a 53% bigger transverse area, a 150% increase in energy uptake at 14 days in a femur fracture model. It was also observed that a 63% greater force was required to break the bone.^[23] This is a very high dose for animals but it is necessary for the bioavailability of the drug in the bone. However, such high doses cannot be used in clinical practice.

Patil et al. investigated the effect of orally administered simvastatin (20 mg/day) on fracture healing of the distal radius in humans in a prospective, double-blind, randomized controlled trial.^[28] They randomized 62 patients into two placebo and drug groups. Thirty-one patients in the drug group did not show significant differences with respect to fracture healing at the end of 12 weeks. They attributed this result to a high clearance of simvastatin in the liver leading to inadequate levels of the drug at the bone tissue level. Thus, in the present study, we used high doses of simvastatin to overcome the clearance of

the drug in the liver as did Skoglund et al. in their study. Yee et al. reported the results of orally administered simvastatin on a spinal posterolateral fusion model in rabbits and stated that it has no beneficial effect on spinal fusion.^[31] However, the drug dose used in the study (6.5 mg/kg/day) was very low, and the drug did not show a beneficial effect on the spine due to its clearance in the liver. Because of this observation, we used very high doses (120 mg/kg/day) to overcome this problem.

Although an average three-point bending force causing failure of fusion was measured at 148.80 ±39.403 Newtons in the SFS group and 123.80 ±28.479 Newtons in the SF group, the difference was not statistically significant in the present study ($p>0.05$). However, with manual examination our research revealed moderate fusion in two levels in the SF group, while there was no pseudoarthrosis in the SFS group. Biomechanical tests may not always be correlated with the manual examination method and radiographies. Some reports in the literature have stated that manual examination is the gold standard for assessing spinal fusion.^[7,10,20,32] Our results are consistent with these reports. Histopathological results are correlated with radiographies and manual palpation tests in the current study. The two specimens (two levels) where moderate fusion was detected by manual palpation in the SF group revealed a Grade C fusion on radiography and Grades 3 and 5 on histological examination.

In conclusion, we suggest that simvastatin can promote spinal fusion. If the bioavailability of simvastatin in the bone can be adjusted by lowering its clearance in the liver it can be used as an adjunct to spinal fusion procedures in elderly populations with high cholesterol levels.

Conflicts of Interest: No conflicts declared.

References

1. Garrett IR, Gutierrez G, Mundy GR. Statins and bone formation. *Curr Pharm* 2001;7:715-36.
2. Deedwania PC, Hunninghake DB, Bays HE, Jones PH, Cain VA, Blasetto JW; STELLAR Study Group. Effects of rosuvastatin, atorvastatin, simvastatin, and pravastatin on atherogenic dyslipidemia in patients with characteristics of the metabolic syndrome. *Am J Cardiol* 2005;95:360-6.
3. Oxlund H, Andreassen TT. Simvastatin treatment partially prevents ovariectomy-induced bone loss while increasing cortical bone formation. *Bone* 2004;34:609-18.

4. Mundy G, Garrett R, Harris S, Chan J, Chen D, Rossini G, Boyce B, Zhao M, Gutierrez G. Stimulation of bone formation in vitro and in rodents by statins. *Science* 1999; 286:1946-9.
5. Wong RW, Rabie AB. Early healing pattern of statin-induced osteogenesis. *Br J Oral Maxillofac Surg* 2005;43: 46-50.
6. Drespe IH, Polzhofer GK, Turner AS, Grauer JN. Animal models for spinal fusion. *Spine J* 2005;5:209-16.
7. Dimar JR 2nd, Ante WA, Zhang YP, Glassman SD. The effects of nonsteroidal anti-inflammatory drugs on posterior spinal fusions in the rat. *Spine* 1996;21:1870-6.
8. Lenke LG, Bridwell KH, Bullis D, Betz RR, Baldus C, Schoenecker PL. Results of in situ fusion for isthmic spondylolisthesis. *J Spinal Disord* 1992;5:433-42.
9. Huddlestone PM, Steckelberg JM, Hansen AD, Rouse MS, Bolander ME, Pater R. Ciprofloxacin inhibition of experimental fracture healing. *J Bone Joint Surg Am* 2000;82:161-73.
10. Moazzaz P, Gupta MC, Gilotra MM, Gilotra MN, Maitra S, Theerajunyaporn T, et al. Estrogen-dependent actions of bone morphogenetic protein-7 on spine fusion in rats. *Spine* 2005;30:1706-11.
11. Salamon ML, Althausen PL, Gupta MC, Laubach J. The effects of BMP-7 in a rat posterolateral intertransverse process fusion model. *J Spinal Disord Tech* 2003;16:90-5.
12. Guizzardi S, Di Silvestre M, Scandroglio R, Ruggeri A, Savini R. Implants of heterologous demineralized bone matrix for induction of posterior spinal fusion in rats. *Spine* 1992;17:701-7.
13. Patel TC, Erulkar JS, Grauer JN, Toriano NW, Panjabi MM, Friedlaender GE. Osteogenic protein-1 overcomes the inhibitory effect of nicotine on posterolateral lumbar fusion. *Spine* 2001;26:1656-61.
14. Maeda T, Kawane T, Horiuchi N. Statins augment vascular endothelial growth factor expression in osteoblastic cells via inhibition of protein prenylation. *Endocrinology* 2003;144:681-92.
15. Edwards CJ, Spector TD. Statins as modulators of bone formation. *Arthritis Res* 2002;4:151-3.
16. Gonyeau MJ. Statins and osteoporosis: a clinical review. *Pharmacotherapy* 2005;25:228-43.
17. Gotto AM Jr, LaRosa JC. The benefits of statin therapy--what questions remain? *Clin Cardiol* 2005;28:499-503.
18. Barter P, Gotto AM, LaRosa JC, Maroni J, Szarek M, Grundy SM, et al. HDL cholesterol, very low levels of LDL cholesterol, and cardiovascular events. *N Engl J Med* 2007;357:1301-10.
19. Ohno T, Shigetomi M, Ihara K, Matsunaga T, Hashimoto T, Kawano H, et al. Skeletal reconstruction by vascularized allogenic bone transplantation: effects of statin in rats. *Transplantation* 2003;76:869-71.
20. Lee YP, Jo M, Luna M, Chien B, Lieberman JR, Wang JC. The efficacy of different commercially available demineralized bone matrix substances in an athymic rat model. *J Spinal Disord Tech* 2005;18:439-44.
21. Huang-Brown KM, Guhad FA. Chocolate, an effective means of oral drug delivery in rats. *Lab Anim (NY)* 2002; 31:34-6.
22. Bauer DC, Mundy GR, Jamal SA, Black DM, Cauley JA, Ensrud KE, et al. Use of statins and fracture: results of 4 prospective studies and cumulative meta-analysis of observational studies and controlled trials. *Arch Intern Med* 2004;164:146-52.
23. Skoglund B, Forslund C, Aspenberg P. Simvastatin improves fracture healing in mice. *J Bone Miner Res* 2002;17:2004-8.
24. Wong RW, Rabie AB. Statin collagen grafts used to repair defects in the parietal bone of rabbits. *Br J Oral Maxillofac Surg* 2003;41:244-88.
25. Mundy G, Garrett R, Harris S, Chan J, Chen D, Rossini G, et al. Stimulation of bone formation in vitro and in rodents by statins. *Science* 1999;286:1946-9.
26. Wong RW, Rabie BM. Histologic and ultrastructural study on statin graft in rabbit skulls. *J Oral Maxillofac Surg* 2005; 63:1515-21.
27. Skoglund B, Aspenberg P. Locally applied simvastatin improves fracture healing in mice. *BMC Musculoskeletal Disorders* 2007;8:1-6.
28. Patil S, Holt G, Raby N, McLennan AN, Smith K, O'Kane S, et al. Prospective, double blind, randomized, controlled trial of simvastatin in human fracture healing. *J Orthop Res* 2009;27:281-5.
29. Stein D, Lee Y, Schmid MJ, Killpack B, Genrich MA, Narayana N, et al. Local simvastatin effects on mandibular bone growth and inflammation. *J Periodontol* 2005;76: 1861-70.
30. Ma B, Clarke SA, Brooks RA, Rushton N. The effect of simvastatin on bone formation and ceramic resorption in a peri-implant defect model. *Acta Biomater* 2008;4:149-55.
31. Yee AJ, Bae HW, Friess D, Roth SM, Whyne C, Robbin M, et al. The use of simvastatin in rabbit posterolateral lumbar intertransverse process spine fusion. *Spine J* 2006; 6:391-6.
32. Yee AJ, Bae HW, Friess D, Robbin M, Johnstone B, Yoo JU. Accuracy and interobserver agreement for determinations of rabbit posterolateral spinal fusion. *Spine* 2004;29: 1308-13.